RESEARCH PAPER | Medical Science | Volume : 5 | Issue : 6 | June 2015 | ISSN - 2249-555X



Prenatal diagnosis of Congenital High Airway Obstruction Syndrome – A Case Report.

KEYWORDS: Congenital high airway obstruction syndrome, laryngeal atresia, echogenic lungs.

Pilli Madhavi Latha	Chilukuri Swathi	Laxmi Sri
Associate Professor, Department of OBGY, Alluri Sita Ramaraju Academy of Medical Sciences (ASRAM)	Department of Pathology, Alluri Sita Ramaraju Academy of Medical Sciences (ASRAM)	Sri Laxmi Hospital, ELURU, Alluri Sita Ramaraju Academy of Medical Sciences (ASRAM)

ABSTRACT *Congenital high airway obstruction syndrome is a rare anomaly which is uniformly fatal. Antenatal diagnosis is made by identifying echogenic and enlarged lungs, dilated bronchi, inverted /flattened diaphragm and ascites on ultrasound. We describe a case that was diagnosed and confirmed by complete pathological examination at 17 weeks of gestation.*

Introduction:
Congenital high airway obstruction syndrome is rare fetal malformation caused by obstruction of fetal airway because of laryngeal or tracheal atresia, sub glottis stenosis, laryngeal cyst or laryngeal web. This syndrome is manifested by the presence of large echogenic lungs ,flattened or inverted diaphragm , a dilated tracheobronchial tree, ascites and other manifestations of non immune hydrops.(1) It is important to diagnose it antenatally as it is uniformly lethal. We report here a case of CHAOS diagnosed at 17 weeks with poor prognostic features which underwent elective termination of pregnancy and diagnosis confirmed by autopsy.

Case report:
A twenty two year old G2P1L1 at 16 weeks 3days was referred to our centre for second opinion regarding non-visualization of stomach and ascites. Patient had a non consanguineous marriage with a sub normal intelligent husband. Her previous baby is 2yrs old with delayed milestones. Cause of developmental delay is not known.

Ultrasound examination revealed a single live fetus corresponding to 17 weeks period of gestation. Amniotic fluid was within normal limits. Bilateral lungs were echogenic and enlarged with small heart compressed in between the lungs. (Fig.1), mild ascites, everted diaphragm (Fig.2 & 3) and dilated bronchi (Fig.4). Based on these findings, the diagnosis of CHAOS was made. Patient and her family members were counselled regarding the possible unfavourable outcome of the pregnancy. The patient opted for termination of pregnancy and the fetus was submitted for detailed autopsy examination.

The autopsy report revealed 200gm male fetus. External examination revealed distended abdomen. Internal examination revealed ascites and enlarged lungs weighing, g with rib notching seen on both lungs. Larynx was completely blocked on probing with guide wire (3 mm below the epiglottis) with post stenotic dilation of trachea and bronchus. (Fig. 5) The heart was compressed in between the lungs.

On Histopathological examination, lungs were found to be in pseudo glandular phase corresponding to 17weeks period of gestation .Section of larynx showed fused arytenoids cartilages and paired muscles across the midline.

DISCUSSION:
Congenital high airway obstruction syndrome is a clinical spectrum which is mostly sporadic and exact incidence is not known. Autosomal dominant inheritance has been reported**. (2)** This is caused by complete or partial obstruction of the airway leading to accumulation of tracheobronchial secretions. This in turn results in hyperinflation of lungs causing the diaphragm to flatten or invert, increased intrathoracic pressure leading to hydrops. Most common cause of obstruction is laryngeal atresia**.(3)** Three types of laryngeal atresia are recognised : type I , in which the supra glottis and infraglottic parts of the larynx are atretic; type II ,in which the atresia is infraglottic ; and type III ,which is glottis.(4)

Antenatal diagnosis can be made primarily with ultrasound. Large echogenic lungs, flattened or inverted diaphragm, a dilated tracheobronchial tree and ascites are the classic features on ultrasound which were found in our case. Polyhydramnios was not seen in our case as it was detected early in the gestation.

Fetal MRI is useful to predict the level of obstruction and identify additional findings related to genetic syndromes and to differentiate between intrinsic and extrinsic causes of obstruction.(3, 5) The most common genetic syndrome associated with CHAOS is Fraser syndrome. This disorder has autosomal recessive inheritance characterized by variable expression of cryptophthalmos, renal agenesis, syndactyly, abnormalities of ears and external genetalia, and laryngeal stenosis or atresia.(6, 7) Often a previously affected pregnancy will prompt Sonographic surveillance for Fraser syndrome. Other syndromes that can have CHAOS as a part of them are Cri-du-Chat syndrome, short-rib polydactyly syndrome, and velocardiofacial syndrome. CHAOS could also be part of association that goes by an acronym TACRD (Tracheal agenesis Complex cardiac anomalies, radial ray defects and duodenal atresia**.(5)**

CHAOS is most often mistaken for congenital airway malformation, especially type III. CCAM is usually lobar, not involving the whole lung.

An important distinguishing feature is the compressed rim of normal lung that can usually be seen in CCAM but not

Volume : 5 | Issue : 6 | June 2015 | ISSN - 2249-555X

in CHAOS.

CHAOS which was once thought to be uniformly lethal is being offered EXIT procedure (ex utero intrapartum treatment) to improve the survival of the fetus. During EXIT procedure, fetal head and chest are delivered by caesarean section, laryngoscopy is performed initially to evaluate the larynx .In most instances, the level of obstruction will be distal to the vocal cords, and the attempts to pass an endotracheal tube will be unsuccessful. Bronchoscopy is then performed. The obstruction due to laryngeal web/cyst may be amenable to bronchoscopic disruption. If these efforts are unsuccessful, a formal tracheostomy is performed. Once the airway is secured, cord is clamped and the infant is handed over to neonatologists.(8) The first long term survivor with CHAOS was reported by Crombleholme in 2000.(9)

Natural history of CHAOS is variable. On rare occasions in utero airway decompression occurs, reversing syndromic findings and improving the prognosis. This spontaneous regression could be due to tracheo-oesophageal fistula that may have decreased the intrathoracic pressure.

Less severe signs of CHAOS and absence of hydrops seem to have favourable neonatal outcome. However, in a few selected patients, appropriate fetal intervention even in presence of hydrops earlier in pregnancy may improve long term outcome.(10)

CONCLUSION:

CHAOS is a rare congenital malformation incompatible with life. It is important to look for associated anomalies as it is a part of various syndromes with autosomal recessive inheritance. Ultrasound is the primary diagnostic tool. MRI imaging helps in evaluating the level of obstruction and plan EXIT procedure in appropriate cases.

Images :



Figure 1. Antenatal ultrasound image of echogenic and enlarged lungs



Figure 2. Antenatal ultrasound image of flattened diaphragm and ascites

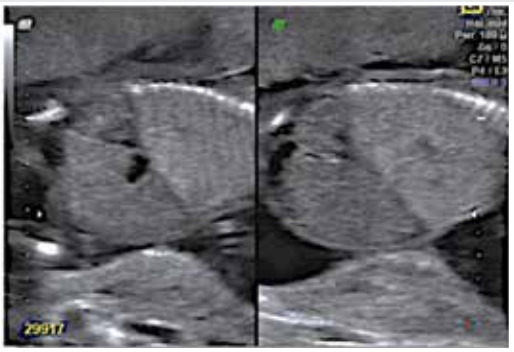

Figure 3. Antenatal ultrasound coronal image showing dilated bronchi



Figure 4. Antenatal ultrasound image showing ascites and everted diaphragm



Figure5. Autopsy images 5A. Showing the enlarged lungs with small heart. 5B. Site of laryngeal atresia (Marked with probe).

Acknowledgements: We thank the department of pathology, PSIMS, Gannavaram for providing us the autopsy images.

Volume : 5 | Issue : 6 | June 2015 | ISSN - 2249-555X

REFERENCE

1. Hedrick MH, Ferro MM, Filly RA, Flake AW, Harrison MR, Adzick NS. Congenital high airway obstruction syndrome (CHAOS): a potential for perinatal intervention. Journal of pediatric surgery. 1994 Feb;29(2):271-4. PubMed PMID: 8176604. Epub 1994/02/01. eng. | 2. Vanhaesebrouck P, De Coen K, Defoort P, Vermeersch H, Mortier G, Goossens L, et al. Evidence for autosomal dominant inheritance in prenatally diagnosed CHAOS. European journal of pediatrics. 2006 Oct;165(10):706-8. PubMed PMID: 16642370. Epub 2006/04/28. eng. | 3. Courtier J, Poder L, Wang ZJ, Westphalen AC, Yeh BM, Coakley FV. Fetal tracheolaryngeal airway obstruction: prenatal evaluation by sonography and MRI. Pediatric radiology. 2010 Nov;40(11):1800-5. PubMed PMID: 20737145. Pubmed Central PMCID: PMC2950274. Epub 2010/08/26. eng. | 4. Garg MK. Case report: Antenatal diagnosis of congenital high airway obstruction syndrome - laryngeal atresia. The Indian journal of radiology & imaging. 2008 Nov;18(4):350-1. PubMed PMID: 19774196. Pubmed Central PMCID: PMC2747465. Epub 2009/09/24. eng. | 5. Joshi P, Satija L, George R, Chatterjee S, D'Souza J, Raheem A. Congenital high airway obstruction syndrome-antenatal diagnosis of a rare case of airway obstruction using multimodality imaging. Medical journal, Armed Forces India. 2012 Jan;68(1):78-80. PubMed PMID: 24669041. Pubmed Central PMCID: PMC3862829. Epub 2012/01/01. eng. | 6. Schauer GM, Dunn LK, Godmilow L, Eagle RC, Jr., Knisely AS. Prenatal diagnosis of Fraser syndrome at 18.5 weeks gestation, with autopsy findings at 19 weeks. American journal of medical genetics. 1990 Dec;37(4):583-91. PubMed PMID: 2175543. Epub 1990/12/01. eng. | 7. Berg C, Geipel A, Germer U, Pertersen-Hansen A, Koch-Dorfler M, Gembruch U. Prenatal detection of Fraser syndrome without cryptophthalmos: case report and review of the literature. Ultrasound in obstetrics & gynecology : the official journal of the International Society of Ultrasound in Obstetrics and Gynecology. 2001 Jul;18(1):76-80. PubMed PMID: 11489232. Epub 2001/08/08. eng. | 8. Bui TH, Grunewald C, Frenckner B, Kuylenstierna R, Dahlgren G, Edner A, et al. Successful EXIT (ex utero intrapartum treatment) procedure in a fetus diagnosed prenatally with congenital high-airway obstruction syndrome due to laryngeal atresia. European journal of pediatric surgery : official journal of Austrian Association of Pediatric Surgery [et al] = Zeitschrift fur Kinderchirurgie. 2000 Oct;10(5):328-33. PubMed PMID: 11194545. Epub 2001/02/24. eng. | 9. Crombleholme TM, Sylvester K, Flake AW, Adzick NS. Salvage of a fetus with congenital high airway obstruction syndrome by ex utero intrapartum treatment (EXIT) procedure. Fetal diagnosis and therapy. 2000 Sep-Oct;15(5):280-2. PubMed PMID: 10971081. Epub 2000/09/06. eng. | 10. Saadai P, Jelin EB, Nijagal A, Schecter SC, Hirose S, MacKenzie TC, et al. Long-term outcomes after fetal therapy for congenital high airway obstructive syndrome. Journal of pediatric surgery. 2012 Jun;47(6):1095-100. PubMed PMID: 22703776. Epub 2012/06/19. eng. |