RESEARCH PAPER | Medical Science | Volume : 5 | Issue : 10 | October 2015 | ISSN - 2249-555X



Solid Pseudopapillary Epithelial Neoplasm (SPEN) of Pancreas: A case report and review of literature

KEYWORDS: SPEN, Solid pseudopapillary epithelial neoplasm, SPT, Solid pseudopapillary tumour, Franz tumours, Hamoudi tumours, papillary cystic neoplasm.

Dr.M.Ilaiah	Dr.P.Mallikarjun	Dr.Faisal Abdul Mujeeb
Professor, Department of General Surgery, Osmania Medical College and Hospital, Hyderabad 500095, Telangana State, India	Associate Professor, Department of General Surgery, Osmania Medical College and Hospital, Hyderabad 500095, Telangana State, India	Department of General Surgery, Osmania Medical College and Hospital, Hyderabad 500095, Telangana State, India

ABSTRACT *Solid pseudopapillary epithelial neoplasm (SPEN) is a rare neoplasm with low malignant potential. They represent 2% of all pancreatic tumours and 9% of pancreatic cystic neoplasms. Only 718 cases have been reported in the last 70 years. Its prevalence is 10-fold higher in women than in men and affected predominantly younger individuals (mean age:22 years).*

Introduction

Solid pseudopapillary tumours of pancreas are rare neoplasms with low malignant potential. They were first described in 1959. Historically several other names have associated with this tumour, including Franz tumours, Hamoudi tumours and papillary cystic neoplasm.

In 1996, World Health Organisation (WHO) classified these tumours as SPTs and further defined malignant SPTs as those tumours with histological characteristics of angioinvasion, perineural invasion, or extension into the surrounding pancreatic parenchyma.

Case Summary

A 22 year old female presented with complains of pain abdomen since 15 days and mass per abdomen since one year. On being investigated by a general physician, an ultrasound of abdomen revealed a mass in the tail of the pancreas. The case was referred to Osmania Hospital Surgery Department for tertiary level care and work up.

On examination, there was fullness of abdomen in left hypochondriac and epigastric region due to a mobile mass measuring 10x8cm and moving with respiration. The mass was tender and firm, without any localised rise in temperature.

Ultrasound revealed a well defined heterogenous isoechoic lesion with areas of hypoechogenecity (?hemorrhagic) measuring 10.2x8cm without any signs of internal vascularity in the distal body and tail region of pancreas. Impression, based on above findings, was of a probably benign pancreatic tail tumour, most likely SPEN. Advised CT with contrast for better evaluation.

CT with IV contrast revealed a large well defined lobulated soft tissue density lesion, heterogeneously enhancing, measuring 7.5x8.9x8cm, in the tail of the pancreas, causing splaying of the pancreatic parenchyma and compression of splenic vessels posteriorly. Impression being that of a Solid Pseudopapillary Tumour of Pancreas.

The above radiological features suggested a large pancreatic tumour in the tail, extending upto the splenic hilum, without any evidence to confirm or deny the involvement of the spleen. Hence the patient was posted for a distal pancreatectomy with a possible splenectomy.

The abdomen was accessed by a rooftop incision. Pancreas is exposed through a window in greater omentum. Tumour found to be extending upto the splenic hilum. After secure ligation of splenic vessels, splenectomy is done by ligation and separation of splenocolic and splenorenal ligaments. Pancreas is transected in the body by leaving a 2cm margin from the tumour and the cut proximal end of pancreas is sutured with a 3-0 prolene continuous non-locking sutures. Tumour with the spleen delivered out. Hemostasis secured and abdomen closed with one flank drain.



Intraoperative image showing tumour in pancreatic tail



Splenic hilum adherent to tumour

Volume : 5 | Issue : 10 | October 2015 | ISSN - 2249-555X

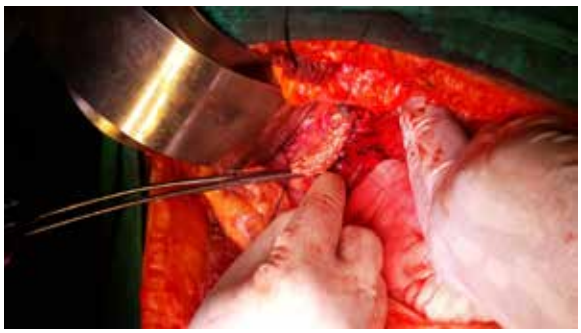

Cut end of pancreas sutured with prolene



Pancreatic tail tumour with spleen (resected specimen)



Cut section of tumour showing cystic degeneration with vascular stalks

The specimen was sent for histopathological examination and was reported as a SOLID PSEUDOPAPILLARY EPITHELIAL NEOPLASM (SPEN) PANCREAS with sections showing tumour tissue arranged in papillary pattern, solid sheets and nests separated by fibrovascular septae. Individual cells are small round to oval with moderate esinophilic cytoplasm and vesicular nuclei with mild pleomorphism. Areas of hyalinisation seen. Sections from spleen showed mild congestion.

Discussion

Solid pseudopapillary tumours of pancreas are rare pancreatic neoplasms with low malignant potential. Also known as Franz tumour, Hamoudi tumour and papillary cystic neoplasm. Malignant features include angioinvasion, perineural invasion, or extension into the surrounding pancreatic parenchyma. SPTs represent approximately 2% of all pancreatic tumours and 9% of pancreatic cystic neoplasms.

SPTs are 10 times more common in women than in men and predominantly affect younger individuals with a mean age of 22 years.

80% patients are symptomatic with pain and/or mass per abdomen being the most common presentation. In asymptomatic patients the tumour may be found on routine examination or as an incidental radiological finding. Although SPT can occur throughout the pancreas, they are slightly more common in the pancreatic tail and when discovered, they are generally large in size (mean diameter 6cm; range, 0.5-34.5cm). On CT imaging, SPTs are characteristically large heterogeneously enhancing lesions with solid and cystic components, and they frequently demonstrate peripheral enhancement and variable calcification. SPTs do not form true cysts; the cystic appearance is secondary to necrotic degeneration of primary cytoarchitecture. As the tumour increases in size, the solid papillary vascular stalks within the tumour slough and hemorrhage.

The differential diagnosis includes other cystic neoplasms including mucinous and serous cystadenomas and intraductal papillary mucinous neoplasms. Cystic degeneration of a typically solid neoplasm such as pancreatic neuroendocrine tumour or acinar cell cancer are included in the differential diagnosis.

Fine needle aspiration (FNA) biopsy is usually inconclusive due to the largely necrotic composition of the tumour. Characteristic cytological features of SPTs include branching papillary fronds with sheets and cords of cells arranged around a fibrovascular septa. The cells contain eosinophilic granules rich in alpha-1-antitrypsin and the nuclei are typically grooved. The immunophenotype is nonspecific with positive staining for vimentin, alpha-1-antitrypsin, neuron specific enolase, CD10 and CD56. Keratins, chromogranin, synaptophysin, and endocrine and pancreatic enzymes are generally not expressed. SPTs often stain positive for progesterone receptors while estrogen receptor positivity is more variable.

The genetic profile associated with SPT is different from pancreatic adenocarcinoma, most notably for an absence of KRAS and DPC4 mutations. SPTs are characterised by the presence of an activating B-catenin gene mutation that interferes with protein phosphorylation.

Surgical resection is recommended for SPT due to their unpredictable but real metastatic potential. Inspite of their large size and tendency to invade critical vasculature, most lesions are usually amenable to complete resection. Pancreaticoduodenectomy or distal pancreatectomy is performed most commonly, with en bloc resection of resection of involved adjacent organs when indicated. Complete margin-negative resection (R0) is associated with long term disease free survival. 10-15% patients have metastases at the time of diagnosis or develop metastases at some point in the future. The most common sites of metastases include liver, mesentry and peritoneum. 5 year survival rate for patients with resectable SPT is 95%. Tumour size, as well as vascular, lymphatic, or perineural invasion have not been useful in predicting recurrence. Presence of nuclear atypia and high mitotic rate may suggest an aggressive subtype. Adjuvant systemic therapy is not routinely utilised due to excellent survival rates following surgical resection alone.

Acknowledgements

The authors are grateful to Dr.Chandrashekhar (Anaesthesiologist), Dr.Ezhil Arasi (Pathologist), Dr.Siva Mohan Naidu (Junior resident/PG), Dr.Manjusha (Junior resident/PG) and Dr.Shadan (Junior resident/PG).

Volume : 5 | Issue : 10 | October 2015 | ISSN - 2249-555X

REFERENCE

1. Frantz VK: Tumors of the pancreas. In Atlas of Tumor Pathology. Washington, DC: Armed forces Institute of Pathology; 1959:32-3. 2. Jung SE, Kim Dyk, Park KW, Lee SC, Jang JJ, Kim WK: Solid and papillary epithelial neoplasm of the pancreas in children. World J Surg 1999 , 23(3):233-6. 3. Pettinato G, Manivel JC, Ravetto C: Papillary cystictumorofthepancreas A clinicopathologic study of 20 cases with cytologic, immunohistochemical, ultrastructural, and flow cytometric observations, and a review of the literature published erratum appears in Am J Clin Pathol 1993;99:764. 4. Lam KY, Lo CY, Fan ST: Pancreatic solidcystic- papillary tumor: clinicopathologic features in eight patients from Hong Kong and review of the literature. World J Surg 1999, 23:1045-50. 5. Pettinato G, Manivel JC, Ravetto C, Terracciano LM, Gould EW, di Tuoro A. Papillary cystic tumor of the pancreas: A clinicopathologic study of 20 cases with cytologic, immunohistochemical, ultrastructural and flow cytometric observations and a review of the literature. Am J Clin Pathol 1992;98:478-88. 6. Friendman AC, Lichtenstein JE, Fishman EK, Oertel JE, Dachman AH, Siegelman SS. Solid and papillary epithelial neoplasm of the pancreas: Solid and papillary epithelial neoplasm of the pancreas. Radiology 1985;154:333-7. Kesari, et al,: Solid psesudo papillary epthelial neoplasm of pancreas 7. Tang LH, Aydin H, Brennan MF, Klinstra DS. Clinically aggressive solid pseudopapillary tumor of pancreas: A report of cases with components of undifferentiated carcinoma and a comparative clinicopathologic anlaysis of 34 conventional cases. Am J Surg Pathol 2005;29:51-2. 8. Kissane JM. Pancreatoblastoma and solid and cystic papillary tumor: Two tumors related to pancreatic ontogeny. Semin Diagn Patho Source of funding - Nil Conflict of interest - None declared