



Transitional Cell Carcinoma Paranasal Sinuses- Significance

KEYWORDS

transitional cell carcinoma, paranasal sinuses ,literature review

* Dr. Navneeta Gangwar

Associate Professor, Department of ENT, Kasturba Medical College, Manipal University, Karnataka, India-576104.

* corresponding author

Balakrishnan R

Professor, Department of ENT, Kasturba Medical College, Manipal University, Karnataka, India-576104

Nayak DR

Professor, Department of ENT, Kasturba Medical College, Manipal University, Karnataka, India-576104

Mahesh SG

Associate Professor, Department of ENT, Kasturba Medical College, Manipal University, Karnataka, India-576104

Mathai AE

Junior Resident, Department of ENT, Kasturba Medical College, Manipal University, Karnataka, India-576104

ABSTRACT

The transitional cell sinonasal carcinomas are rare, non keratinizing variant of squamous cell carcinoma. This commonly involves the sinonasal tract and estimated incidence is 2- 11 percent . But it can also involve the nasopharynx, base of tongue and hypopharynx. There are little data on the biological behaviour of these tumours. Treatment is usually on the lines of squamous cell carcinoma. In this paper we attempt to discuss the clinical presentation, radiology, histopathological features and clinical features of this infrequently encountered tumor by means of three cases, which we encountered

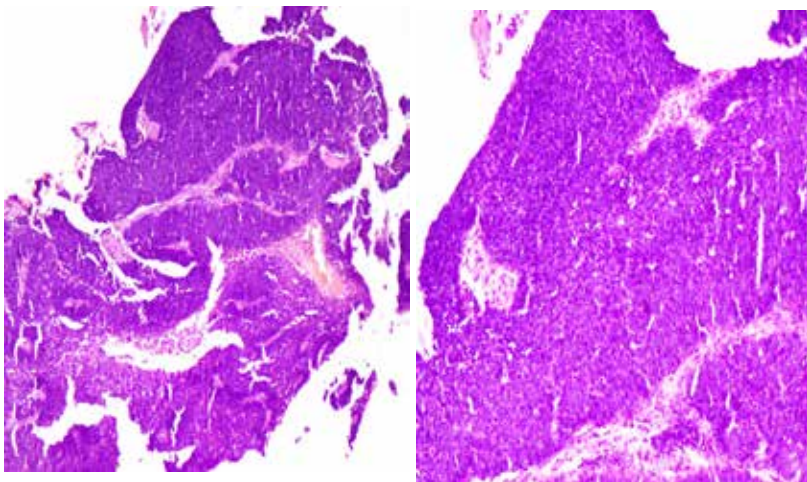
INTRODUCTION-

Paranasal sinus cancers represent about 0.2 percent of all malignant neoplasms and about 3 percent of all upper respiratory and alimentary tract cancers. Transitional cell carcinoma of the PNS is very rarely described. It is entirely different from the TCC of the urinary tract and the prostate gland, and the "transitional cell "of the urinary bladder is not expected to be found histologically in the respiratory system.

The transitional cell sinonasal carcinomas are rare, non keratinizing variant of squamous cell carcinoma. The other terms applied to it are Ringertz carcinoma, Schneiderian carcinoma, cylindrical or columnar cell carcinoma, papillary carcinoma, intermediate cell carcinoma. This entity was initially

described by Ringertz in 1938¹. He noted the cells were in a transitional stage from glandular epithelium into squamous cells. The neoplasm shows squamous cells mixed with lymphoid follicles, and hence sometimes also known as lympho-epitheliomas. They are pathologically characterised by a plexiform or ribbon-like growth pattern, cytological atypia, neoplastic epithelium delineated by a persistent basement membrane and lack of histological evidence of keratinisation. This commonly involves the sinonasal tract and estimated incidence is 2- 11 percent². But it can also involve the nasopharynx, base of tongue and hypopharynx. There is little data on the biological behaviour of these tumours.^{3,4} Treatment is usually on the lines of squamous cell carcinoma.

CASE REPORTS-

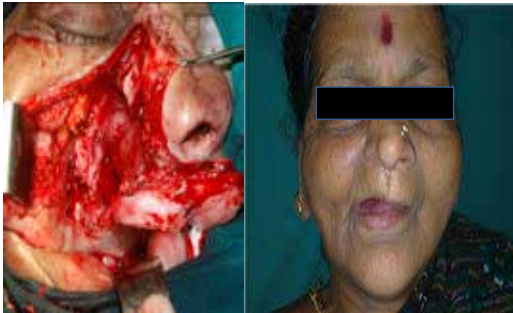

100 X and 200 X H&E Stain Histopathology Images of case 1

CASE 1 - A 60 year old female presented to us with history of off and on epistaxis and right side progressively increasing

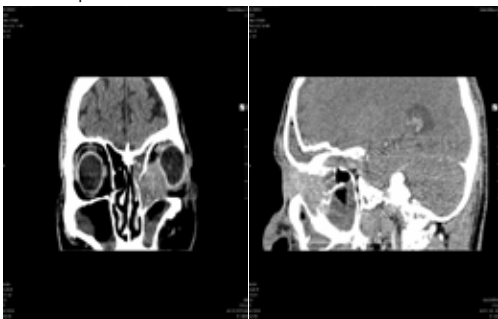
nose block of 6 months duration. There was no other significant positive history. On nasal endoscopic examination a red-

dish fleshy mass was noted in the right nasal cavity between inferior turbinate and septum, superiorly extending upto the roof obscuring the other structures of the nasal cavity. The mass was friable and bled on touch. There was no cervical lymphadenopathy. Ocular and alveolar examination was normal. X-ray of paranasal sinus showed right maxillary sinus opacity with intact bony walls. She underwent right subtotal maxillectomy. Orbital floor was preserved. Biopsy report revealed a tumor composed of papillae and occasional glandular structures of multiple layers of malignant cells. Focal squamoid differentiation seen. Adjoining seromucinous glands with diffuse lymphoplasmacytic infiltration and bony spicules seen. Subepithelial small granulomas composed of epithelioid cells and small foci of fobroid necrosis were seen. Orbital floor and pterygoid muscle was involved by tumor. Postoperatively she underwent external beam radiotherapy (66G/33#) with weekly chemosensitised cisplatin over 6 weeks. On follow up, 3-4 months after completion of radiotherapy she developed right side radiation keratopathy, cortical cataract, dacryocystitis with trigeminal neuralgia which was managed conservatively. Six months after radiotherapy C T paranasal sinuses was repeated. It revealed mucosal thickening posteriorly over the orbital floor. Biopsy taken from that area came negative for any malignant cells. USG neck done one year after did not reveal any lymphadenopathy. She has some trismus and neuralgia but there is no evidence of any recurrence in four year of regular follow up.



Intra-operative And Post Operative Images of case 1

CASE 2- A 67 year old male patient was referred from the ophthalmic department to rule out any ENT cause for the left sided, medial orbital swelling of three months duration. Vision was 6/12 in the left eye. The patient had a past history of left dacryocystectomy six years back, for complaints of bleeding from the same site, the histopathological diagnosis was transitional cell carcinoma. Diagnostic nasal endoscopy revealed a polypoidal mass in the left middle meatus. Biopsy was taken which came as sinonasal transitional cell carcinoma. C T scan revealed a well defined homogenously enhancing extraconal lesion in inferomedial aspect of left orbit involving the maxilla, ethmoid and frontal sinuses. Lesion was displacing the globe superolaterally indenting the inferomedial aspect of left globe with suspicious infiltration of globe and inferior oblique muscle. The patient underwent left fronto ethmoido maxillary resection with orbital extentionation. The patient was advised post op CTRT but the patient was lost to follow up after three months.



Coronal And Sagittal CT scan images of Case 2

CASE 3- A 38 year old male patient presented to us with left sided nose block, nasal discharge and epistaxis of one year duration. Diagnostic nasal endoscopy revealed a granular mass filling the left middle meatus and the nasal cavity. Biopsy taken on OPD basis just revealed chronic inflammation. CT scan revealed soft tissue density involving left maxillary sinus, left nasal cavity. He underwent functional endoscopic sinus surgery. Granular mass was removed, from the maxillary sinus, middle meatus and nasal cavity between septum and middle turbinate. To our complete surprise the histopathological diagnosis came as transitional cell carcinoma of maxillary sinus. Patient was advised post op CTRT which he declined, but he has been on regular follow up since then. Now it more than four years since the operation and he has not shown any signs of residual or recurrent tumor on repeated endoscopic evaluation.

DISCUSSION-

D.A.Osborn is of the opinion that the very name transitional cell carcinoma seems to perpetuate the concept of a tumor of transitional cells, and it might be helpful to delete the word 'cell' and call the present tumor simply transitional carcinoma, implying a carcinoma arising from or assuming the structure of transitional epithelium. Ringertz was the first to describe a series of 27 tumors of solid cylindrical cells in the nasal cavity and paranasal sinuses in 1938. ⁽¹⁾ Larsson and Martensson⁽⁵⁾ reported another series of 34 cases on this rare entity about half a century ago. Osborn reported 39 cases of paranasal transitional cell carcinoma in 1970⁽⁴⁾. In the WHO classification, the nomenclature 'cylindric' is preferred to transitional carcinoma due to the varied interpretation of term 'transitional' because of its resemblance to transitional epithelium of urinary bladder or 'transition' referring to intermediate features between respiratory epithelium cells and squamous epithelium. Surprisingly, the literature is sparse on this variant of squamous cell carcinoma after these reports. The many other published series of carcinomas of this region either record a much lower incidence or do not appear to recognise its existence as a histologic entity.

Pathologically, these tumors are well-differentiated non-keratinizing carcinomas. They have ribbon of cells which may invaginate and form crypts. Sometimes invaginations of these ribbons of cells may be filled completely by solid tumor cells. Islands of stroma may be seen when these tumor columns become confluent. These cylindrical cells are seen at right angles to the basement membrane. A distinct feature described by Osborn et al⁽⁴⁾ is the phenomenon of dedifferentiation occurring in the basement membrane. Foci of malignant squamous metaplasia are usually seen in cylindrical cell carcinoma which may create diagnostic dilemma for squamous cell carcinoma. Osborn has also estimated that there is 2-5% chance of papilloma being converted into transitional cell carcinoma. However Buchanan and Slavin⁽⁶⁾ did not find any evidence, in their seven patients of transitional cell carcinoma, of origin from a previously simple papilloma.

In the management of their cases, it is usual for surgeons not to be influenced by histologic subdivisions of carcinoma; such classification bear no practical implications. The particular interest in transitional cell carcinomas of this region centers on the analysis of survival patterns. Ringertz⁽¹⁾ first suggested the possibility of a better prognosis in this type of carcinoma more than 60 years ago, but no further interest was shown until Larsson and Martensson⁽⁵⁾ reported a 5 year survival rate of 36% as compared with 28% for squamous carcinoma. In a smaller series, Osborn and Winston⁽⁷⁾ found a 5 year survival rate for transitional carcinoma of 45%, as compared with 11.5% for squamous and 20% for anaplastic carcinomas of the paranasal sinuses. Metastasis in lymph nodes are generally regarded as being relatively uncommon in paranasal carcinoma. The incidence, mainly without histologic confirmation, was 10% for transitional as compared with 17% each for squamous and anaplastic carcinomas of the paranasal sinuses⁽⁴⁾. In our three cases none had nodal

metastasis and two cases have had more than two years of disease free survival till now, which is reinforcing the above mentioned facts.

Review of literature reveals two isolated case reports of this tumor involving only the maxillary sinus^(8,9). Out of these the first case had early metastasis and poor response to radiotherapy, the second case had only local involvement and was managed by surgical excision and post op radiation with good prognosis. Manivel et al⁽⁹⁾ reported two cases of transitional cell carcinoma with endodermal sinus tumor like features in the nasopharynx and paranasal sinuses. Both patients were treated with irradiation and multidrug chemotherapy. One patient died of uncontrollable recurrence of tumor, whereas the other developed locally recurrent, transitional cell carcinoma in the absence of yolk cell tumor. They regarded these tumors as basically transitional cell carcinomas in which divergent differentiation has occurred towards the line of endodermal sinus tumor. The concurrence of these patterns of carcinoma, seemed to be associated with more aggressive biologic behaviour than pure transitional cell carcinomas of this region. They recommended the use of germ-cell-tumor-directed chemotherapy in the treatment of such

tumors with features of germ cell differentiation. Milind et al have reported a case of transitional cell carcinoma of the base of tongue which was managed by palliative radiotherapy of 20Gy in five fractions followed by chemotherapy with paclitaxel and carboplatin⁽¹⁰⁾.

Our first case has shown good results with surgery and post op CRT and third case has equally comparable results till now with wide local endoscopic resection, may be because the tumor was limited in its extent and not very aggressive in nature.

CONCLUSION-

Little is known about the biological behaviour and treatment of transitional cell carcinomas. In light of the sparse knowledge, these tumors are best treated on the lines of squamous cell carcinoma. There are no published reports on the use of newer chemotherapeutic agents or targeted therapy specifically for transitional cell carcinoma. Our case showed good response with cisplatin, which can be used along with radiotherapy. The treatment of such cases should be individualized due to infrequent occurrence of such malignancy.

REFERENCE

1. Ringertz N. Pathology of malignant tumors arising in the nasal and paranasal cavities and Maxilla. *Acta Otolaryngol(suppl.)* 1938; 27: 33-41; 104-117. | 2. Hopkin N, McNicoll W, Dalley VM, Shaw HJ. Cancer of the paranasal sinuses and nasal cavities. Part I. Clinical features. *J Laryngol Otol* 1984; 98: 585-95. | 3. Manivel C, Wick MR, Dehner LP. Transitional (Cylindric) cell carcinoma with endodermal sinus tumor like features of the nasopharynx and paranasal sinuses: Clinicopathologic and immunohistochemical study of two cases. *Arch Pathol Lab Med* 1986; 110: 198-202. | 4. Osborn DA. Nature and behaviour of transitional tumors in the upper respiratory tract. *Cancer* 1970; 25: 50-60. | 5. Larsson LG, and Martensson G. Carcinoma of the paranasal sinuses and the nasal cavities. *Acta Radial* 1954; 42: 149-72. | 6. Buchanan G, and Slavin G. Tumours of the nose and sinuses: A Clinicopathological study. 1998 (July); 84: 685-696. | 7. Osborn DA, and Winston P. Carcinoma of the paranasal sinuses. *J Laryng.*1961; 75: 387-405. | 8. Stockdale CR. Transitional cell carcinoma of the maxillary sinus. *O.S.,O.M and O.P.*1959 (Feb); 12(2): 206-210. | 9. Lam W. Transitional cell carcinoma of the maxillary sinus. *Australian Dental Journal.* 1981 (June); 26(3): 172-174. | 10. Kumar et al. Cylindric cell carcinoma of the base of the tongue: A rare variant of squamous cell carcinoma. *J C R T* 2009;5(2): 124-126. |