



Percutaneous Fixation of Proximal Humerus Fractures With External Fixator in High Risk Patients

KEYWORDS

Dr. N.M.Bhavsar

Assistant Professor, Dept. of Orthopaedics, V.S.G.H

Dr. P.N.Patel

Senior Resident, Dept. of Orthopaedics, V.S.G.H

Dr. S.J. Patel

Senior Resident, Dept. of Orthopaedics, V.S.G.H

Dr. N.P. Parikh

3rd Year Resident, Dept. of Orthopaedics, V.S.G.H

Dr. P.R. Patel

Professor, Dept. of Orthopaedics, V.S.G.H

Dr. N.A. Lil

Associate Professor, Dept. of Orthopaedics, V.S.G.H

ABSTRACT *The incident of the proximal humerus fractures in on the rise in the last decade. Many treatment options are available like conservative treatment, open reduction internal fixation, joint replacement, and percutaneous fixation.).ORIF is associated with surgical trauma, higher rates of infection, avascular necrosis of the humeral head, and neurovascular lesions. Therefore the trend has changed in a past few years from massive internal fixation to closed reduction and minimal fixation. The advantages of the percutaneous pinning are not only the possibility of preservation of the blood supply to bone fragments, no blood loss and the possibility of surgery under brachial block. The latter prerogatives may be of considerable importance when treating patients in poor general condition, such as those in American Society of Anesthesiologists(ASA) physical status (PS) three or four. Adding an external fixation to this minimizes the complications of pinning.*

Between 2010 and 2012 ASA PS three or four assigned to 35 patients admitted at our hospital with proximal humerus fracture. Patients were classified according to NEER's classification were taken for closed reduction and percutaneous pinning. Thirty (17 female and 13 male) out of these 35 were available for evaluation both radiologically and clinically with an average follow up of 8 months (range from 6 months to 1 year). Five patients were not included in the study as they were lost to follow up. The average age of the patients was 66.56(range 52 to 87). There were 3 with two part, 26 with three part and 1 with four part.

Twelve patients (40%) had excellent results, fourteen (46%) had good, two (6.66%) had fair and two (6.66%) had poor results. The average constant score was 84.26(range 39 to 96).The average age of the patient with two part fracture was 61 years compared with 67 years for three part fractures.

The two-part fractures had better results than the three part fractures, with an average Constant score, adjusted for age and gender, of 91(range 87-95) and 83.86(range39- 96) respectively.

Percutaneous pinning is a good treatment option in high operative risk patients and adding an external fixation to that helps in maintaining valgus of the head of humerus, it minimizes the complications of percutaneous pinning even in osteoporotic patients.

INTRODUCTION:

The incident of the proximal humerus fractures in on the rise in the last decade. It is about 4-5% of all fractures out of which 70% occurring in patients over 60 years (1). Neer's classification is an accepted system to describe these fractures (2). Many treatment options are available according to the fracture pattern, amount of displacement, bone stock, pre-existing rotator cuff disease, arthrosis, patient's age and general condition(3). They are conservative treatment, open reduction internal fixation, joint replacement, and percutaneous fixation. Good clinical outcome has been reported from ORIF – 92%(4), conservative treatment – 87%(5) and 87.5% from shoulder arthroplasty(6,7). Advantages of the ORIF are anatomic restoration and early mobilization, but it is associated with surgical trauma, higher rates of infection, avascular necrosis of the humeral head, and neurovascular lesions (4). Therefore the trend has changed in a past few years from massive internal fixation to closed reduction and minimal fixation(8), which is a less invasive method associated with less damage to the soft tissue and a low rate of avascular necrosis of the femoral head.

The advantages of the percutaneous pinning are not only

the possibility of preservation of the blood supply to bone fragments, no blood loss and the possibility of surgery under brachial block. The latter prerogatives may be of considerable importance when treating patients in poor general condition, such as those in American Society of Anesthesiologists(ASA) physical status (PS) three or four(3,9). Disadvantages being no anatomic reduction or early mobilization, varuscollaps, pin migration and pin tract infection.

So we have tried using an external fixation (10) along with percutaneous pinning with the aim to minimize some of these complications.

MATERIALS AND METHODS:

Between 2010 and 2012 ASA PS three or four assigned to 35 patients admitted at our hospital with proximal humerus fracture. Patients were classified according to NEER's classification were taken for closed reduction and percutaneous pinning. Thirty (17 female and 13 male) out of these 35 were available for evaluation both radiologically and clinically with an average follow up of 8 months(range from 6 months to 1 year). Five patients were not included in the study as they were lost to follow up. The average

age of the patients was 66.56(range 52 to 87). There were 3 with two part, 26 with three part.

All patients were operated within one week of injury. Patients were given brachial block and put in a beach chair position on a radiolucent table. Close reduction was done under fluoroscopic control. 2.5 mm partially threaded k-wires were used. Two k wires were put from shaft to head of humerus and two from greater tuberosity towards the shaft. Another wire was inserted from anterior cortex of the shaft humeruslateral to biceps tendon to humeral head. Three to five pins were inserted in each case reaching the subchondral bone. 3.5mm external fixator was applied connecting to the first four wires.

Postoperatively shoulder immobilizer applied for 4 to 6 weeks. Shoulder pendulum exercises were started at two weeks. Patients were examined in outpatient clinic at 3 weeks, 6 weeks, 3 months, 6 months and 1 year. AP and axial view of proximal humerus were taken to assess fragment, union and signs of AVN. Clinical evaluation was done with constant score.

RESULTS:

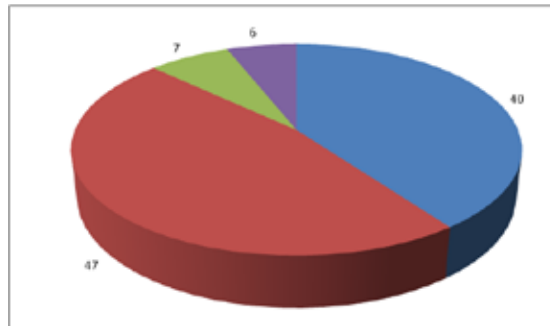
Twelve patients (40%) had excellent results, fourteen (46%) had good, two (6.66%) had fair and two (6.66%) had poor results. The average constant score was 84.26(range 39 to 96).The average age of the patient with two part fracture was 61 years compared with 67 years for three part fractures.

The two-part fractures had better results than the three part fractures, with an average Constant score, adjusted for age and gender, of 91(range 87-95) and 83.86(range39-96) respectively.

All patients with two-part fractures had no pain at all; two had no limitation of daily activities. Minimal limitation of abduction associated with the two-part fractures in one patient. Two of three patients had forward flexion and abduction greater than 155 degrees. With regards to internal rotation, two could touch their shoulder blades with the back of their hands, and one could touch the T12 vertebrae. Two of the three patients were very satisfied with the outcome. There was no medialisation of the shaft or significant angulation of the humeral head on x-ray in this group.

In Patients with three-part fractures sixteen of 26 patients had no pain at all. Forward flexion and abduction in sixteen of 26 patients had more than 150 degree, no limitations in daily activities. With regard to internal rotation, 16 patients could touch their shoulder blades with back of their hand, 6 reached the T12 vertebrae, 2 reached the lumbar spine and 2 patients reached only the sacro-iliac joint.

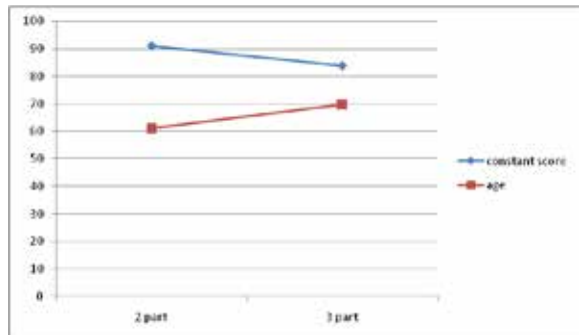
In four of 30 cases(13%) significant secondary displacement due to failure of fixation occurred. All these patients had three-part fractures. The average age of the four patients was high(78 years in comparison with 67 years for entire three part fracture group). All of them had a significant loss of head shaft alignment but there was no varus collapse and reasonable movements with fair and poor constant score.In 3 cases there was superficial wound infection at the site of pin insertion which resolved after pin removal.



- 40% Excellent results
- 47% Good results
- 7% Fair results
- 6% Poor results

• AVERAGE CONSTANT SCORE

FRACTURE TYPE	AVERAGE CONSTANT SCORE
2- part	91
3-part	83.26



Discussion:

Majority of the patients with proximal humerus fractures are above 60 years old, and most of these fractures in these population due to osteoporosis (12) . Conservative treatment in a sling followed by functional rehabilitation under the supervision leads to satisfactory results in minimally displaced fractures whereas, displaced two and three part fractures need to be reduced and stabilized (13) . Closed reduction and percutaneous pinning techniques are of paramount importance when treating elderly patients with cardio-vascular or pulmonary diseases, particularly those in ASA PS three or four, in whom anesthesia is very risky or clearly contra-indicated.

Open reduction and internal fixation in this population has some complications like increased morbidities due to anesthesia, more soft tissue damage, risk of avascular necrosis of humeral head (AVN) causing functional impairment. Percutaneous pinning seems to be a suitable alternative to other operative techniques like intra-medullary nailing, open/mini-open reductions and internal fixations using wires and plates (14, 15). Though this technique has some complications like they may allow less anatomical reduction of the bone fragments, pin loosening, pin track infections and progressive varus collapse. However, several studies have shown that less anatomical reduction of the fragments is not a major drawback in most of the proximal humerus fractures as the results can be satisfactory (14,16,17,18) . Many of these complications can be prevented by adding an external fixator. By adding an external fixator varus collapse is prevented and pin loosening is

less because the site of fixation is shifted from cancellous bone of the proximal humerus to the stronger bone of the lateral cortex of the humerus.

So far, two methods of percutaneous pinning with the use of a device locking the end of the pins have been described. In one of them, the locking device called "humerus block" is placed deep to the lateral portion of the deltoid muscle, just over the cortical bone of the uppermost humeral diaphysis through a 4 cm skin incision. This device can lock two pins and is left on site (16). In another one, pins are attached with a "MIROS" system. Both of these run through the same principle of preventing the varus collapse (3). Just like "MIROS" system, by putting an external fixator, four pins can be stabilized, it is cost effective and it does not require any incision. Results of our study were comparable to them.

CONCLUSION:

In our studies there was no major complication, healing was achieved in all patients and no patient had a migration of greater trochanter. There are certain limitations to this study like; it is an observational study and lack of long follow up. However we can conclude that percutaneous pinning is a good treatment option in high operative risk patients and adding an external fixation to that helps in maintaining valgus of the head of humerus, it minimizes the complications of percutaneous pinning even in osteoporotic patients.

REFERENCE

1. Francesco M. et al. (Long term results of percutaneous fixation of proximal humerus fractures) IJO NOV'12(46):664-7. | 2. Neer CS 2nd (1970) Displaced proximal humeral fractures. Classification and evaluation. J Bone Joint surgery Am 52:1077-89. | 3. Stefano C. et al. (Percutaneous pinning of three- or four-part fractures of the proximal humerus in elderly patients in poor general condition: MIROS versus traditional pinning) International Orthopaedics (SICOT)(2012) 36:1267-73. | 4. Ring D. Current concepts in plate and screw fixation of osteoporotic proximal humerus fractures. Injury 2007;38:559-68. | 5. Zyto K, Ahrengart L, Sperbert A, Törnkvist H. Treatment of displaced proximal humeral fractures in elderly patients. J Bone Joint Surg Br 1997;79B:412-7. | 6. Reitman RD, Kerzhner E. Reverse shoulder arthroplasty as treatment for comminuted proximal humeral fractures in elderly patients. Am J Orthop 2011;40:458-61. | 7. Esen E, Dogramci Y, Gultekin S, Devci MA, SulcuovaFanatli U, Bolukbasi S. Factors affecting results of patients with humeral proximal end fractures undergoing primary hemiarthroplasty: a retrospective study in 42 patients. Injury 2009;40:1336-41. | 8. Szyszkowitz R, Schippinger G (1999) Fractures of the proximal humerus. Unfallchirurg 102(6):422-8 | 9. Owens WD, Felts JA, Spitznagel EL (1978) ASA physical status classifications: a study of consistency of ratings. Anaesthesiology 49:239-42 | 10. Blonna D, Castoldi F, Scelsi M, Rossi R, Falcone G, Assom M (2010) The hybrid technique : potential reduction in complications related to pins mobilization in the treatment of proximal humeral fractures. J Shoulder Elbow Surg 19(8):1218-29. | 11. | 12. Kristiansen B, Barfod G, Bredesen J, et al. Epidemiology of proximal humeral fractures. Acta Orthop Scand. 1987;58(1):75-7. | 13. Williams GR, Wong KL (2000) Two part and three part fractures: open reduction and internal fixation versus closed reduction and percutaneous pinning. Orthop Clin North Am 31(1):1-21 | 14. Chen CY, Chao Ek (1998) Closed management and percutaneous fixation of unstable proximal humerus fractures. J Trauma 45(6):1039-45 | 15. Soete PJ, Clayton PE (1999) Transitory percutaneous pinning in fractures of the proximal humerus. J shoulder Elbow surg 8(6):569-73 | 16. Resch H, Povacz P, Fröhlich R, Wambacher M (1997) Percutaneous fixation of three – and four-part fractures of the proximal humerus. J Bone Joint Surg Br 79:295-300 | 17. Jaberg H, Wamer JP, Jacob R P (1992) Percutaneous stabilization of unstable fractures of the humerus. J Bone Joint Surg Am 74:508-14 | 18. Neer CS II (1970) Displaced proximal humeral fractures. II. Treatment of three-part and four-part displacement. J Bone Joint Surg Am 52:1090-1103