



## Post Auricular Neurofibroma After Tympanomastoid Surgery - A Rare Case Report

### KEYWORDS

Cortical mastoidectomy, Neurofibroma, Papilloedema

**Dr. Manas Ranjan Rout**

Assistant Professor, Department of ENT and Head & Neck Surgery, ASRAM Medical College, Eluru, A.P (India)

**Dr Ch P Das**

Professor and HOD, Department of ENT & HNS ASRAM Medical College, Eluru

**ABSTRACT** Complications in tympanomastoid surgery are rare in experienced surgeon's hand. Still many complications have been reported in the literature. Injury to facial nerve, sigmoid sinus, jugular bulb, mastoid emissary vein, dura and ossicular chain are common complications of mastoidectomy. There are some rare complications like pneumocephalus, pneumomediastinum, and Papilloedema and brain abscess following mastoid surgery. Post mastoidectomy tetanus is also a rare complication reported in the literature. Neurofibroma after tympanomastoid surgery is a very rare complication we are presenting here. A 20 Year male patient came with history of painful swelling behind the left ear since four months which started two months after cortical mastoidectomy and tympanoplasty in same ear done in our hospital. Mass was excised under local anaesthesia and sent for histopathological study. Report came as neurofibroma. Post operatively patient became asymptomatic and under follow up.. Post auricular neurofibroma after tympanomastoid surgery is a rare complication and not been reported in literature. We are reporting this case because of its rare occurrence.

### Introduction

Mastoidectomy is a surgical procedure by which the disease from the mastoid antrum, air cell system and aditus ad antrum are removed, particularly in case of mastoiditis and chronic suppurative otitis media with cholesteatoma.

There are so many complications of mastoidectomy and more in the hand of an inexperienced surgeon. Complications are because of abnormal anatomy, altered anatomy due to disease process, destruction of coverings of the vital structures like dural plate, sinus plate and facial canal etc.

Usual complications of mastoidectomy are injury to facial nerve causing facial palsy, injury to sigmoid sinus, dura and middle ear structures like ossicles are also found in some cases. Some rare complications like pneumocephalus, pneumomediastinum, papilloedema, surgical emphysema and brain abscess following mastoid surgery have been reported in the literature.

Tetanus after mastoidectomy is also a very rare complication reported in the literature.

Neurofibroma may develop because of trauma (Surgical or Non surgical). Neurofibromin regulates fibroblasts in response to injury. Mast cells and inflammatory response are linked to tumor formation.

Neurofibromas are benign neoplasm derived from the myelin sheath of peripheral nerve. They often occur in the context of neurofibromatosis, a hereditary condition.

This case of post auricular neurofibroma after tympanomastoid surgery, we are reporting because of its rare occurrence.

### Case report

A 20 year male patient came to our ENT out patient department with chief complaints of intermittent discharge from left ear since 4 months which at times associated with pain and decreased hearing in that ear since 3months. There was no history of foul smell discharge. Detail history was taken and thorough clinical examination was done. He was a non smoker and non alcoholic from a family of low socio-economic status.

On examination of left ear, there was a big central perforation involving both antero-inferior and posterior-inferior quadrant with congested and edematous middle ear mucosa. Mastoid tenderness was positive on the tip of the mastoid process. Eustachian tube function was normal. Other ear was normal and he was having normal nose and throat findings. Tuning fork test revealed conductive hearing loss.

Left mastoid was sclerotic on X-ray mastoid. CT scan was showing normal ossicular chain, semicircular canals, cochlea and facial canal with evidence of mastoiditis. There was no evidence of cholesteatoma in the middle ear, attic or mastoid. Pure tone audiometry showed conductive type of hearing loss on left ear with 35 dB hearing loss.

Patient was diagnosed to be "Left Chronic suppurative Otitis media with big central perforation having conductive hearing loss and mastoiditis" and planned for cortical mastoidectomy with tympanoplasty at the same sitting.

After all routine investigations including screening tests for retro virus and hepatitis viruses and with all preventive measures like tetanus toxoid vaccine and lignocain test, surgery was done under general anesthesia.

Cortical mastoidectomy was done by post auricular approach and all the disease air cells were removed. Intra operatively there was a big mastoid cavity because of bone erosion. Polypoid mucosa and granulation tissues found in the mastoid cavity were removed. Aditus ad antrum was patent and middle ear was having normal and mobile ossicular chain. Type-1 tympanoplasty was done using temporalis fascia graft.

Immediate post operative period was uneventful and patient was doing well. We discharged patient on 7<sup>th</sup> postoperative day.

There after he came for regular follow up in every 15 days.

After two months patient developed a small swelling over the post auricular incision near tip of the mastoid process. He was complaining of intermittent neuralgic pain over the swelling which was more at night causing disturbance in sleep. Swelling was progressively increasing in size to attend the size of 2 cm x 2cm. Swelling was reddish – brown in color,

having smooth surface and tender on palpation.

Patient was diagnosed clinically as traumatic neuroma or foreign body granuloma and planned for excision.

Mass was excised under local anaesthesia using 2% xylocain infiltration and sent for histopathological study.(Figure-2)

Histopathological report revealed hyperplastic fibrous component and neural components arranged in the form of fascicles and at places arranged in bundles and verrucae like bodies with areas of hyalinization. The tumor cell revealed elongated spindle cells with spiriform nuclei, interspersed by fibroblasts. This histological feature suggestive of neurofibroma.(Figure-1)

Patient became asymptomatic after surgery and under regular follow up.

### Discussion

Mastoidectomy is an operation performed to remove disease from the mastoid antrum, air cell system (when present), aditus ad antrum and sometimes middle ear. Broadly mastoidectomy has been classified in to open cavity mastoidectomy and closed cavity mastoidectomy.

Facial palsy is the most common serious surgical complication during all type of mastoidectomy. Injury to sigmoid sinus superior petrosal sinus, jugular bulb or mastoid emissary veins results in an alarming profuse venous bleeding (1). Complications of open cavity mastoidectomy include deafness or further hearing loss, vestibular symptoms, cerebrospinal fluid leak, infection and recurrent cholesteatoma or drainage (2).

There are some rare complications mastoidectomies reported by different authors.

Lela Migirov et al reported four cases of intra cranial complications following mastoidectomies. Out of four children one was having brain abscess, one having subdural empyema, one having epidural collection and fourth on having sigmoid sinus thrombosis (3).

Dayasena RP et al reported the rare complications like surgical emphysema and pneumomediastinum following mastoidectomy (4).

P. Harkness et al reported an unusual complication of mastoidectomy, papilloedema following cortical mastoidectomy as a part of endolymphatic sac decompression (5).

F Jégoux et al reported a case of pneumocephalus in 43 year old women 37 years after mastoidectomy (6).

Girgis BA et al reported a case of nominal aphasia following radical mastoidectomy (7). A rare complication of cerebral abscess following mastoidectomy for chronic otitis media was reported by Amit Agrawal et al (8).

Manas et al has reported a very rare case of tetanus infection following mastoidectomy.(9).

Neurofibromas are benign neoplasm derived from the myelin sheath of peripheral nerve. They often occur in the context of neurofibromatosis, a hereditary condition.

These are benign or non cancerous tumors that grow on nerve through out the body. There are three major types of neurofibromas ie; cutaneous neurofibroma, spinal neurofibroma and plexiform neurofibroma.

Cutaneous neurofibromas are also called discrete or dermal neurofibromas. These tumors grow from small nerves in the skin or just under the skin and appear as small bumps typically beginning around the time of puberty. It is less common to see this type of neurofibroma in young children with Neurofibromatosis type-1.

Cutaneous neurofibroma rarely cause medical problems but may itch or be tender when bumped. It is important to note that these tumors remain benign throughout life and do not become malignant cancers. Despite their benign nature, they may cause significant cosmetic problems and occasionally required removal.

Neurofibroma may develop because of trauma (Surgical or Non surgical). Neurofibromin regulates fibroblasts in response to injury. Mast cells and inflammatory response are linked to tumor formation.

### Conclusion

So here we have reported a rare case of neurofibroma, a nerve sheath tumor after tympanomastoid surgery, which presented to us with painful swelling behind the ear two months after ear surgery. It's a traumatic neurofibroma after surgery.

### Photos

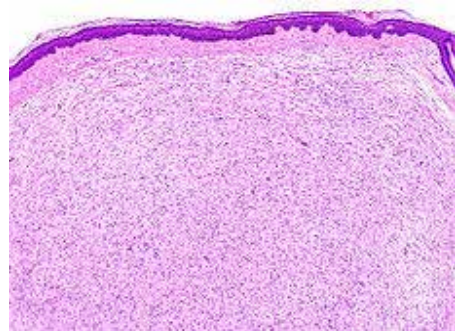


Figure 1(Histopathological study)

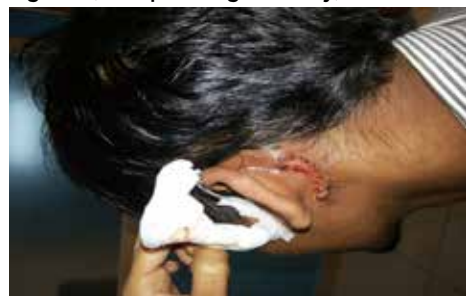

Figure 2 (Post operative picture)

### REFERENCE

1. Michel E Glasscock III, Aina julianna Gulya, Glasscock-Shambaugh Surgery of the ear, New delhi, Elsevier India – a division of Reed Elsevier India Pvt Ltd, 2003, Glenn D Johnson, Simple Mastoid Operation, 487 – 497. | 2. Michel E Glasscock III, Aina julianna Gulya, Glasscock-Shambaugh Surgery of the ear, New delhi, Elsevier India – a division of Reed Elsevier India Pvt Ltd, 2003, John F.Kveton, Open Cavity Mastoid Operations, 499 – 515. | 3. Lela Migirov , Ana Eyal , Jona Kronenberg , Intracranial Complications following Mastoidectomy, Pediatric Neurosurgery, 2004;40:226-229 | 4. Dayasena RP, Soodin D, Habaragamuwa BW, Ganthune S., Surgical emphysema and pneumomediastinum following mastoidectomy, Ceylon Med J. 2007 Dec;52(4):146-7. | 5. P. Harkness , R. Dossetor and J. Weighill , Papilloedema, an unusual complication of mastoidectomy, The Journal of Laryngology & Otology ,September 1996 , 110 : pp 878-880 | 6. F Jégoux, B Godey, L Riffaud, X Morandi , Pneumocephalus as a delayed mastoidectomy complication, The Journal of laryngology and otology (2007) ,Volume: 121, Issue: 4, Pages: 401-403 | 7. Girgis BA, Siegler J, Nominal aphasia following a radical mastoidectomy, J Laryngol Otol. 1986 May;100(5):595-7 | 8. Amit Agrawal , Akshay Pratap , Ishwar Singh , Anand Kumar , Sangeeta Shrestha, Cerebellar Abscess following Mastoidectomy for Chronic Otitis Media, Pediatric Neurosurgery, 2007;43:327-329 | 9. Manas RR, CP Das, Tetanus after ear surgery – a very rare case report; Int Journal of Scientific research, Vol 3, Issue 3, march 2014, P270-271. |