



Evaluation of Breast Cancer Metastasis to The Skeletal System by Using Bone Scintigraphy

KEYWORDS

Breast, Cancer, Metastatic, bone scintigraphy

Mohammed A. Ali Omer

College of Medical Radiologic Science, Sudan University of Science and Technology, Khartoum-Sudan. and College of Applied Medical Science, Qassim University, Buraydah-KSA.

M. E. M. Gar-alnabi

College of Medical Radiologic Science, Sudan University of Science and Technology, Khartoum-Sudan.

Mohamed Yousef

College of Medical Radiologic Science, Sudan University of Science and Technology, Khartoum-Sudan. and College of Applied Science, Taibah University, Almadinah Almunawarah, KSA

Gada A.E. Sakin

College of Medical Radiologic Science, Sudan University of Science and Technology, Khartoum-Sudan.

ABSTRACT

The aim of this study was to evaluate the breast cancer metastasis to specific preference parts of skeletal system using bones scintigraphy with consideration to metastatic from both breasts. The sample consists of 430 patients who referred for bone scintigraphy at radiation and isotopes center in Khartoum during 2010-2013, after a confirmation of breast cancer based on histology, more variables as gender, age, involved quadrant and breast, anatomical sites of metastasis from both breast have been collected and analyzed. The analysis reveals that the left breast was highly involved by cancer 64% relative to right one. Breast cancer starts on age group of 20-30 years old and taking the plateau at 40-50 years old then decreases following aging. The right and left breasts cancer commonly gives metastases to lumbar vertebrae (26.7%, 22%), then dorsal vertebrae (14%, 19%), the pelvic bone (10%, 12.7%), the ribs (5%, 11.3%), the cervical vertebrae (8.7%, 10.7%), the skull (7.3%,) and the femur bone with percentage of (6.7%, 10%) respectively and the right breast cancer gives higher metastatic percent to skeletal system segments 58.1% (250) than the left breast cancer 41.9% (180), the predominant type of histopathology was Invasive ductal carcinoma (IDC) that representing 38% then the Adenoid carcinoma 27% and invasive lobular carcinoma 17%. The common involved quadrant by cancer was the upper outer quadrant UOQ 44%, inner upper quadrant 17%, lower outer quadrant LOQ, lower inner quadrant LIQ and the nipple showed the following percentages 17%, 15%, 13%, and 11% respectively.

1. INTRODUCTION

Breast cancer is an abnormal cell growth, the growth of which is uncoordinated with the normal one and persists with excessive manner after the cessation of the stimuli that evoke it [1], with a tendency to metastasize to other vital organs via circulatory system, lymphatic system and direct invasion. The phenomena of cancer metastasize is due to some properties of the cancer cell, as cancer cells show uncontrolled mitotic divisions causing unorganized growth, amebic movement and cancer cells do not undergo differentiation [2]. The breast cancer is commonly affecting female with a percentage rate equal to 34.5% in Sudan [3] and scarcely among males 0.1%. such high incidence of breast cancer among female also confirmed by Kathleen et al, [4] in which they ascribed the high incidence of female breast cancer to estrogen hormone that promotes the development of breast cancer as also stated by UNFPA, [5] and El Ayass et al, [6]. However, some women are susceptible to breast cancer than others in a condition of the followings: relative involvement with breast cancer (Sisters, Mothers), historical relation with breast cancer or benign tumor\ disease, early menstrual period or younger, late menopause, infertility, radiation exposure at chest wall, administration of estrogen in high doses after menopause and obesity [7] as well as the race, in which Anderson et al, [8] concluded that the breast cancer incidence is higher in black women with percentage of 15.5 than in white women with percentage of 13.1 among women younger than 40 years. Also some studies suggest that the more alcohol intake the greater the risk of breast cancer [9]. However the evidence confirmed that women can protect themselves against the alcohol-breast cancer link by consuming an adequate amount of folic acid with a daily multivitamin and by eating leafy green vegetables. Also, ageing has play a role as

a risk factor in induction of breast cancer, and the women are 10 times as likely to develop breast cancer in their thirties, 40 times as likely in their forties, 60 times as likely in their fifties and 90 times as likely after age 60 years old [5]. So breast cancer is higher in middle aged and elderly women than younger women [4, 6]. While Hickey et al, [10] referred that: young breast cancer incidence occur in the age group of 20-34, with a distinct concerns and issues compared with older women, including queries regarding fertility, contraception and pregnancy. The postmenopausal hormone therapy (PHT) or (hormone replacement therapy or HRT), has been used for many years to help relieve symptoms of menopause and to help prevent osteoporosis. The prescribed drugs as estrogen and progesterone (known as combined PHT), estrogen alone can increase the risk of cancer of the uterus, so progesterone is added to help prevent this, while for women with hysterectomy, estrogen alone can be prescribed (Estrogen replacement therapy (ERT) [11]. Also there are some genes considered as risk factors and the studies confirmed that: about 5% to 10% of breast cancers are thought to be linked to inherited changes (mutations) in certain genes. The most common gene changes are those of the BRCA1 and BRCA2 genes, which increase the chance of getting breast cancer up to 80% [12]. In addition to height and weight of the patient i.e. body mass index, in this realm Melinda et al, [13] stated that: the overweight (body mass index 25-29) and obese women (body mass index > 30) are more likely to develop breast cancer; that possibly because body fat alters a woman's estrogen metabolism.

The most common symptoms of breast cancer are: painless lump in the breast, dimpled or wrinkled skin over breast, discharge from the nipple, and inwards retraction of nipple. The

breast cancer has a great tendency to give metastatic foci to many parts of the body via different roots i.e. blood stream, lymphatic one, direct invasion, and cavities, thus it can form new tumors in other parts of the body. These secondary tumors commonly originated in the bones of the pelvis, spine, legs, ribs, and skull [14]. The metastases may also be found in the lungs, liver, Lymphatic system, and brain, while the relative signs could be as: lymph adenopathy at armpit (axilla) or in the neck, pain, pathological fracture, loss of function or sensation in limbs, spinal cord compression and hypercalcaemia [15], loss of energy and weight loss and lack of appetite, cough or shortness of breath [16], headaches, nausea, sign of a seizure, arm or a leg weakness or numbness, and even a change in personality [17].

The effort to diagnose and to evaluate breast cancer metastasis has been carried out by a set of modalities. In this realm CT can visualize the pathological evidence depending on the CT number (the number that characterize the radiation absorption at a given point of an object and are referred to as the attenuation value or CT density which measured in Hounsfield unit HU [18]. While MRI depends on proton resonance accumulation within the tumor bulk detection of cancer metastasis has been well established, as NM technology could detect the cancer during the stage of carcinoma in-situ [19] hence it could be capable to reveal the cancer metastasis especially when the applied radioisotope has chemical properties such like iodine and gallium [20], one of the studies carried out at NM section to reveal and assess the metastatic cases of breast cancer is bone scintigraphy.

A bone scan is a nuclear scanning test that identifies new areas of bone growth or breakdown. It can be done to evaluate damage to the bones, find metastasized cases to the bones, and monitor conditions that can affect the bones (including infection and trauma). The bone scan can often detect the pathological problem in days to months earlier than a regular X-ray test [21].

The intension of this study is to evaluate the diagnostic findings and studying of breast cancer metastatic behavior using bones scintigraphy with consideration to metastatic from both breasts.

2. Method:

The following study has been carried out on 210 of breast cancer patients who referred to radiation and isotopes center in Khartoum for bone scintigraphy. All patients biopsied and the histological types of cancer tissues have been confirmed.

The patients have been well hydrated and having one liter of fluid after radiopharmaceutical injection and of breast feeding patients should stopped breast feeding for 24 hours after injection of radiopharmaceuticals.

The radiopharmaceutical has been prepared from elution of Molybdenum-99-Technetium-99m Generator and obtaining of 5ml of sodium pertechnetate solution with maximum activity of 100 mCi which is added to the vial that contains Metheline-diphosphonate (MDP), the vial content well mixed and the PH of the prepared solution was at 6-7. The solution preparation has to be administered to patient within 3-4 hours from the preparation time. The Patient should be laid in supine position, a pillow could be placed under the patients knees for comfort if necessary.

From the reception hall of patients, the patient being call to hot lab for checking the name, age, weight and height up on which the dose being determine and injected intravenously (^{99m}Tc -MDP) using shielded syringe and butter fly for protection point of view, then the patient left to stay for 2 hrs at specially waiting room. During this period the patient allowed to have lot of water as well as voiding.

After the intravenous administration, the ^{99m}Tc -MDP complex

is taken up by soft tissues and accumulated in the kidneys then redistribution and reaching the maximum accumulations in the bones within 1 hours after administration.

Then image or scanning using Gamma camera (Model Nucline™ Spirit Dual Head SPECT, manufactures by Mediso Medical System) has been carried out as anterior\posterior and posterior\anterior views of axial skeleton and the a delay in imaging was so helpful in elderly patients with slower bone uptake, as well where an equivocal occur in anterior and posterior technique then, spot views is used (e.g. pelvic, lateral skull views) or where bladder activity obscures pelvic structures lateral or squat views may be obtained or a further post void image undertaken. If the patient is unable to empty the bladder masking the retained urinary activity with lead shielding will allow improved detail in the rest of the pelvis.

3. Results & Discussion

In Figure 5.1 which show the incidence percent of cancer distribution in women breast. The results showed that the left breast is so more susceptible to cancer than the right one, with a percentage of 50.7% greater than the right one which is 49.6%, this results is an agreement with the study done by Nosheen et al, [22] which indicate that the carcinoma of the breast affects the left breast with percentage of 66% slightly more than the right breast which has 31% and bilateral breast cancer 3%, while bilateral breast cancer has zero percentage. Which indicate that bilateral breast cancer incidence is very rare. This result is an agreement with the study carried out by Chaudary et al, [23].

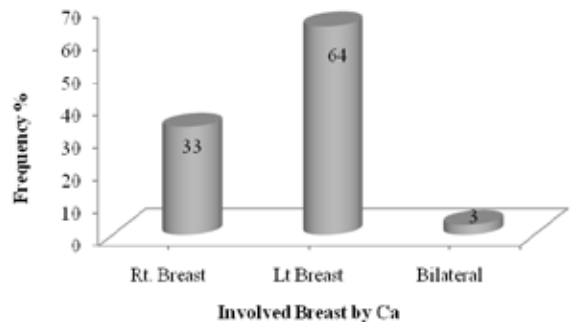


Figure 1 show the incidence percent of cancer distribution in women breast

Figure (2) shows the distribution of breast cancer among the women based on their ages. It reveals that the breast cancer could involve younger ladies in the ages of 20-30 years and increases with aging taking a high incidence around 38% among age group of 40-50 years old and 24% in women with age group of 50-60 years old, then decreases with aging, however this result is differ for the same case in developed country in which breast cancer is predominant among the age group of 20-43 years old as 12% [10]. This finding is in agreement with Anderson et al, [8]; they found that the breast cancer is so predominant among black women and commonly above the age of 40 years old. The decreasing incidence following the ageing could be ascribed to deceased of patients; one notation is that: all younger patients (20-30 years old) developed aggressive and most susceptible cancer types to hormones such as adenoid carcinoma.

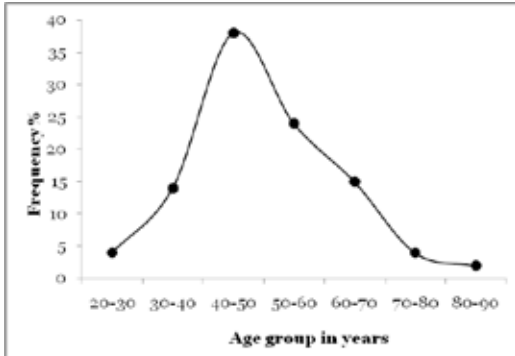


Figure 2 shows the percentage of distribution of cancer involvement based on women age

Figure 3 shows the common regions of skeletal system where the cancer cells could be seeded to establish secondary tumors from the right breast cancer. The carcinoma of the right breast is commonly gives some considerable metastasis to the Lumbar vertebrae (LV) with a percentage of 26, the dorsal vertebrae (DV) with a percentage of 14, the pelvic bone (Pelvic B) with a percentage of 10, the cervical vertebrae (CV) with a percentage of 8, the skull with a percentage of 7.3 and femur bone with percentage of 6.7. The common metastatic property from breast cancer is due to estrogen receptor positive subtypes [6]. This finding is an agreement with the literature review which stated that the breast cancer commonly gives metastasis to bone [24]; however there are some organs more susceptible to metastasis than other parts as our study shows that within the skeletal system there is most common region for secondary such as LV, DV and Pelvic bone. The researchers assume that the success of secondary growth is due to opportunity of the cell impaction, good climate and blood supply, in this view Marina and Ivan, [25] stated that growth of secondary tumor is mortgaged to factors of cell growth. The routes of skeletal metastasis are direct extension or invasion, lymphatic spread, hematogenous dissemination and intra-spinal spread. Skeletal metastases of breast cancer will mainly occur from lymphatic spread and hematogenous dissemination.

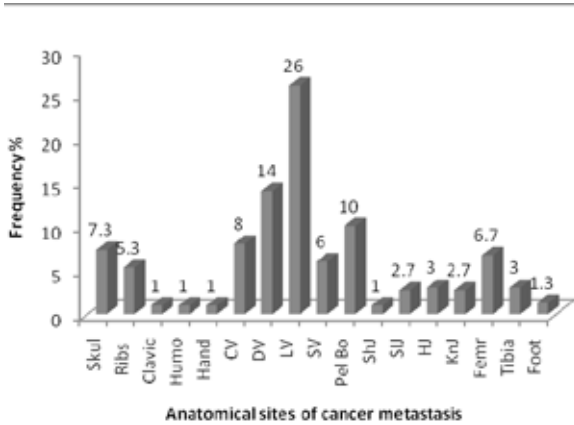


Figure 3 shows the anatomical sites of cancer metastasis among women for right breast

Figure 4 shows the common regions of cancer secondary among women for the left breast. The carcinoma of the left breast is commonly gives some considerable metastasis to the Lumbar vertebrae (LV) with a percentage of 21, the dorsal vertebrae (DV) with a percentage of 18, the pelvic bone (Pelvic B) with a percentage of 11, the ribs with percentage of 10, the cervical vertebrae (CV) with a percentage of 9 and the femur bone with a percentage of 8. This finding is agreed with Koizumi et al, [14] which concluded that bone is the most common sites of breast cancer secondary. How-

ever the results show that within the skeletal system there is most common region for secondary such as pelvic, upper leg bone (femur) and ribs but the spine is the most common site of bone metastasis (LV and DV). This finding is agreed with Gray et al, [26] in which they stated that the breast cancer is most commonly affects the spine, ribs, pelvis, and proximal long bones.

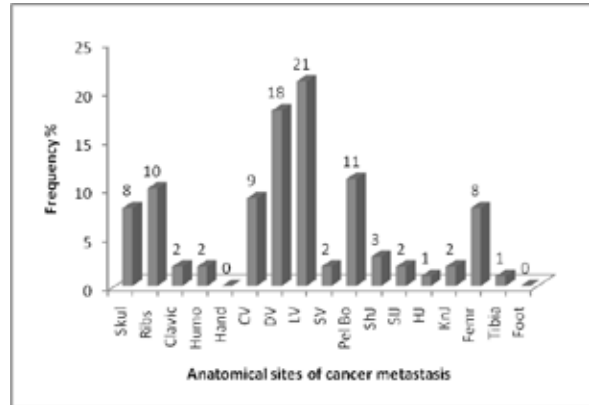


Figure 4 shows the anatomical sites of cancer metastasis among women for left breast

Figure 5 shows the comparative metastatic percent of cancer to skeletal system from right and left breast cancer, In general, the metastasis from both breasts to human system have shows same preferences; as to metastasize to certain organ higher than others i.e. the left and right breast cancer give metastasis to LV, DV and the Pelvic bone as most higher than others parts of skeletal system, they also show the same phase of metastasis to other skeletal system segments i.e. identical metastasis, this could be due to symmetrical net of lymphatic drainage as well as the blood supply arteries and the drainage veins. However the right breast usually appears to give higher frequency% relative to left one.

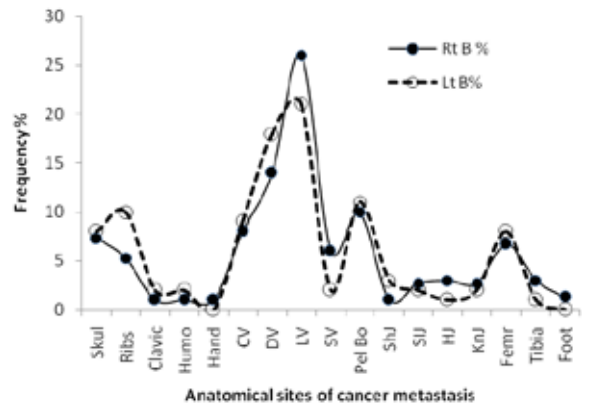


Figure 5 shows the comparative metastatic percent of cancer to skeletal system from right and left breast cancer

Figure 6 shows the common histological types of breast cancer percent in Sudan. It reveals that the common histological types of breast cancer are Invasive ductal carcinoma (IDC) that representing 38% from the total sample; which is in agreement with the study carried out by Gautam et al, [27, as well Li et al, [28] and Terfa et al, [29] who mentioned that: the most common subtype accounting for 70–80% was the IDC. The other less common types were Adenoid carcinoma 27%, Invasive lobular carcinoma (ILC) 17% in addition to minor percent of other types of histology, however carcinoma in situ taking 0% indicating the lack of breast screening program in Sudan or not publically known.

