



23-Gauge Transconjunctival Sutureless Vitrectomy for Primary Rhegmatogenous Retinal Detachment

KEYWORDS

Primary rhegmatogenous retinal detachment, 23-Gauge vitrectomy

Dr. Abhijeet Ramchandra Sable

Assistant Professor Ophthalmology Department, Smt. Kashibai Navale Medical College and General Hospital, S.No. 49/1, Narhe, Pune. 411041

Dr. Suhas Shripad Kulkarni

Professor Ophthalmology Department, Smt. Kashibai Navale Medical College and General Hospital, S.No. 49/1, Narhe, Pune. 411041

Dr. Divya Vakharia

Ophthalmology Department, Smt. Kashibai Navale Medical College and General Hospital, S.No. 49/1, Narhe, Pune. 411041

ABSTRACT

PURPOSE: To evaluate the anatomical & visual outcome following 23G vitrectomy for primary rhegmatogenous retinal detachment (RRD). **METHODS:** Retrospective, interventional, non-comparative case series of 27 eyes with RRD, underwent 23G-vitrectomy with silicon-oil or C3F8 tamponade. Anatomical stability and best corrected visual acuity (BCVA) noted at 6 months. **RESULTS:** Primary anatomical success rate was 92.59%. 2 eyes had redetachment which was successfully repaired. BCVA was good in 66.6% (> 6/24) and poor in 14.8% (<6/60) at 6 months follow up. 12 out of 27 eyes were phakics of which 6 developed gas cataracts, 3 warranting cataract removal with IOL implantation. **CONCLUSION:** 23G-transconjunctival-sutureless-vitrectomy for repair of primary RRD has shown to have a good anatomical success rate with no postoperative complications like hypotony or endophthalmitis.

Introduction

Rhegmatogenous retinal detachment (RRD) is a vision threatening condition. There are revolutions occurring in retinal detachment surgery. The development of scleral buckling techniques, laser, pneumatic retinopexy & intraocular gases have improved outcomes in repair of RRDs.^[10,13,14] Pars plana vitrectomy and pars plana vitrectomy combined with scleral buckling are considered to be an effective options in repair of RRDs.^[14] The advances in pars plana vitrectomy instrumentation, perfluorocarbon liquids, wide angle viewing systems, directional lasers and silicon oil have given a way to successfully treat more complex conditions.^[1] Self sealing sclerotomies with smaller gauge instruments have first been described by Chen et al in 1996 and Fuji et al.^[6,7] first described 25-gauge transconjunctival sutureless vitrectomy in 2002. Eckardt^[3] described a 23-gauge transconjunctival system in 2005, targeting some of the disadvantages of the 25-gauge system. The 23-gauge instruments are more rigid than those of 25-gauge system and behave more like traditional 20-gauge instruments, allowing more thorough peripheral vitrectomy and higher complex maneuvers.^[2,3] Lumen in 23-gauge system are wider and it improves illumination and fluid flow, reducing the net vitrectomy time. Also higher rigidity allows better control of instruments while performing vitrectomy. The 23-gauge system also utilizes oblique self sealing scleral tunnels, which reduce the potential complication of post operative wound leakage. Advantages of 23-gauge vitrectomy over traditional 20-gauge vitrectomy are (i) faster wound healing (ii) less conjunctival scarring (iii) improved patient comfort (iv) decreased inflammation (v) reduced post operative astigmatic change (vi) shortening of surgical opening and closing time.^[5]

The purpose of this study was to assess anatomical and visual outcomes of the 23-gauge vitrectomy system as Primary modality of treatment in RRD.

Materials and Methods

Medical records of 27 consecutive eyes of 26 patients (as

one patient was having bilateral disease) who underwent 23-gauge vitrectomy to repair primary RRD from January 2014 to December 2014 were retrospectively reviewed. Patients with Primary RRD of recent onset were included and eyes with advanced PVR, with history of pneumatic retinopexy, scleral buckling, follow up period of less than 6 months, dense vitreous hemorrhage were excluded. We collected data of variables as age, gender, laterality, duration between onset of symptoms and intervention and systemic illness. Regarding retinal detachment data collected was quadrant, clock hours involved, number and characteristics of break, association with lattice, involvement of macula and lens status. BCVA preoperatively and postoperatively at end of 6 months measured with Snellen's visual acuity chart was collected. Data regarding intraoperative tamponade (silicon-oil/C3F8 etc), use of endolaser or cryo was also collected. Also data regarding postoperative stability of retina during follow up at end 3 months and 6 months also collected. And in the end data regarding recurrence of retinal detachment, reasons for that and complications was collected. Variables were analyzed using students 't' test. 23-gauge instruments such as vitrectomy probe, microscissors, forceps, endolaser probe, endodiathermy probe, and flute needle were used for vitrectomy. A pneumatic vitreous cutter was used with a vitrectomy unit in all cases. A Non contact wide angle viewing system was used for visualization. Illumination was provided by xenon light, through 23-gauge light pipe. The vacuum was set at 400 mm Hg to 500 mm Hg with bottle height of 50 cm. The cut rate of the Microsurgical System of 1500-2500 cuts per minute was utilized in all cases.

Description of the procedure: After peribulbar anesthesia, eye was prepared and draped in the standard fashion. Cannulas were placed inferotemporally, superotemporally and superonasally 3 mm posterior to limbus for pseudophakic eyes & 3.5 mm posterior to limbus for phakic eye. The infusion line was connected to inferotemporal cannula. Wide angle fundus visualization was achieved using BIOM non contact wide field imaging system. Gen-

erally core vitrectomy was performed followed by meticulous peripheral vitreous base 3600 shaving with particular attention to relieving all traction at the sites of retinal breaks and along detached retina. Scleral depression was performed combined with either indirect ophthalmoscopy or viewing under BIOM system. Great care was taken to remove all vitreous from around the internal opening of infusion cannula during vitrectomy, allowing retrograde flow of ocular fluid out of the infusion cannula to equalize intraocular pressure during perfluron injection. Retinal break anterior to the equator were treated with cryotherapy before performing vitrectomy. In cases of highly bullous detachments or posteriorly located retinal breaks, the breaks were treated with endolaser after fluid air exchange. Subretinal fluid was drained through the break or a posterior retinotomy when necessary. Fluid air exchange by way of active suction using the ocutome was done to drain subretinal fluid. The decision to perform 3600 endolaser versus focal laser treatment of retinal breaks varied according to the peripheral retinal findings at the time of surgery. Non expansile mixtures of C3F8 or silicon oil were used as internal tamponade. All patients underwent postoperative positioning. Outcome measures studied were primary anatomical success rate, post operative BCVA at 6th month.

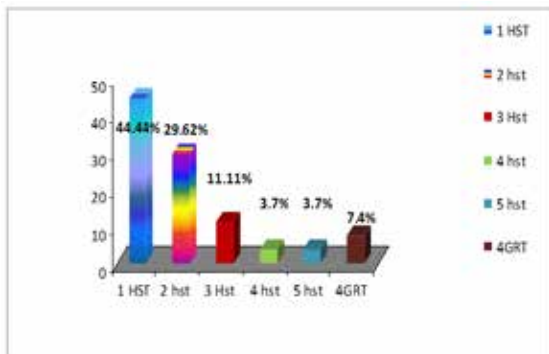
Results

Total 27 eyes of 26 patients were included in study as one patient was having bilateral disease. Out of these 16 were male and 11 female patients. All patients had a minimum post operative follow up of 6months (range6-13) months. The mean follow up±SD was 10.2±2.9 months. The mean age ±SD of patients was 48.59±10.8 (range,17-70). There were 11(40.75%) right eyes and 16(59.25%) left eyes. Three(11.11%) patients were one eyed. Three(11.11%) patients were hypertensive and two were diabetic.

Duration between onset of symptoms and surgery was <1week for 18(66.66%) patients and 1week to 3 week for 5(18.5%) patients and >3 weeks for 4(14.8%) patients. Out of these post operative visual outcome was good (i.e.>6/24)in 83.33% patients who presented within one week and 60% for patients who presented within 1 week to 3 weeks and zero %for more than 3 weeks. The characteristics of retinal breaks summarized in Graph-1, 12(44.44%) patients were having 1 Hst and 2(7.4%) of patients were having giant retinal tears. Remaining 13(48.14%) patients were having multiple breaks.

(Graph-1)

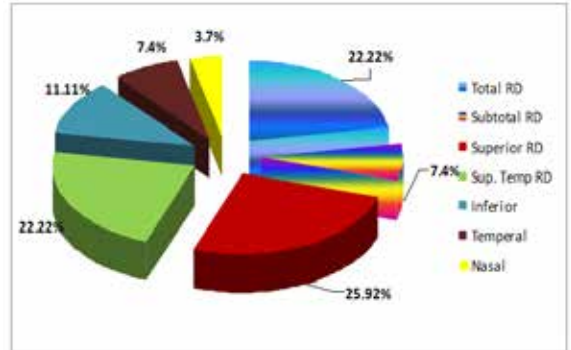
Graph-1: Characteristics of Retinal breaks



Total retinal detachment was seen in 6(22.22%) patients and subtotal in 2(7.4%) patients. Involvement of other quadrants is summarized in Graph – 2.

(Graph – 2)

Graph-2: Retinal detachment and its quadrant-wise distribution.



Lattice was associated in 10(37.03%) and macula was off in 19(70.37%) and on in 8(29.63%) patients before surgery. The mean preoperative snellen BCVA for macula-on was 6/9(range,6/6 to 6/12) and for macula-off was 1/60 (range,PL+ to 6/24). The mean post operative month 6 Snellen best corrected visual acuities were 6/6 (range6/6 to 6/12) and 6/36(range6/24 to FC1mt) for macula on and macula off respectively. Compared with preoperative BCVA, the improvement was significant for macula off eyes (p<0.001), but not for macula-on eyes (p=0.111). Silicon oil was used in 2 eyes and c3f8 in 25 patients as tamponade during surgery. Endolaser was done in 25 and cryo in 5 patients. Of the 12 phakic eyes during operation, none had lens touch by cannulas or instruments. None had dislodgement of 23-gauge cannulas during operation. No eyes required conversion to 20-gauge system or suturing of sclerotomy wounds.

After surgery eye was anatomically stable in 25(92.59%) of patients. Two eyes developed retinal detachment after surgery. The first redetachment occurred in pseudophakic patient inferiorly. Resurgery with scleral buckle was performed. Inferior tear was lasered and eye was stable until last visit. The other pseudophakic patient with total redetachment with proliferative vitreoretinopathy was treated with resurgery and eye was stable until last visit.

Post operative BCVA was good (<6/24) in 18(66.66%) and better (6/24 to 6/60) in 5(18.51%) and fair(<6/60) in 4(14.8%) of patients. Ten (37%) patients were pseudophakic and 5(18.5) patients were aphakic before surgery. Of remaining 12 patients, 4 were having cataract before surgery and in remaining 8 clear lenses 6 patients developed gas cataract out of which 3 required cataract surgery..

The mean postoperative day-1 IOP ±SD was 18.3±6.9 mm of Hg. Two eyes (7.4%) had hypotony. The IOP normalized spontaneously within 1 week with eye pad. Four eyes (14.8%) of patients had increase in IOP and required topical medications. One eye (3.7%) had epiretinal membrane and one (3.7%) had Proliferative vitreoretinopathy. There were no eyes with wound leakage, choroidal detachment or endophthalmitis.

Discussion

There has been trend towards primary vitrectomy in repair of RRD. Weichel et al [16] compared vitrectomy alone with combined (buckling with vitrectomy) in repair of RRD. This study demonstrated single surgery anatomical success rate of 92% for the vitrectomy alone group and 94% for combined treatment group. There were increased postoperative complications in the scleral

buckling/PPV group, including myopic shift with encircling element, diplopia, epiretinal membrane and cystoid macular edema. Vitrectomy without scleral buckling as a technique for repair of primary RRD was first reported by Escoffery *et al* in 1985.^[4] The modern Vitrectomy surgery which has classically been performed with 20-gauge instruments. However advancement in techniques and instrumentation lead to introduction of 25-gauge vitrectomy.^[6] But with 25-gauge vitrectomy, there are concerns of postoperative endophthalmitis and hypotony. In this system instruments are inserted through cannulated sclerotomies. When these trocars are removed and open hole in sclera is often clearly visualized and represents a direct opening from the vitreous to the outside of the eye, putting the eye at increased risk of endophthalmitis. Also opening in the sclera can be associated with wound leakage. Hypotony in the postoperative period can increase the risk of complications including retinal and vitreous incarceration and suprachoroidal hemorrhage. In addition, restricted intraoperative manipulations, due to increased flexibility of the instruments, have been an issue with 25-gauge vitrectomy. Eckardt^[3] first described 23-gauge vitrectomy targeting these limitations in consecutive series of 41 patients in 2005. Of the 41 patients, 8 had RRD. All the eyes were successfully reattached.

The single operation anatomical success rate of 92.59% reported in this series is comparable to that for primary repair of RRD by other means such as scleral buckling, pneumatic retinopexy, primary 20 gauge vitrectomy and combined scleral buckling/vitrectomy.^[8]

(Table-1)

Table-1: Anatomical outcomes after primary vitrectomy for RRD repair.

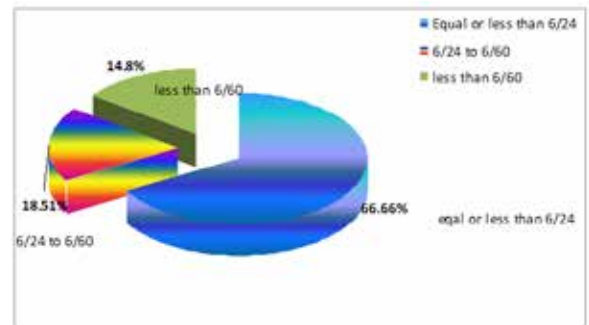
Year	References	Total no. of eyes	Anatomical Success rate
1985	Escoffery <i>et al</i>	29	79
1996	Heimann <i>et al</i>	53	64
1999	Campo <i>et al</i>	275	88
2000	Speicher <i>et al</i>	78	94
2004	Stangos <i>et al</i>	45	98
2005	Brazitikos <i>et al</i>	75	95
2006	Weichel <i>et al</i>	68	93

Our primary anatomical success rate of 92.59% compared favorably with those reported in literature for 20-gauge system 63-95%. Two eyes that had redetachment, both were pseudophakic. One was having inferior break leading to inferior redetachment. Resurgery was done using scleral buckle and it was successfully reattached. The other eye was having development of proliferative vitreoretinopathy in which resurgery (without buckle) was done with induction of silicon oil. In last visit both patients, retina was stable.

Overall we found a statistically significant improvement in vision with 23-gauge system. Post operative BCVA was good (<6/24) in 18(66.66%) and better (6/24 to 6/60) in 5(18.51%) and fair (<6/60) in 4(14.8%) of patients.

(Graph-3)

Graph-3: Post operative BCVA



Intraoperative and postoperative complications in our study were rare. There were two cases of hypotony but without evidence of choroidal detachment. In both cases wound appeared intact on slit lamp examination. Intraocular pressure in these cases normalized within one week with pressure patching. Four eyes of patients had increase in IOP and required topical medications. No cases of endophthalmitis were seen despite the theoretically increased risk for infections created by unsutured sclerotomies. We attribute this in part to superior wound construction with longer scleral tunnel the 25-gauge that is generated with 23-gauge system. Also the wound architecture that is generated by an angle incision is less likely to provide a track for bacteria to enter the eye. The self sealing nature of the 25-gauge system may be compromised after excessive intraocular manipulation. The angled nature of the 23-gauge sclerotomy site, however, is thought to allow better wound healing. In 23G the scleral thickness 3.5 mm posterior to limbus is 0.6mm, a 25° tunneled wound would be roughly 1.4 mm long, which is two times longer than a straight incision of 25G system.^[5]

23-gauge instruments have advantage of mirroring conventional 20-gauge instruments with similar rigidity and functionality, which allows more complex manipulation and peripheral vitreous dissection in retinal detachment repair. The cannula system allows trans-conjunctival insertion, possible shortening opening and closing time and easier passage of instruments. The cannulas appear to remain stable intraoperatively. There was no cannula dislodgment noted in the current series. In the literature on the efficacy and safety of the 23-gauge system in the repair of retinal detachment is limited. PVR rate (3.7%) observed postoperatively is similar to previously reported rates of PVR after either scleral buckling or 20-gauge vitrectomy, which ranged from 5- 17%.^[16] This shows that good fluid dynamics of current 23-gauge vitrectomy systems may be more efficient in removing pro-proliferative materials (retinal pigment epithelial cells, growth factors and cytokines).

Conclusion

23-gauge-vitrectomy is safe and effective with enhanced patient comfort and early rehabilitation. 23G-transconjunctival-sutureless-vitrectomy, for repair of primary RRD, has shown to have a good anatomical success rate with no postoperative complications like hypotony or endophthalmitis. As more instruments become available and surgeons gain greater experience with 23-gauge vitrectomy outcomes may still improve and indications for this technique are likely to expand.

REFERENCE

1. Brazitikos PD, D'Amico DJ, Tsinopoulos IT, Stangos NT, Primary vitrectomy with perfluoro-n-ctane use in the treatment of pseudophakic retinal detachment, *Retina* 1999;19:103-109 | 2. Chen E. 25Gauge transconjunctival sutureless vitrectomy, *Curr Opin Ophthalmol* 2007;18:188-193. | 3. Eckardt C. Transconjunctival sutureless vitrectomy, *Retina* 2005;25:208-211 | 4. Escoffery RF, OLK RJ, Grand MG, Boniuk I. Vitrectomy without scleral buckling for primary rhegmatogenous retinal detachment. *Am J Ophthalmol* 1985;99:275-281. | 5. Fine HF, Iranmanesh R, Iturralde D, Spaide RF. Outcomes of 77 consecutive cases of 23-gauge Transconjunctival vitrectomy surgery. *Ophthalmology* 2007;114;1197-1200 | 6. Fujii GY, de Juan E Jr, Humayun MS, et al. A new 25gauge instrument system for | Transconjunctival sutureless vitrectomy surgery, *Ophthalmology* 2002;109;1807-1820 | 7. Fujii GY, de Juan E Jr, Humayun MS, et al. Initial experience using transconjunctival sutureless vitrectomy System for vitreoretinal surgery. *Ophthalmology* 2002;109;1814-1820 | 8. Han DP, Mohsin NC, Guse CE, et al. Comparison of pneumatic retinopexy and scleral buckling in management of primary RRD. *Am J Ophthalmol* 1998;126:658-668 | 9. Lam DS, Yuen CY, Tam BS, Cheung BT, Sutureless vitrectomy surgery. *Ophthalmology* 2003;110:2428-2429. | 10. Machemer R. Reminiscences after 25 years of pars plana vitrectomy. *Am J Ophthalmol* 1995;119:505-510 | 11. Meyer CH, Rodrigues EB, Schmidt JC, Horle S, Kroll P. Sutureless vitrectomy surgery, *Ophthalmology* 2003;110:2427-2428 | 12. Schwartz SG, Flynn HW. Primary retinal detachment: scleral buckle or pars plana vitrectomy, *Curr Opin Ophthalmol* 2006;17:245-250. | 13. Schepens CL, Okamura LD, Brockhurst LJ. The scleral buckling procedures, Surgical techniques and management. *Arch Ophthalmol* 1957;58:797-811 | 14. Schwartz SG, Kuhl DP, McPherson AR, et al. Twenty year follow up for scleral buckling. *Arch Ophthalmol* 2002;120:325-329 | 15. Sharma YR, Karunanithi S, Aza RV, et al. Functional and anatomic outcome of scleral buckling versus primary vitrectomy in pseudophakic retinal detachment. *Acta Ophthalmol Scand* 2005;83:293-297 | 16. Weichel ED, Martidis A, Fineman MS, et al. Pars plana vitrectomy versus combined pars plana vitrectomy – scleral buckle for primary repair of pseudophakic retinal detachment *Ophthalmology* 2006;113:2033-2040