



## A Comparative Study on the Treatment of Unstable Intertrochantric Fractures of Femur Using Pfn and Pfna

### KEYWORDS

Unstable Intertrochantric femoral fractures , proximal Femoral Nail(PFN), Proximal Femoral Nail Antirotation(PFNA) , Innovative single helical screw, Screw cutout,

**Dr.Mohan.N.S**

Asst.Prof.Orthopaedics Sanjay Gandhi Institute of Trauma & Orthopaedics  
byrasandra,jayanagar east bangalore karnataka -560011

**ABSTRACT** Intertrochantric femoral fractures are common among older age group and are associated with substantial morbidity and mortality. A wide variety of treatment modalities are available for the management and many authors have reported that intramedullary devices such as PFN are biomechanically stronger and rigid compared to extramedullary devices. PFN also showed more number of post operative complications like implant failures, screw cutout in case of unstable intertrochantric fractures. To improve in 2003 AO/ASIF introduced PFNA (Antirotation system). This study was conducted to understand and analyze the advantages of PFNA over PFN in the management of unstable intertrochantric fractures at Sanjay Gandhi Institute of Trauma and Orthopaedics Bangalore between 2011 to 2013. In all the cases pre operative and post operative clinical evaluation, radiological evaluation, assessment regarding operative time, blood loss, fluoroscopy time, time for fracture union, post operative complications are also noted. Clinical results were evaluated using Harris Hip score. The results showed PFNA has better rotation stability with single screw and better functional outcome in treating unstable intertrochantric fractures when compared to PFN.

### Introduction:

Intertrochantric fractures are the most frequently operated fractures and have the highest mortality and morbidity rates<sup>1</sup>. More than 20000 fractures occur every year, and the incidence is expected to double by year 2020<sup>2</sup>. A wide modalities of treatment are available for the management of these fractures, in olden days these fractures were treated conservatively with lot of complications, to decrease the complication rate internal fixation was done<sup>3</sup>. Unstable intertrochantric fractures are difficult to treat<sup>3</sup>. Intramedullary devices such as PFN are biomechanically stronger and more rigid compared to extramedullary devices such as DHS<sup>4</sup>. PFN also has showed more number of post operative complications, like implant failures, screws cut out, in case of unstable intertrochantric fractures<sup>5</sup>. To improve in 2003 AO/ASIF introduced PFNA (Antirotation system). PFNA claimed better rotation, and angular stability with single screw and better functional outcome in treating unstable intertrochantric fractures when compared to PFN<sup>6</sup>.

In the present study an effort was made to understand and analyze the advantages of PFNA over PFN in the management of unstable intertrochantric fractures.

### Materials & Methods:

This study was conducted in a tertiary care center Sanjay Gandhi Institute of Trauma and Orthopaedics Bangalore 2011 to 2013, A total of 88 cases (54 males & 34 Females) were included in the study group with age group between 60 and 80 years. Patients were informed about the study in all respect and informed consent was taken from each patient. Patients with acute unilateral, non pathological, unstable fractures (Evan's classification) without any co-morbidity were included in the study. Fractures with identical geometric pattern were divided into two groups each having 44. One was treated with PFNA and other was treated with regular PFN. All fractures were fixed by closed reduction and internal fixation on fracture table under fluoroscopic control. A standard

post operative protocol was maintained which included partial weight bearing for 2 months, and assisted weight bearing for another 1 month with calcium and vitamin D supplementation. Post operative follow up done at 4-6 week intervals for a period up to 24 months. In all cases antithrombotic prophylaxis was administered using low molecular weight heparin for 3-5 days and antibiotic prophylaxis was administered in peri-operative period. Radiograph of the affected hip were obtained in AP and medial and lateral planes to assess the post operative fracture reduction. In all the cases assessment also done regarding operative time, blood loss, fluoroscopy time, time for fracture union, post operative complications, limb length discrepancy, pre and post surgical ambulatory status. The quality of fracture reduction was graded as good and acceptable, (5-10 deg varus / valgus and anti-version/retroversion maintaining neck shaft angle) poor (> 10 deg varus / valgus and anti-version /retroversion not maintaining the neck shaft angle) other parameters like Singh index, Tip apex distance, Screw placement were also noted. The position of PFN Antirotation was graded as good if the blade was placed into the lower half of the neck AP view, and centrally on a lateral view and if nail does not protrude outside the greater trochanter. The clinical results were assessed using Harris hip score, Harris hip score were categorized as excellent (91-100 points) good (81-90 points) fair (71-80 points) and poor (<70 points). Radiographs of the affected hip were obtained in the AP and lateral views at each follow up visit. And any change in the position of the implant, and the extent fracture union were noted. Fracture were judged to be healed radiographically if bridging callus was evident on 3-4 cortices as noted on two views.

### Results:

Out of 88 total cases 80 patients (50 males and 30 females) were available for evaluation and 8 of them lost follow up. The mean operative time in PFNA was 50 minutes, whereas 80 minutes in PFN, mean blood loss

in case of PFNA is 110ml , Where as in PFN is 150ml , The mean fluoroscopy time in PFNA is 4 min , In PFN it is 8min, The time of union in PFNA group is 12weeks ,In PFN group it is 14 weeks .

Post operative complication in PFNA group 2 cases of superficial infection was noted, which were resolved with injectable antibiotics. In case of PFN group 2 cases of superficial infection and 2cases of deep infection were noted , Which required wound debridement, One case screw cut out Z effect was noted , One case of broken nail at distal locking site , and One case of broken distal locking screw was noted . Limb length discrepancy was noted in two cases of PFNA , Where as 6 cases were noted in PFN , In post operative ambulation 30(80%) cases gained pre injury ambulatory status within 2weeks and remaining 10 cases (20%) gained in another 8weeks, Where as in PFN 20cases group(50%) gained pre injury ambulatory status within 2 weeks, and another 20cases(50%) gained in another 8 weeks, 4 cases had abductor lurch.

Regarding functional outcome Harris hip score was used , In PFNA group 36 cases (90%) showed excellent results 4 cases(10%) showed good results, Where as in PFN group 30cases (75%) showed excellent results, 8 cases (20%) showed good results and 2 cases (5%) showed poor results.

**Discussion:**

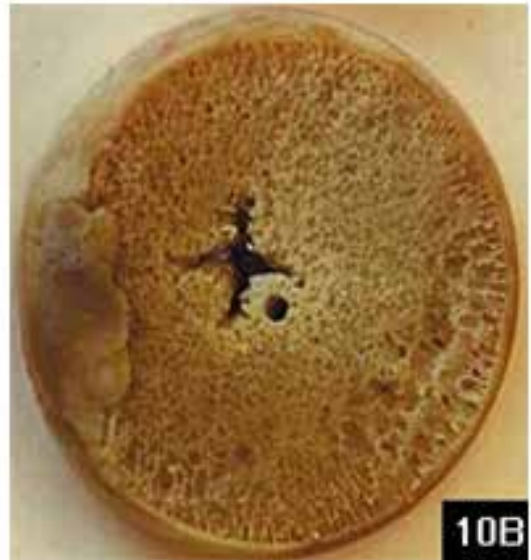
The aim of the study was to compare the functional outcome of the patient having unstable intertrochantric fractures treated by two different methods of intramedullary fixation PFNA and PFN . Intramedullary nails act as internal splints and helps in indirect healing these devices causes minimal trauma to the vascular supply of the bone <sup>7</sup>. To improve the rotational and angular stability using a single element the AO/ASIF group came out with PFNA in 2003 <sup>6</sup> . Study showed less operative time, less blood loss, less fluoroscopy time, less complication rate, good post operative ambulatory status, better Harris hip score, with PFNA <sup>6</sup>.

The innovative helical blade design provides better compaction of cancellous bone , there will be increased contact area between implant and the femoral head, better hold on both compact bone and cancellous bone<sup>8</sup>. PFNA improves the fixation stability by decreasing reaming of the bone stock which will be done in PFN <sup>9</sup>. There is no need of another de-rotation screw and it has been biomechanically proven to have better purchase in osteoporotic bones <sup>10</sup>.

Biomechanically PFNA has greater resistance to cut out better rotational stability achieved with one single element large surface and increased core diameter guarantee the maximum compaction and optimal hold in bone <sup>11</sup>. It has showed improved resistance to varus collapse resistance to femoral head rotation , longer fatigue life <sup>12</sup>. The 11.0 mm helical blade reduces the amount bone removed in the neck <sup>9</sup>. The tip of the PFNA is flexible which reduces the stress on the bone at the tip and therefore, there will be less implant failure (distal nail breakage and distal locking screw breakage)<sup>13</sup>.

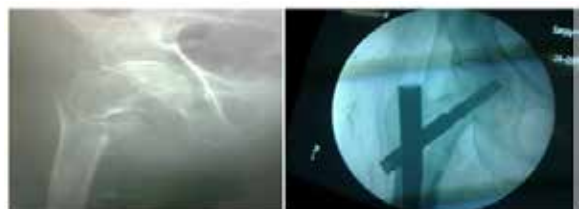
In PFN 2 screws are used for the neck the larger screw is the lag screw to take the load. Smaller screw for rotation stability if the length of smaller screw increases ver-

tical force increases and induces the cutout causing effect (Z-effect) , or reverse Z effect <sup>14</sup>. Cut out rates of PFN screws is between 0.6-0.8%<sup>15</sup>.



**Helical blade: impaction causes bone compaction**

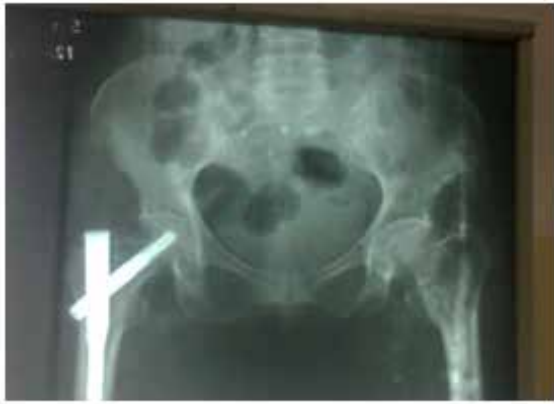**Retards rotation & prevents varus collapse**



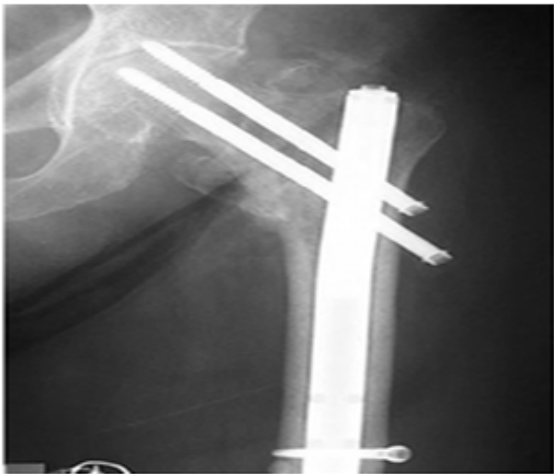
Preoperative

postoperative

Follow up at 3 month

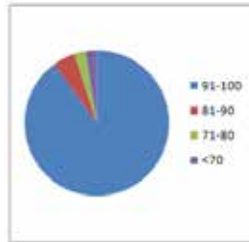


Z effect

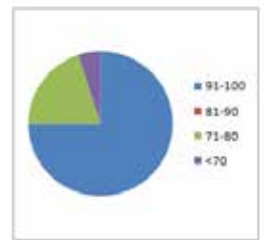


Number	40	40
Mean operative time	50 min	80min
Mean blood loss	110ml	150ml
Mean fluoroscopy time	4min	8min
Time of union	12weeks	14weeks
Post operative complications	2 superficial infection	2 sup & 2 deep infection
Limb length shortening	2	6
Post operative ambulation	90 %gained pre injury ambulatory status	75% gained the pre injury ambulatory status

Harris hip score



PFNA



PFN

**Conclusion:**

In PFNA there is no need of another derotation screw , Innovative helical blade design provides better hold on both compact and cancellous bone , Increases contact area between and femoral head improve stability and less incidence of screw cutout in case of unstable intertrochantric fractures .

Our study showed PFNA is better implant then PFN in treating unstable intertrochantric fractures.

**RESULTS**

	PFNA	PFN
--	------	-----

**REFERENCE**

Konal KJ, Cantu R V , Intertrochantric fractures in Bucloz RN , Heckman Courtbrown LM , Torenetta IIP, Mcqueen MM, (7th edi) Rockwood &Green fractures in adults(Wolters Kluwer; Lippincott willams&Wilkins 2010 ) 1570-1597 | Hagrod GA ,Choudhary MT ,Hussain A, Dynamic hip Screw in proximal femur, Indian Journal of Orthopedics 28(2), 1994 , 3-6 | Haidukewych GJ, Ibroul TA, Berry DJ, Reverse obliquity fracturesof intertrochantric region of the femur , J Bone Joint surg AM . 2001; 83(5):643-650 | BaumgartnerMR, Curtin SL, LindskogDM, Intramedullary versus extramedullary fixation for the treatment of intertrochantric hip fractures clin Orthop Relat Ref . 1998(348):87-94 | Simmermacher RKJ, Bosch AM, Van der Werken C. The AO/ASIF- Proximal femoral nail: a new device for the treatment of unstable proximal femoral fractures. Injury 1999;30(5):327-32. | Takigami J,Matsumoto R, Ohara A, et al. Treatement of trochantric fractures with the proximal femoral Nail Antirotation(PFNA) system report of early results. Bull NYU Hosp Jt 2008; 66(4):276-279 | FritzT,Hiersemannk, Krieglstein C,Fried IW, Prospective randomized comparison of gliding Nail and Gamma Nail in the therapy of trochantric fractures . Arch orthop Trauma Surg 1999, 119(1-2);1-6. | Merrddy P, Kamath S, Ramakrishanan M, Malik H, Donnachie N, The AO/ASIF Proximal Femoral Nail Antirotation(PFNA):A new design for the treatment of unstable intertrochantric fractures Injury.2009; 40(4):428-432 | Brunner A, Jockel JA,Barbst R, The Proximal Femoral Nail Antirotation Proximal Femoral Nail in the treatment of unstable intertrochantric fractures-3 Cases of post operative perforation of helical blade into the hip joint. J ortho Trauma 2008; (10):731-36 | Vidyadhara S, Rao SK, one and two femoral neck screws with Intramedullary Nails for unstable trochantric fractures of femur in the elderly –Randomised clinical trial. Injury2007;38(7): 806-814. | M.B Sommers, M Bottlang, C Roth, H. Hall, J .C . Krieg; A laboratory model to evaluate cutout resistance of Implants for peritrochantric fracture fixation; Journal of orthopedic Trauma July 2004, vol 18(6); 361-368 | Hwang JH, Oh JK, Han SH, Shon WY , Oh CW, Mismatch between PFNA& medullary canal causing difficulty in Nailing of the peritrochanteric fractures Arch orthop Trauma surg . 2008; 128(12); 1443-1446 | Simmermacher RK,Ljungquist J,Baish et al. The new Proximal Femoral Nail Antirotation in daily practice ; results of a multicentric clinical study Injury 2008; 39(8); 932-939. | Adams Cl, Robinson CM, Court Brown CM, McQueen MM, Prospective randomized study controlled trial of an Intramedullary Nail versus dynamic screw or plate for intertrochantric fractures of femur J Ortho Trauma. 2001 ;15(6):394-400. | Baumgaertner MR, Curtin SL, Lindskog DM, Keggi J. The value of the tip-apex distance in predicting failure of fixation of peritrochanteric fractures of the hip. J Bone Jt Surg Am 1995;77:1058-64. |