



Diagnostic Peritoneal Lavage by Blunt Tip Trocar(5mm) Channeled Drain Technique-A Case Series

KEYWORDS

Dr.Kamlesh A Bhadreshwara

(MS,general surgery),Dept. of Surgery, Associate Professor, Smt. NHL municipal medical college, Ahmedabad

Dr.Alpesh Amin

(MS,general surgery),Dept. of surgery, Assistant Professor, BJMC, Ahmedabad

ABSTRACT Diagnostic peritoneal lavage (DPL) is an invasive, rapid and highly accurate test for evaluating intraperitoneal hemorrhage or a ruptured hollow viscus. DPL plays a role in both blunt and penetrating abdominal trauma. In this article we are introducing a simple technique that can even speed up the DPL procedure by using blunt tip 5 mm trocar - 15 French Blake silicon drain in a semi-open technique. Method: Semi-open DPL was performed in 11 patients with blunt abdominal trauma (BAT). A blunt tip 5 mm trocar was introduced into the peritoneal cavity blindly and 15 Fr size Blake channeled drain was advanced into the peritoneal cavity and the peritoneal effluent was withdrawn and analyzed. Results: A total of 11 blunt abdominal trauma patients were subjected to 5mm Blunt Tip Trocar-Channeled Drain DPL technique. The DPL was grossly positive in 9 patients (81.8%) and subsequently were managed surgically and in two patients (18.2%) it was grossly and microscopically negative, subsequently both were managed conservatively. There was no complications attributed to this new DPL technique. Conclusion: The preliminary data suggest that blunt tip 5mm trocar - Channeled Drain technique delivers a faster reliable way of performing DPL in trauma patients. However, large number of cases is needed to justify its Routine use in trauma.

1. Introduction

Since being first fully reported in 1926, diagnostic peritoneal lavage (DPL) has been accepted as an essential diagnostic procedure in the "haemodynamically abnormal patient with multiple blunt injuries and the manual for Advanced Trauma and life Support for Doctors (ATLS) still recommends DPL in the haemodynamically abnormal patient with multiple blunt injuries [1]. A recent article has again advocated its use [2]. To date, three techniques of peritoneal lavage have been summarized by Manganaro. These include the closed, semi-closed, and open technique [3]. Despite the fact that all three at one time have enjoyed some form of popularity. The open technique is currently preferred. Greater accuracy, less morbidity, and decreased incidence of complications have been cited as its distinct advantages [4]. In contrast, the closed technique has been associated with a 2% to 5% incidence of false-positive results, in addition to major bowel and vascular injury. Despite previously published reports of multiple complications with the closed technique, Krausz et al. reported a 96% accuracy rate with minimal complications using a percutaneous catheter technique, thus adding to the growing body of evidence supporting either Method. In this study we are introducing a simple faster technique in performing DPL.

2. Patients and Methods

The study was undertaken in the accident and trauma unit at our hospital, Ahmedabad. The study population included 11 male patients affected by blunt abdominal trauma due to motor vehicle accident. First, the patient is positioned flat in the supine position. A Foley catheter and a nasogastric tube are inserted to decompress the bladder and the stomach.

After scrubbing and draping of abdomen, a local anesthetic was injected supra umbilical in the dermal and subcutaneous layers. Two towel clips were applied at the superior edge of the umbilicus. A small longitudinal or transverse incision was made supra-umbilical. The towel clips were used to lift up strongly the abdominal wall in order to lift the abdomen wall away from bowel (Figure 1 a,b). A 5 mm

blunt tip trocar (Kii Access-Applied Medical) is introduced slowly using screwing clockwise - anticlockwise technique with a fine tilt toward the pelvis till the tip passes into the peritoneal cavity (Figure 1a,b).

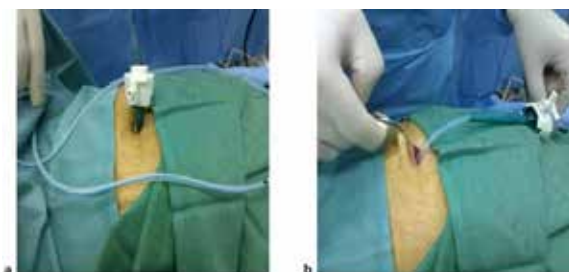


Figure 1.a, b: A 5 mm blunt tip trocar is introduced slowly using screwing clockwise - anticlockwise technique with a fine tilt toward the pelvis till the tip passes into the peritoneal cavity

The obturator of trocar is taken out and then a 15Fr channeled Blake drain is advanced into the pelvic cavity. Using 30 ml syringe, a negative pressure is applied. If no effluent is coming out then 1 liter normal saline is introduced and withdrawn back using the syringe. The trocar was then taken out and only skin was closed

3.result

Over a period of three years, eleven male patients were subjected to the 5mm blunt tip trocar-Channeled drain DPL technique, with a mean age of 23.3 ± 7.3 (15-52) years. In 9 patient (81.8%) the DPL was grossly positive for blood, subsequently a therapeutic laparotomy was

performed in all these patients. Four (81.8%) of these patient were found to have liver laceration of grade 3, managed with packing and a second look laparotomy with removal of packs. Two patients (22.2%) was found to have splenic laceration of grade 3 and were all managed by splenectomy. In one patient (11.1%) the reason for bleed-

ing was a mesenteric tear and in another patient (11.1%) he was found to have right diaphragmatic tear with lung laceration leaking blood into the peritoneal cavity. In two patients (18.1%) the DPL was negative grossly and microscopically. In this DPL negative group of patients, one patient was having multiple pelvic fractures and the other patient was having bilateral femur fractures.

4. Discussion

Initially the of DPL been made under the name of abdominal puncture to diagnose acute abdominal diseases. In 1906, Solomon 1 devised an ingenious but rather complicated apparatus that he recommended for abdominal puncture. It consists of a needle within a trocar,

through which a ureteral catheter is passed into the peritoneal cavity. Solomon described a few cases in which the procedure appeared to be of value [6]. Diagnostic peritoneal lavage (DPL) has been used as a diagnostic procedure in patients with blunt abdominal trauma for

almost a century. Its accuracy and reliability are high. However DPL is an invasive procedure and carries a small but significant risk of iatrogenic intra-abdominal injury [7].

DPL is performed in one of three different ways. The open technique utilizes a vertical infra-umbilical incision and direct visualization of peritoneal entry with a scalpel. The closed technique relies on percutaneous needle access to the peritoneal cavity, followed by the insertion of a

catheter using Seldinger technique. The semi-open technique follows the same principles of the open technique except that the midline fascia is penetrated with a needle and the catheter is advanced using the Seldinger technique [8,9].

There is no difference in overall outcomes or rates of injury to visceral contents between the techniques. The closed method is faster, but often has more technical complications such as wire placement and inadequate fluid return [10].

Dingfelder was the first to publish in 1978 direct entry into the abdomen with a trocar. There are several retrospective studies published on the safety of this method of entry. Although a few studies were prospective, only three were randomized [11]. The methodology of the three RCTs is sound, and two reported on insertion time as well as morbidity and mortality. Nezhat et al. excluded past abdominal surgery but took into account BMI; they showed fewer minor complications with direct trocar entry than with the Veress needle [12,13]. Such concerns would

be also applicable with our technique especially previous infra - umbilical surgery.




Figure 2. Tip of the drain with its flutes

No major complications occurred with the 5mm blunt tip trocar - Channeled drain technique. The insertion is even faster since there is no need to place a wire and the blunt tip trocar is quite blunt that unlikely to cause bleeding or bowel injury if performed safely and with the appropriate way. With this technique there will be no need to close the fascia if the DPL is negative which is another advantage. The use of silicon 15 fr round Blake drain enhanced the withdrawal of the peritoneal contents easily due to the presence of flutes rather than holes and this is also true for the fluid return after installing normal saline in the peritoneal cavity. This probably due to the long silicon tube and long flutes along the side of the drain that is so hard to be occluded

A positive DPL in an adult classically requires one of the following results: 10 ml gross blood on initial aspiration, > 500/mm³ white blood cells (WBC), > 100,000/mm³ red blood cells (RBC), or the presence of enteric/vegetable matter [8]. These thresholds were originally developed in the setting of blunt trauma and have since been applied to penetrating trauma. In the presence of gross blood or enteric matter, immediate laparotomy is performed.

Without those findings, accurate microscopic cell counts should be obtained, which in our institution takes approximately 30 minutes to receive from the laboratory. During this time period, if the patient's clinical status deteriorates or signs of peritonitis develop, laparotomy is

not delayed.

5. Conclusion

The 5 mm blunt tip trocar - channeled drain DPL technique may represent an advantage over traditional methods as it allows a faster peritoneal entry, and easier withdrawal of intra-peritoneal content. But these advantages has not been studies in a randomized method

REFERENCE

- [1] Advanced Trauma Life Support Student Course Manual for Doctors: American College of Surgeons Committee on Trauma 1997
- [2] Parks RW, Chrysos E, Diamond T. Management of liver trauma. Br J Surg. 1999; 86: 1121-35
- [3] Manganaro AJ, Pachter HL, Spencer FC, et al. Experiences with routine, open abdominal paracentesis. SurgGynecolObstet 1978; 146: 795.
- [4] Soderstrom CA, DuPriest RW Jr, Cowley RA. Pitfalls of peritoneal lavage in blunt abdominal trauma. SurgGynecolObstet 1980; 151: 513-518.
- [5] Krausz MM, Manny J, Usumomiya T, et al. Peritoneal lavage in blunt abdominal trauma. SurgGynecolObstet 1981; 152: 327-330.
- [6] Neuhoef H, Cohen I. Diagnostic Peritoneal Lavage. Ann Surg. 1926; 83: 454
- [7] Cue JI, Miller FB, Cryer HM, Malangoni MA, Richardson JD: A prospective, randomized comparison between open and closed peritoneal lavage techniques. J Trauma 1990, 30 (7):880-883.
- [8] American College of Surgeons: Abdominal trauma. In Advanced Life Support Program for Doctors 8th edition. Chicago, IL; 2008: 111-129.
- [9] Schultz DJ, Weigelt JA: Diagnostic Peritoneal Lavage. In Operative Techniques in General Surgery Volume 5. Issue 3 Edited by: VanHeerden JA, Farley DR. Philadelphia, PA: WB Saunders; 2003: 139-144.
- [10] Lopez-Viego MA, Mickel TJ, Weigelt JA: Open versus closed diagnostic peritoneal lavage in the evaluation of abdominal trauma. Am J Surg 1990, 160: 594-597.
- [11]