



Spinal intradural epidermoid cyst : A case report and literature review

KEYWORDS

Epidermoid, intradural , conus, spinal cord

Sandeep P Inchanalkar

Department of Surgery, D.Y.Patil Hospital, Kolhapur, Maharashtra

Amit Garud

Department of Surgery, D.Y.Patil Hospital, Kolhapur, Maharashtra, India

Chamandeep Singh Kamboj

Department of put surgery, D.Y.Patil Hospital, Kolhapur, Maharashtra, India

ABSTRACT Epidermoid cysts are rare benign neoplasms within the neuraxis, which are commonly located in the intracranial region and account for less than 1% of all intraspinal tumors^{1,2}. Epidermoid cysts can be congenital or acquired. Congenital epidermoid cysts are frequently found in association with spinal dysraphisms such as syringomyelia, dermal sinus and spina bifida, while the most common etiology for an acquired cyst is repeated lumbar puncture^{2,5}. Here, we report a 18-year-old female patient with dorsolumbar epidermoid cyst. Magnetic resonance imaging revealed a well –defined intradural extramedullary lesion at D12-L1 vertebral levels, which was hypointense on T1W1 and heterogeneously hyperintense on T2W2 with conus compression. Surprisingly patient had no neurological deficits, surgery was performed to decompress the spinal cord. Histopathology examination of the removed lesion proved it to be epidermoid . In this report , we also discuss the principles of diagnosis and treatment of conus epidermoid in combination with literature review.

Introduction

Epidermoid cysts are rare benign neoplasms within the neuraxis, which are commonly located in the intracranial region and account for less than 1% of all intraspinal tumors^{1,2}. Epidermoid cysts can be congenital or acquired. Congenital epidermoid cysts are frequently found in association with spinal dysraphisms such as syringomyelia, dermal sinus and spina bifida, while the most common etiology for an acquired cyst is repeated lumbar puncture^{2,4}. Although epidermoid cyst can be extradural, intradural, extramedullary or intramedullary in the spine, the tumors are often intradural extramedullary in the lumbosacral region⁵. The symptoms of an epidermoid cyst are usually nonspecific. Neurological symptoms such as progressive paraparesis, motor sensory complaints and sphincter trouble causes great distress^{2,3,4,6,7}. Patients with epidermoid cyst usually suffer for a long time with symptoms, for an average time of 6 years, due to their slow growing nature^{2,4}.

Because it is an indolent benign tumor, an epidermoid cyst can be cured by a complete excision. However complete resection is difficult to achieve because its capsule adheres to the spinal cord or nerve roots, so subtotal resection is usually the more common objective⁹.

Case presentation :

A 18 Yr old girl presented with backache of 4-5 years duration. It was a dull aching, nonradiating pain. No history of weakness in legs or bowel and bladder disturbance. There was no history of trauma or repeated lumbar punctures. On examination, there was no evidence of spinal dysraphism or any motor-sensory deficit. On MRI, there was intradural extramedullary lesion at D12- L1 region, it was hypointense on T1W1, heterogeneously hyperintense on T2W2 and showing uniform enhancement (figure 1,2). The diagnosis of intradural mass lesion was made. The patient underwent laminectomy from T11 to L2 and the intradural extramedullary lesion seen, it was under the root that was stretched by it. Using microscope it was gently dissected from the root and cord. Tumour was decompressed initially and later the cyst wall was removed entirely. A wash given with normal saline and dura closed in water-

tight manner. During surgery the blood loss was 400 to 500 ml. Patient recovered well, with no postoperative deficits. Postoperative MRI showed total excision (fig 3). Microscopic examination showed, cyst walls were lined with compressed stratified squamous epithelium with abundant keratin material, which was consistent with epidermoid cyst (fig 4).

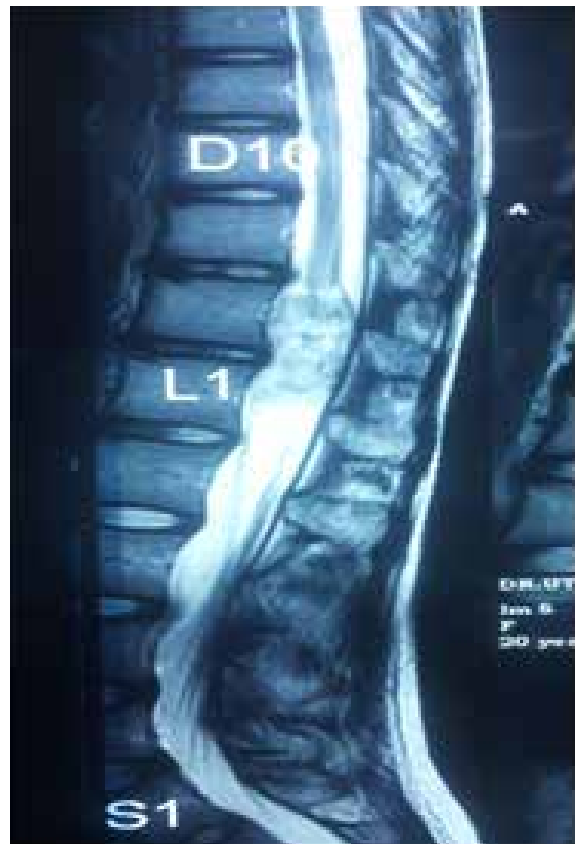

Fig 1; T2W Sag mri

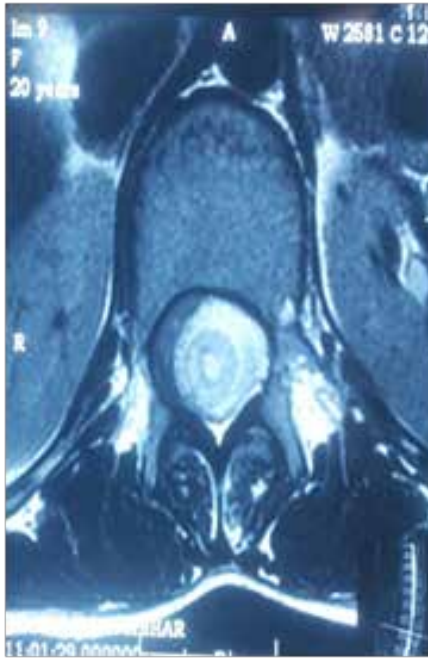


Fig 2; T2W Axial mri

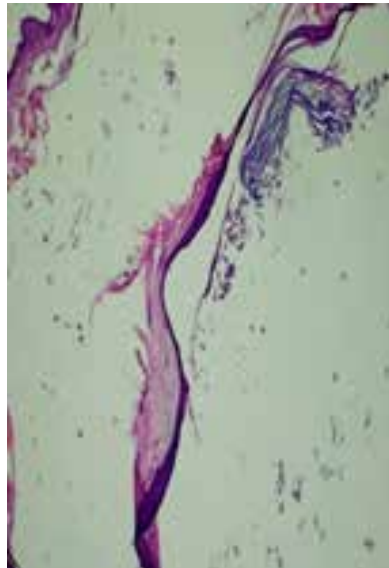


Fig 4; Histopathology

Discussion :

Due to rarity of epidermoid cysts, there are no descriptions of the clinical features in the literature. The symptoms and signs of an intraspinal epidermoid cysts are directly associated with the size and site of the lesion, non specific symptoms and signs such as numbness , weakness, spasticity, paraparesis of lower extremities and defecation disorders pose challenges in the preoperative diagnosis. Ependymomas, metastasis and astrocytomas can be ruled out, but distinguishing an epidermoid cyst from a dermoid cyst relies on a pathological examination. MRI is an effective tool for the diagnosis of an intraspinal epidermoid cyst. Histologically, they are composed of lined stratified squamous epithelium supported by an outer layer of collagenous tissue. Progressive desquamation of keratin from the epithelial lining produces cholesterol crystals . This may produce vigorous inflammation if ruptured^{2,9,10,11}. The dermoid cysts in the spine with similar pathogenesis and manifestation will often have satellite lesions^{2,8}. Given their indolent benign nature, asymptomatic epidermoid cysts should be managed conservatively. Surgical excision is essential for lesions with symptomatic progression and where imaging shows that neural elements are compressed^{8,9,11,12}. Although complete excision is the goal, sometimes it may be difficult due to adherence of the wall to neural elements. Local recurrence is uncommon, metastatic lesions are not reported, malignant transformation are not found in the spine^{13,14}. Symptomatic relapse cases should be re-treated by surgery, but it is difficult due to formation of scar tissue¹⁴.

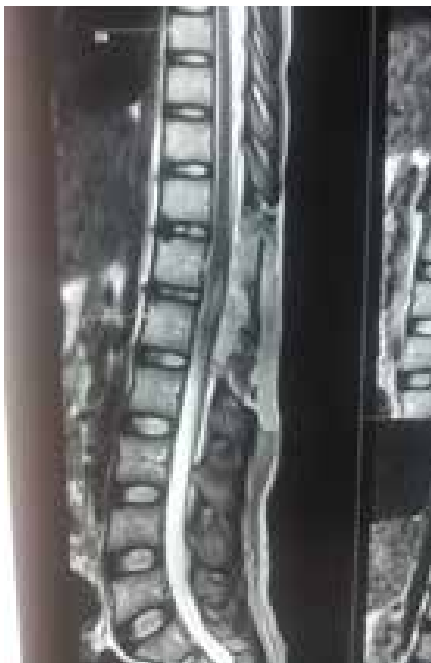

Fig 3; post op MRI

REFERENCE

- Amato VG, Assietti R , Arienta C: Intramedullary epidermoid cyst:preoperative diagnosis and surgical management after MRI introduction. Case report and updating of the literature. J Neurosurg Sci 2002,46:122-126. | 2. Roux A, Mercier C, Larbrisseau A, Dube LJ, Dupuis C, Del Carpio R: Intramedullary epidermoid cysts of the spinal cord. Case report. J Neurosurg 1992, 76(3):528-533. | 3. Zavanone M, Guerra P, Rampini PM, Crotti F, Vaccari U: A cervico-dorsal intramedullary epidermoid cyst, case report and review of the literature. J Neurosurg Sci 1991, 35(2):111-115. | 4. Lunardi P, Missori P, Gagliardi FM, Fortuna A: Long term results of the surgical treatment of spinal dermoid and epidermoid tumors. Neurosurgery 1989, 25(6): 860-864. | 5. Bloomer C W, Ackerman A, Bhatia RG: Imaging for spine tumors and new applications. Top Magn Reson Imaging 2006, 17(2):69-87. | 6. Jadhav RN, Khan GM, Palande DA: Intramedullary epidermoid cyst in cervicodorsal spinal cord. J Neurosurg 1999, 90(1 suppl):161. | 7. Tekkok IH, Palaoglu S, Erbeni A, Onol B: Intramedullary epidermoid cyst of the cervical spinal cord associated with an extraspinal neuroenteric cyst: case report. Neurosurgery 1992, 31(1):121-125. | 8. Ogden AT, Khandji AG, MC Cormic PC, Kaiser MG: Intramedullary inclusion cysts of the cervicothoracic junction. Report of two cases in adults and review of the literature. J Neurosurg Spine 2007, 7(2):236. | 9. Gonzalvo A, Hall N, McMohan JH, Fabinyi GC: Intramedullary spinal epidermoid cyst of the upper thoracic region. J Clin Neurosci 2009, 16(1):142-144. | 10. Kumar A, Singh P, Jain P, Badole CM: Intramedullary spinal epidermoid cyst of the cervicodorsal region: a rare entity. J Paediatr Neurosci 2010, 5(1):49-51. | 11. Fleming C, Kaliaperumal C, O'Sullivan M: Recurrent intramedullary epidermoid cyst of conus medullaris. BMJ Case Rep 2011. doi:10.1136/bcr.11.2011.5090. | 12. Chon KH, Lee JM, Koh EJ, Choi HY: Malignant transformation of an epidermoid cyst in the cerebellopontine angle. J Korean Neurosurg Soc 2012, 52(2):148-151. | 13. Hamlat A, Hua ZF, Saikali s, Laurent JF, Gedouin D, Ben Hassel M, Guegan Y: Malignant transformation of intracranial epithelial cysts: systematic article review. J Neurooncol 2005, 74(2):187-194. | 14. Huabin Yin, Dan Zhang, Zhipeng Wu, Wu, Wang Zhou and Jianru Xiao: Surgery and outcomes of six patients with intradural epidermoid cysts in the lumbar spine. World Journal of surgical Oncology, 2014, 12:50. |