ORIGINAL RESEARCH PAPER | Gynaecology | Volume : 6 | Issue : 12 | December 2016 | ISSN - 2249-555X | IF : 3.919 | IC Value : 79.96

Clinico-Histopathological Pattern of Ovarian Tumors and Tumor Like Lesions

KEYWORDS: Cystadnoma, teratoma, follicular cyst

LEENA VERMA
ASSISTANT PROFESSOR, DEPARTMENT OF PATHOLOGY, DR. S. N. MEDICAL COLLEGE, JODHPUR.

DHARMENDRA SINGH FATEHPURIYA
ASSISTANT PROFESSOR, DEPARTMENT OF OBSTETRICS AND GYNAECOLOGY, DR. S. N. MEDICAL COLLEGE, JODHPUR

ABSTRACT

INTRODUCTION
Tumors of ovary exhibit a variety of spectrum of histopathology more than any other organ.

MATERIAL AND METHODS
A retrospective and prospective study for a period of 2 Years in 428 ovarian specimen in the Department of Pathology, Dr. S. N. Medical college, Jodhpur.

RESULT
Total 268 cases (63%) were tumor like lesion and 160 cases (39%) were neoplastic lesion of ovary. The most common benign lesion was serous cystadenoma(50%) of all ovarian lesion followed by benign cystic teratoma (16.87%). The most common malignant lesion was serous cyst adenocarcinoma (7.5%) followed by mucinous cystadenocarcinoma(1.8%). Most common presenting complain was mass per abdomen and abnormal vaginal bleeding. Most common affected age group was 21 to 50 years.

CONCLUSSION
Most common ovarian tumor was surface epithelial tumor. In benign serous cyst adenoma and in malignant serous cystadenocarcinoma was common. In tumor like lesion follicular cyst was usually seen in ovarian specimens.

INTRODUCTION

Ovarian tumors and tumor like lesions can occur at any age and they present as major health problems in women. Their clinical presentation is highly variable ranging from asymptomatic patient to patient presenting with nonspecific symptoms [1] such as abdominal mass, ascites, bloating, back pain, urinary urgency, constipation and tiredness or more specific symptoms such as pelvic pain, abnormal vaginal bleeding or involuntary weight loss. [2,3,4,] Some of the lesions can be hormonally active so they can give rise to signs and symptoms of a hormone secreting tumor.

The most dreaded lesions are the malignant tumors of the ovary which is the fifth leading cause of death in women and the leading cause of death from gynaecological cancer. [5]

MATERIAL AND METHODS

This study was done in the Department of Pathology, Dr. S. N. Medical college Jodhpur for a period of 2 Years ie 6 months retrospective from January to June 09 and one and half years prospective from July 09 to December 2010.The received gross specimen was fixed in 10 % formalin for 24 hours and from every specimen multiple sections were taken from representative site for histological examination. Sections were processed in automated tissue processor after which their paraffin blocks were made and section was cut at 3 to 5 micron thickness and stained with hematoxylin and eosin stain. The sections were examined microscopically for histomorphological features so that histopathological diagnosis can be made.

OBSERVATION

TABLE-1: RESULT OF HISTOPATHOLOGICAL EXAMINATION OF OVARIAN SPECIMENS (OVERALL STUDY)

	No. of Cases	Percentage (%)
Benign tumors	136	31.77 %
Borderline tumor	03	0.70 %
Malignant tumor	21	4.90%
Tumor like lesions	268	62.61 %
Total No. of specimens	428	100.00%

The total number of ovarian specimens received were 428 out of which 268 (62.6%) cases of tumor like lesions, benign tumors were 136 (31.77%) and malignant tumors were 21 cases (4.90%).

The most common tumor was surface epithelial tumors with 123 cases (76.87%) followed by Germ cells tumor with 31 cases (19.37%), sex cord stromal tumors with 4 cases(2.55%) and metastasis in ovary with two cases (1.25%).

TABLE-2: DISTRIBUTION OF VARIOUS TUMORS

TUMORS	No. of cases	Percentage
SURFACE EPITHELIAL TUMORS		
Serous Tumors		
Serous cystadenoma	80	50.00
Borderline Serous Tumor	03	01.87
Serous Cyst adenocarcinoma	12	07.50
Serous Cyst adenofibroma	08	05.00
Mucinous Tumors		
Mucinous Cyst adenoma	15	09.37
Borderline Mucinous Tumor	00	00
Mucinous Cyst adenocarcinoma	03	01.87
Others		
Brenner Tumor	01	00.62
Mesonephroid Tumor	00	
Endometroid Tumor	01	00.62
Mixed Mullerian Tumor	00	00
Clear Cell Tumor	00	00
Mixed (mucionous + Serous)	00	00
SEX CORD STROMAL TUMOR		
Granulosa Cell tumor	02	01.25

Volume : 6 | Issue : 12 | December 2016 | ISSN - 2249-555X | IF : 3.919 | IC Value : 79.96

Thecoma Fibroma	02	01.25
Malignant Sex Cord Stromal Tumor	00	00
Androblastoma	00	00
GREM CELL TUMOR		
Teratoma (Dermoid Cyst)	27	16.87
Struma Ovarii	00	00
Endodermal Sinus Tumor	01	00.62
Dysgerminoma	03	01.87
Choriocarcinoma	00	00
METASTATIC LESION	02	01.25
MISCELLANEOUS	00	00
TOTAL	160	100

Figure a

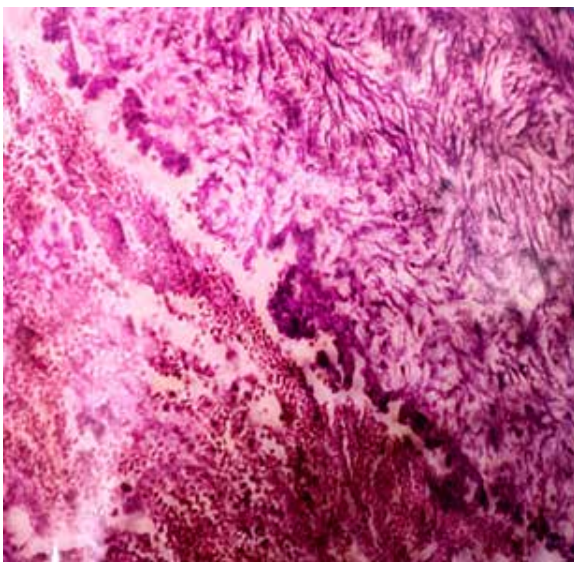

Figure b

[Fig-1a,b]: Serous cystadenoma. a. cut section shows unilocular cyst with papillary excrescences. b. Histology showing a simple cyst lined by a single layer of columnar epithelium resting on a fibrocollagenous stroma (H & E, 20X)

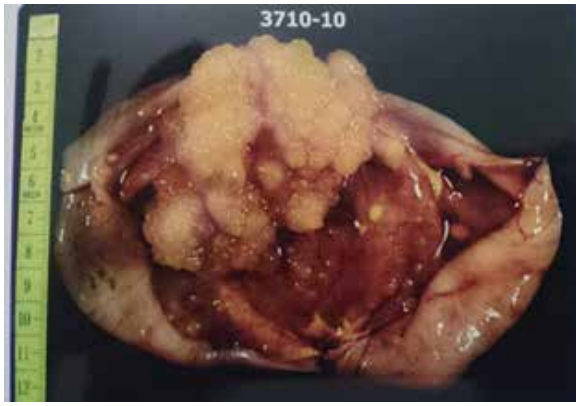

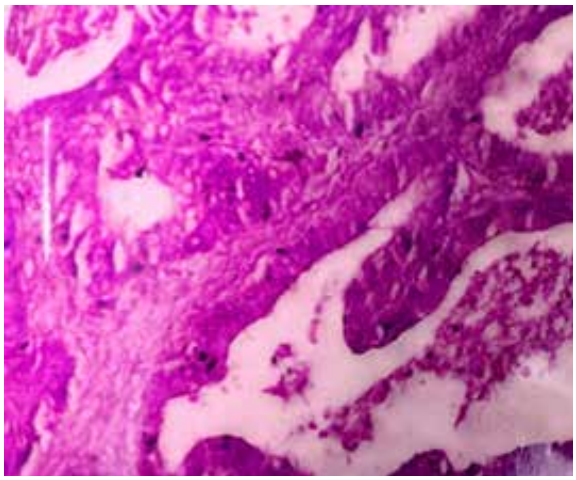

[Fig-2a,b]: Papillary serous cystadenocarcinoma. a. Cut section shows cyst with intra-cystic papillary excrescences and complex branching papillae. b. Histology shows papillary architecture with thick fibrovascular core, stratification and nuclear pleomorphism (H & E, 40X).

TABLE-3: AGE WISE DISTRIBUTION OF VARIOUS TUMORS OF OVARY

Age group in years	Surface epithelial tumor	Germ cell tumor	Sex cord stromal tumor	Metastatic tumor	Total
11-20	5	3	-	-	8
21-30	23	12	2	-	37
31-40	37	6	-	-	43
41-50	29	9	1	1	40
51-60	15	1	1	-	17
61-70	8	-	-	1	9
71 onward	6	-	-	-	6

Out of 160 cases, 120 cases were found between 21 to 50 years age group.

In germ cell tumor, mature teratoma was most common tumor with 27 cases followed by dysgerminoma with 3 cases and yolk sac tumor with 1 case.

Sex cord stromal tumor comprised of 2.5% of all tumor lesion with 2 cases of granulosa cell tumor, 1case of thecoma and 1 case of thecoma-fibroma.

Two cases of metastatic lesion of krukenberg tumor and undifferentiated adenocarcinoma were noted.

Volume : 6 | Issue : 12 | December 2016 | ISSN - 2249-555X | IF : 3.919 | IC Value : 79.96

Out of 268 cases of tumor like lesions most common was follicular cyst with 94 cases followed by hemorrrhagic cyst (66 cases), luteal cyst (58 cases), simple serous cyst (40 cases), other inflammatory conditions and endometriosis with 10 cases.

In this study mass per abdomen was the commonest presenting symptom in 39.25% followed by abnormal vaginal bleeding in 28% and pain abdomen in 19.8%.

DISCUSSION

In this study incidence of surface epithelial tumor (76.87%) was highest followed by germ cell tumor(19.37%), sex cord stromal tumor (2.5%) and lastly metastatic tumor (1.25%) similar to other studies.

Incidence of serous cystadenoma (50%) was much higher similar to Maheshwari et al (32.21%)[6] and R. Jha & S Karki (26.82%)[7]. Incidence of Borderline Serous tumor was 1.87% comparative with the study of Pilli et al[8] (1.41%). Incidence of serous cystadenocarcinoma forming 7.5% correlated closely with that of R. Jha & S Karki (7.31%)[7].

Incidence of mucinous cystadenoma was 9.37% similar to R. Jha & S. Karki (12.8%)[7]. Incidence of Mucinous cystadenocarcinoma was 1.87% lower than other studies.

Incidence of Brenner tumor forming 0.62% similar to Maheshwari et. al.[6] (0.70%). Incidence of Endometrioid tumor (0.62%), similar to Pilli et al[8] (0.70%). Incidence of Granulosa cell tumor (1.25%) close to Sarin et al[9]. Incidence of fibrothecoma was 1.25%. Incidence of Benign Cystic Teratoma was 16.87% correlated with Bhattacharya M. et al.[10] Incidence of Dysgerminoma comprised of 1.87% of all ovarian tumors which can be correlated with Shah et al (0.54%)[11]. Incidence of Endodermal sinus tumor was 0.62% similar to R.Jha and S.Karki.

Similar to this study, other studies also show that most ovarian tumors occur in women of reproductive age group. Peak incidence of ovarian tumor is between 21- 50 years.[8]

CONCLUSSSION

Most common ovarian tumor was surface epithelial tumor. The most common benign lesion was serous cystadenoma(50%) of all ovarian lesion followed by benign cystic teratoma (16.87%). The most common malignant lesion was serous cyst adenocarcinoma (7.5%) followed by mucinous cystadenocarcinoma(1.8%). Most common presenting complain was mass per abdomen and abnormal vaginal bleeding. Most common affected age group was 21 to 50 years. Ovary exhibit a variety of histopathological spectrum, therefore routine histopathological examination is very important for diagnosis of ovarian tumors.

REFERENCES

1. Goff, B. A., Mandel, L., Muntz, H. G., & Melancon, C. H. (2000). Ovarian carcinoma diagnosis. *Cancer*, *89*(10), 2068-2075.
2. Bankhead, C. R., Kehoe, S. T., & Austoker, J. (2005). Symptoms associated with diagnosis of ovarian cancer: a systematic review. *BJOG: An International Journal of Obstetrics & Gynaecology*, *112*(7), 857-865.
3. Ryerson, A. B., Eheman, C., Burton, J., McCall, N., Blackman, D., Subramanian, S., & Richardson, L. C. (2007). Symptoms, diagnoses, and time to key diagnostic procedures among older US women with ovarian cancer. *Obstetrics & Gynecology*, *109*(5), 1053-1061.
4. Goff, B. A., Mandel, L. S., Melancon, C. H., & Muntz, H. G. (2004). Frequency of symptoms of ovarian cancer in women presenting to primary care clinics. *Jama*, *291*(22), 2705-2712.
5. Gynecologic Neoplasm at Merck Manual of Diagnosis and Therapy Professional Edition
6. Maheshwari V, Tyagi SP, Saxena K, Tyagi N, Sharma R, Aziz M, Hameed F.(1994). Surface Epithelial tumors of the ovary. Indian J Pathol Microbiol. 37(1):75-85.
7. Jha, R., & Karki, S. (2008). Histological pattern of ovarian tumors and their age distribution. Nepal Med Coll J, 10(2):81-85.
8. Pilli, G. S., Suneeta, K. P., Dhaded, A. V., & Yenni, V. V. (2002). Ovarian tumours: a study of 282 cases. *Journal of the Indian Medical Association*, *100*(7), 420-423.
9. Sarin A, Singla P. Gupta V.(1992) Ovarian tumours in postmenopausal women. J of Obstetrics and Gynaecology :26(3):225-28.
10. Bhattacharya, M. M., Shinde, S. D., & Purandare, V. N. (1980). A clinicopathological analysis of 270 ovarian tumours. *Journal of postgraduate medicine*, *26*(2), 103.
11. Shah PK, Shroff CP, Deodhar KP and Vaidya PR. (1991). Ovarian tumors in childhood and adolescent. J of Obstet and Gynecol;26(4):397-402.