



## Annular Pancreas Producing Duodenal Obstruction : A Case Report

### KEYWORDS

Annular pancreas; duodenal stenosis; duodenojejunostomy

**Dr.Nareshkumar**

Dept of general surgery

**Dr.Phanikrishnaravula**

Dept of general surgery

**ABSTRACT** Annular pancreas is a rare congenital anomaly characterized by the presence of ectopic pancreatic tissue surrounding the duodenum. This malformation is usually asymptomatic in adults, but can manifest as pancreatitis, duodenal stenosis, or duodenal or gastric ulceration. We report the case of a young patient of 35 years old hospitalized for epigastric pain and vomitings, in whom radiological investigations showed an annular pancreas. At operation, a complete obstruction of duodenum between its first and second parts was found, caused by an annular pancreas. No other congenital anomaly of intra abdominal organs was noted. A duodenojejunostomy was performed. Both rarity of this congenital abnormality and its successful correction by surgical means have prompted us to make the following presentation.

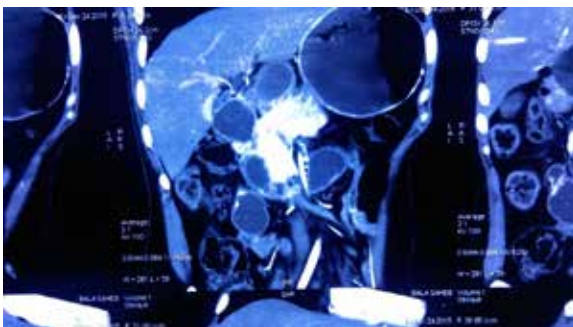
### 1.INTRODUCTION

Annular pancreas is a rare congenital anomaly of the pancreatic ducts[1]. This anomaly is due to incomplete rotation of the ventral pancreatic bud. Annular pancreas is diagnosed with nearly equal frequency in children and adults[2]. The factors initiating symptoms are recurrent pancreatitis, duodenal stenosis and duodenal or gastric ulcerations[3].

One new case of duodenal obstruction due to annular pancreas is presented.

### 2.CASE REPORT

An 35 years old male presented with a history of recurrent attacks of epigastric pain, nausea and vomiting. Symptoms had been present for more than months, but had become more frequent in the last few weeks. On examination, he was found to have a Spanish sound. Side view duodenoscopy revealed an important concentric narrowing of the second part of duodenum which could not be crossed. Computed tomography (CT) scanning showed an annular pancreas encircling the second part of duodenum (figure 1).



**Figure 1.** Computed tomography of abdomen showing the annular pancreas encircling the second part of duodenum.

Our patient was taken to laparotomy which confirmed the annular pancreas encircling the duodenum. The first part of duodenum was dilated. This enlargement extended downward to second part of duodenum, which was markedly constricted by a ring of pancreatic tissue which completely

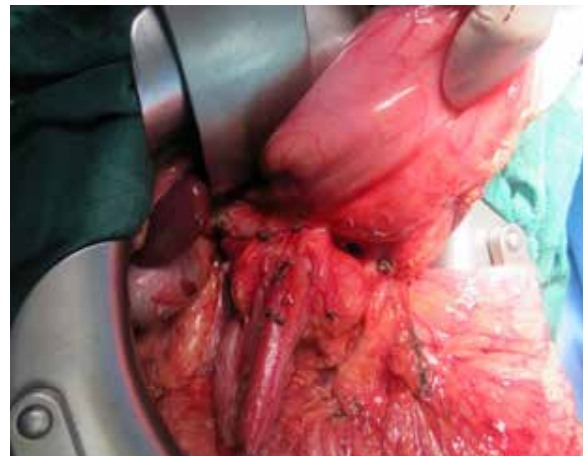
surrounded the duodenum and which was continuous with head of the pancreas. No other congenital anomaly of the intra abdominal organs was noted. A duodenojejunostomy was performed without technical difficulty. The patient made an excellent recovery, and he was discharged from hospital 4 days later. He remains in good general health 6 months after the surgery (figures 2 and 3).

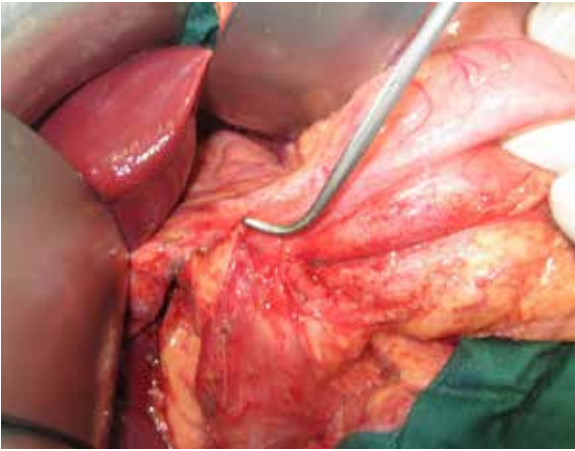
### 3.DISCUSSION

Annular pancreas was first described by Tiedman in 1818[4], and named by Ecker in 1862[5].

Only 737 cases of annular pancreas have been reported in literature[1]. It is a rare congenital anomaly (the incidence is approximately 3 in 20000), and it is the most common anomaly of the pancreatic ducts after pancreatic divisum[2].

Three developmental theories explain the formation of an annular pancreas. Baldwin in 1910 suggested that there was a failure of atrophy of the left component of the ventral pancreatic anlage which maintains a true ventral connection[2]. Lecco's theory suggests that the ventral pancreas adhered to surrounding tissues at its site of origin in the ventral mesogastrium, maintaining a true ventral connection[6]. The third theory, explained by Verga in 1972 [7], suggests that the primary





**Fig 2 and 3. Intra operative photograph showing an annular ring of pancreatic tissue around the duodenum.**

abnormality is duodenal with the pancreas "filling the space " around a narrowed duodenum.this results in a complete or in complete stenosis of the duodenal lumen.

It has been estimated that only about 33% of the cases are symptomatic[3].in children,annular pancreas appears most often in the first weeks of life by symptoms related to duodenal stenosis[2];and other associated congenital malformations have been reported like common mesentery,heartdefects,down syndrome(trisomy 21),imperforate anus,ortracheoesophageal malformations[2].in adults,the age of revelation is usually between 20 and 50 years.the most frequently found symptoms are:abdominal pain(70%),vomiting and nausea(47%),and they are generally reflecting a proximal intestinal obstruction[8].other clinical manifestations have been reported:peptic ulcer secondary to stasis upstream of duodenal stenosis,acute or chronic pancreatitis due to the default flow of pancreatic secretions in annular pancreas,and jaundice due to the common bile duct stegnosnosis by the annular pancreas or related to a lithiasic origin[2,8]

The diagnosis of annular pancreas used to be based on duodenography which showed a medio duodenal stenosis corresponding to the pancreatic ring[8].nowdays, CT Scan allows us to see the pancreatic ring encircling the duodenum[2].the echo endoscopy also allows approaching the diagnosis by showing the ring of normal pancreatic tissue encircling the duodenum ,but the pancreato MRI remains the most reliable diagnostic tool and allows to highlight the presence of a pancreatic duct encircling the duodenum[8,9].Endoscopic retrograde cholangiopancreatography(ERCP) can also make the diagnosis,but it remains invasive and sometimes impossible in case of an uncrossable stenosis of the duodenal lumen[9].

The treatment of annular pancreas is surgical.its aim is relief of the duodenal obstruction.for this, there are various procedures being used.the first one is directly attack the obstruction by dividing or removing a portion of the annular pancreas despite the associated hazards of pancreatic or duodenal fistula[1,10],furthermore ,the division of the annular pancreas is often followed by (up to 50% of cases)[10].on the other side,the majority of surgeons have elected to bypass the obstruction by establishing a gastrojejunostomy,alatero lateral anastomosis of first part of the duodenum with jejunum,or a duodeno-jejunal anas-

tomosis with roux en Y loop[3,10].the frequent association of peptic ulcer and the risk of anastomotic ulcer suggest the need for a procedure like vagotomy which reduces acid secretion by the stomach.thus from available evidence it appears corrective operations for annular pancreas should include vagotomy and gastrojejunostomy and avoid the duodenum and the annular pancreas[10].

#### 4.CONCLUSION

Annular pancreas is a rare malformation that manifests itself primarily by signs related to duodenal stenosis.the diagnosis is currently based on abdominal CT scan and MRI of the pancreas .Treatment is exclusively surgical,and a bypassing procedure is the method of choice in the treatment of annular pancreas producing duodenal obstruction. Both the rarity of this congenital abnormality and its successful correction by surgical means have prompted us to make this presentation.

#### 5. AUTHOR'S CONTRIBUTION

Dr.Phanikrishnaravula and Dr.Nareshsriramula were the surgeons treating the patient and were involved in critically revising the draft for content.

#### REFERENCES

- [1] Zyromski, N.J.,Sandoval, J.A., Pitt, Ladd, A.P.,Fogel,E.L., Mattar, W.E., Sandrasegaran, k., Amrhein,D.W.,Rescorla, F.J., Howard, T.J., Lillemoe, K.D. and Grosfeld, J.L. (2008) Annular pancreas: Dramatic differences between children and adults. The journal of the American college of surgeons, 206,1019-1025.
- [2] Heyries, L. and Sahel, J. (2010) Anomalies congenitales du pancreas. Hepatologie[7-102-a-15] Elsevier masson.
- [3] Bouassida, M., Sassi, S.E., Touinsi, H., Mighri, M.M., Chtourou, M.F., Chebbi, F. and Sassi,S.A.(2011) A rare cause of proximal intestinal obstruction in adults- Annular pancreas : A case report. Pan African Medical journal,10,56.
- [4] Tiedman, F.(1818) Annular pancreas. Dutch Archives of Physiology,4,403.
- [5] Ecker, A. (1862) Bildungsfehler des pancreas und des herzens.
- [6] Lloyd -Jones, W.,Mountain,J.C.and Warren, K.W.(1972) Annular pancreas in the adult.Annals of surgery,1972, 163-170.
- [7] Dowsett, J.F., Rode,J. and Russell,R.C.G(1989) Annular pancreas: A clinical, endoscopic, and immunohistochemical study, Gut,30,130-135.
- [8] Yogi,Y,Shibue,T. and Hashimoto,S .(1987) Annular pancreas detected in adults,diagnosed by endoscopic retrograde cholangiopancreatography: Report of four cases,Gastroenterologia Japonica,22,92-99.
- [9] Kandpal, H., Bhatia, V., Garg,Pand Sharma, R. (2009) Annular pancreas in an adult patient:diagnosis with endoscopic ultrasonography magnetic resonance cholangiopancreatography.Singapore medical journal,50, e29.
- [10] Thomford N.R., Knight, P.R., Pace, W.G. and Madura, J.A. (1972) Annular pancreas in the sz78loo/p;[pogdsari=-\adult:Selection of operation. Annals of surgery,1972,159-162.