



Traumatic Rupture of Tibialis Anterior Tendon Treated With Flexor Digitorum Longus Graft

KEYWORDS

Traumatic rupture, tibialis anterior tendon, flexor digitorum longus, graft

Gautham Kiron T

Consultant Orthopedic surgeon.
SIGMA Hospital, Saraswathipuram,
Mysore 570009

Parineetha R Bellavi

Resident, Department of
Anaesthesia, JSS Medical College
and Hospital, Mysore 570015

Ravi Kumar

Senior resident, Department of
Orthopedics, Maharaja Agarsen
Hospital, Punjabi Bagh,
New Delhi 110026

Chaitanya Ganne

Department of Clinical Neurosciences, NIMHANS, Bangalore 560029

ABSTRACT

A delay in diagnosis and management of traumatic rupture of tibialis anterior tendon can lead to chronic ankle pain and instability. Early surgical intervention has been described using extensor hallucis longus (EHL) graft with post operative deficits ranging from abnormalities of early swing phase of gait, stubbing and callosities of great toe. We report a traumatic rupture of tibialis anterior tendon which was managed surgically with flexor digitorum longus (FDL) graft in an elderly gentleman who was admitted for disabling pain in the anterior aspect of his left ankle and difficulty in walking. FDL was harvested and grafted to the ruptured tibialis anterior defect and anchored to the medial cuneiform. Follow-up 6 months after surgery revealed normal gait, good functional and pain free range of motion. The use of FDL graft was adequate in maintaining the movements of the foot and preventing the more frequently noted complications of EHL grafts.

INTRODUCTION

Tibialis anterior tendon (TAT) rupture is an uncommon entity with only a few cases reported in literature [1,2,3,4,5]. Ruptures can be either spontaneous or traumatic. The aetiologies was first described by Bruning in 1905 [3]. Spontaneous ruptures may be due to metabolic conditions such as diabetes mellitus, gout, hyperparathyroidism [3], systemic lupus erythematosus, rheumatoid arthritis [3] and local steroid infiltration [1,2]. Other causes include repetitive friction and pressure due to the presence of dorsal pedal or anterior talotibia exostosis [5], Quinolone treatment has recently been recognised as a cause [3,6]. The diagnosis is often delayed as they go unnoticed by patients [7]. Repair can be more challenging due to the retraction and defects at the distal end of the tendon. Spontaneous ruptures are more common in the older male population in the fifth to seventh decade of life usually occur in the avascular zone 5 to 30 mm from the insertion site [3]. Closed ruptures of the tibialis anterior tendon are usually caused by a forced plantar flexion mechanism of traumatic event [3,5] or a tight gastrosoleus complex leading to laceration of the tendon. The diagnosis is based on clinical examination mainly and on radiological confirmation. Spontaneous ruptures can be managed conservatively, while surgical treatment is mandatory in traumatic ruptures as it is associated with better functional outcomes and less complication rates [1,2]. Extensor hallucis (EHL) tendon is most commonly used as it lies adjacent to the TAT sheath and can be addressed with the just a small incision at its insertion site. EHL graft leads to gait abnormalities, difficulty in pulling on socks and shoes, callosities at the dorsum of great toe, hammer toe prominence of metatarsal head, neuroma [7]. In order to avoid such complications we present a case of surgically treated TAT rupture with Flexor digitorum longus (FDL) graft

CASE PRESENTATION:

A 71 year old gentleman was admitted with the complaints of left anterior ankle pain following injury to the left ankle while climbing uphill. The mechanism of injury was forced plantar flexion. He had a difficulty in walking and raising the foot off the ground. Patient was a known hypertensive since 12 years. There was no history of diabetes mellitus, local steroid infiltration or inflammatory joint diseases.

Clinical examination of left ankle revealed loss of the normal contour of tibialis anterior, a foot slapping gait with a tendency for toe dragging, difficulty in heel walking, tenderness over the medial aspect of the ankle and decreased dorsiflexion strength Grade 0/5 as per the medical research council scale [8]. Features of flat foot were not present.

X ray studies of left ankle under antero-posterior and lateral views were normal. Magnetic resonance imaging (MRI) showed a complete rupture of TAT with retraction of the proximal tendon stump and surrounding edema (Fig1). After confirming normal hemodynamic and cardiorespiratory status of the patient, he was taken up for reconstructive surgery with FDL graft.
"Fig1 about here"

OPERATIVE PROCEDURE:

Under spinal anaesthesia and a well padded pneumatic tourniquet to the upper thigh, patient was placed in a supine position over the operating table with a sand bag support under the ipsilateral hip. (Fig 2a-d) Two incisions were made – 1) a linear incision over the tibialis anterior tendon taking care to protect the cutaneous nerve and 2) a second incision over the medial aspect of the foot extending to the medial malleolus posteriorly. Through the first incision, the superior and inferior extensor retinaculum was cut and the tendon sheath exposed and opened. Ten-

don appeared retracted with a gap of 3 cm and both the ends were oedematous and unhealthy. This made it difficult to reattach it to the medial cuneiform.

Through the second incision the flexor hallucis longus (FHL) and the flexor digitorum longus (FDL) were identified and isolated at the Henry's knot. FDL was cut and its distal stump was sutured to the FHL. FDL was cut proximally at the level of the medial malleolus to obtain adequate graft length. The harvested graft was prepared and sutured to the distal end of the lacerated tibialis anterior tendon the other end was fixed to the medial cuneiform at the attachment of the tibialis anterior with the aid of suture anchor with foot in slight dorsiflexion and neutral version. The superior and inferior extensor retinaculum was repaired. This was followed by wound closure and below knee plaster in 15° dorsiflexion for 6 weeks. The immediate post-operative period was uneventful. At the end of 6 weeks the plaster was removed and daily active assisted exercise were started. At 8 weeks active use of foot with the aid of crutches were allowed. At 3 months near normal active dorsiflexion of foot was observed and At 6 months, there was good functional recovery, with no gait abnormalities. Patient was eventually able to heel walk and his MRC grade of dorsiflexion improved to 4+/5. The American Orthopaedic Foot and Ankle Society [AOFAS] score [9] was 82.

DISCUSSION:

Tibialis anterior accounts for nearly 80% of the strength required for dorsiflexion of the ankle, its rupture is an uncommon event and can lead to significant deformity as well as loss of function. Due to the subtle symptoms like low intensity of pain, and presence of compensatory muscles for gait balance the rupture goes neglected by the patients and unnoticed by doctors. Rupture may be spontaneous or traumatic, the causes of which have already been elaborated earlier. Bunnell and by McMaster stated that the tibialis anterior may rupture in one of four locations. [2,3,4]. Its order of frequency 1) the insertion (by rupture of the tendons fibres or avulsion of a fragment of bone) 2) the musculotendinous juncture 3) the muscle belly 4) the origin (in which rupture is rare) [4].

Diagnosis is mainly by clinical examination, in acute injuries there is swelling, ecchymoses, loss of normal tendon contour, a palpable defect along the course of the tendon and tenderness. The patient has weakness of the foot with limitation of dorsiflexion, gait analysis shows a variable degree of foot drop with dragging of toes [4,7]. The defect is made more evident by asking the patient to heel walk [1,4,10]. The differential diagnosis of anterior tibial syndrome and peroneal nerve palsy has to be ruled out [1]. Radiological evaluation is done with ultrasound and MRI [4,11], MRI is the diagnostic tool of choice [3], a partial tear will show an attenuated tendon with increased surrounding fluid and a complete tear will show a clear discontinuity of the tendon, thickening of the retracted portion and excess of fluid collection in the tendon sheath [4,12].

Due to the rarity of the condition there is no consensus regarding the optimal treatment [1,7]. Conservative management is reserved for elderly moribund patients and patients with incomplete tear [1,2,4]. Treated mainly by plaster cast, ankle foot orthosis, bracing and immobilization [5]. There are various studies that have shown complications with conservative management like Trout et al., showed patients to have a late foot drop sequel, flat foot deformity and ankle arthrosis [5,13]. In young and active

patients surgical repair of the tibialis anterior tendon rupture is highly indicated [4]. Surgery with direct end-to-end repair is done in acute cases. Most commonly due to delay of the diagnosis, repair will be needed to fill the defect. Once retracted, and the necrotic tendon is derided, there can be a defect of 8 cm or more. Common techniques that are used to repair a neglected tibialis anterior tendon rupture are extensor hallucis longus tendon transfer most commonly used, flap-down of the ruptured tibialis anterior tendon, peroneus tertius tendon, achilles tendon, semitendinosus muscle tendon [1,2], autogenous grafting (split harvesting of peroneus longus tendon), allografting, xenografting, and nonanatomic repair (attaching the tibialis anterior tendon to the talus). Surgery requires sufficient exposure along the course of tendon to secure the proximal end, mobilize it, and approximate it to the distal portion. Grafts are used based on the defects present. How much tension to put on the repaired tendon is controversial. It has to be tensioned as long as there is no deformity of the foot. The foot is generally maintained halfway dorsiflexed and in neutral version. The tendon/ graft can be sutured to the medial cuneiform or attached with suture anchors for adequate strength. The extensor retinaculum has to be repaired to prevent the bow stringing phenomenon and cicatricial adhesion to the subcutaneous tissue [1,2]. Patients are put on a plaster cast for 6 weeks and returned to normal activity at 6 months. The usage of the more common EHL graft leads to gait abnormalities especially at early swing phase of gait cycle, with the risk of falling due to stubbing of the hallux on the floor, hammer toe, as a foot devoid of tibialis anterior the extensors act as the main dorsiflexors of the foot, difficulty in pulling on socks and shoes, callosities at the dorsum of great toe, though to some extent EHB substitutes the function of lost EHL plantar prominence of metatarsal head, neuroma [7]. EHL needs to be applied in more tension to match the strength of tibialis anterior tendon. To avoid such complications we used the FHL graft which showed promising results.

CONCLUSION:

Early diagnosis of tibialis anterior tendon ruptures requires adequate clinical examination and radiological confirmation. The use of FHL tendon graft helps maintain the function of all toes of the foot, allowing normal gait and avoids complications seen in using the EHL graft. Despite the age of the patient, surgical intervention allowed for an excellent functional recovery as pre injury state.

Figures and legends:

Fig 1: T1 weighted MRI of left ankle showing ruptured tibialis anterior tendon with retraction and surrounding oedema.

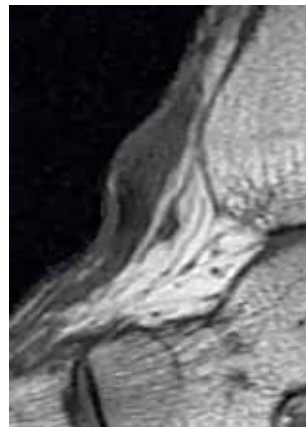
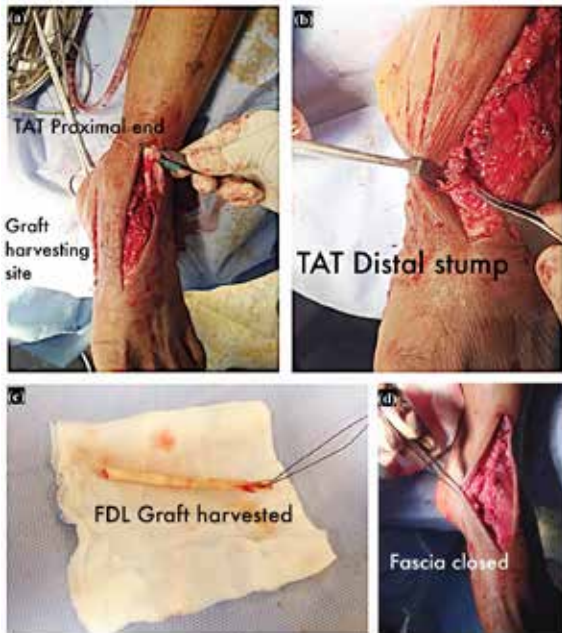


Fig 2: Shows a composite image of stepwise surgical procedure: (a) anterior incision and identification of proximal stump of unhealthy ruptured tibialis anterior tendon (b) distal stump of ruptured tibialis anterior tendon. (c) harvested FDL graft (d) reconstruction of the superior and inferior extensor retinaculum of ankle.



REFERENCES

1. M. E. Rodrigues, A. Pereira, B. Alpoim, J. M. Geada, (2013). Traumatic rupture of the tibialis anterior tendon: A case report. *Rev Bras Orthop*, 48, 278-281.
2. V. J. Sammarco, G. J. Sammarco, C. Henning, S. Chaim, (2009). Surgical repair of acute and chronic tibialis anterior tendon ruptures. *J Bone Joint Surg Am*, 91, 325-32.
3. E. Palmanovich, Y. S. Brin, L. Laver, D. B. David, S. Massrawe, M. Nyska et al., (2013). Chronic tibialis anterior tendon tear treated with an achilles tendon allograft technique. *Article in Orthopedics*, 36,850-853.
4. J. T. J. Jerome, M. Varghese, B. Sankaran, K. Thirumagal, (2010). Tibialis anterior rupture: A missed diagnosis. *The Foot and Ankle Online Journal*, 3, 2.
5. L. A. DiDomenico, K. Williams, A. F. Petrolla, (2008). Spontaneous rupture of the anterior tibial tendon in a diabetic patient: results of operative treatment. *The Journal of Foot & Ankle Surgery*, 47,463- 467.
6. F. Kaleagasioglu and E Olcay, (2012). Fluoroquinolone-induced tendinopathy: etiology and preventive measures. *Tohoku J Exp Med.*, 226, 251-258.
7. C. Christman-Skieller, M. K. Merz, J. P. Tansey, (2015). A systematic review of tibialis anterior tendon rupture treatments and outcomes. *Am J Orthop (Belle Mead NJ)*, 44, E94-9.
8. T. Paternostro-Sluga, M. Grim-Stieger, M. Posch, O. Schuhfried, G. Varcariu, C. Mittermaier, C. Bittner, V. Fialka-Moser, (2008). Reliability and validity of the medical research council (MRC) scale and a modified scale for testing muscle strength in patients with radial palasy. *J Rehabil Med*, 40,665-671.
9. J. J. Cook, E. A. Cook, B. I. Rosenblum, A. S. Landsman, T. S. Roukis, (2011). Validation of the American College of Foot and Ankle Surgeons Scoring Scales. *The Journal of Foot & Ankle Surgery*, 50, 420-429.
10. J. T. J. Jerome, M. Varghese, B. Sankaran, S. Thomas, S. K. Thirumagal, (2008). Tibialis anterior tendon rupture in gout - Case report and literature review. *Foot and ankle surgery*, 14,166-169.
11. G. S. Sapkas, A. Tzoutzopoulos, F. C. Tsoukas, I. K. Triantafillopoulos, (2008). Spontaneous tibialis anterior tendon rupture: delayed repair with free-sliding tibialis anterior tendon graft. *Am J Orthop*, 37, E213-E216.
12. R. A. Gallo, B. H. Kolman, R. H. Daffner, R.L. Sciulli, C. C. Roberts, P. J.

DeMeo , (2004). MRI of tibialis anterior tendon rupture. *Skeletal Radiol*, 33,102-106.

13. B. M. Trout, G. Hosey, S. J. Wertheimer, (2000). Rupture of the tibialis anterior tendon. *J Foot Ankle Surg*, 39,54-58.