



Pterygium Management – Today

KEYWORDS

Pterygium-Conjunctival graft- PERFECT - bare sclera- recurrence

Dr. R B Goyal

asst prof, NIMS university Jaipur

Dr. Karishma Goyal

ABSTRACT

The pterygium is a common eye disorder. Medical therapy is not effective and the aim of surgery is complete removal of the lesion and the prevention of recurrence. Though wide variety of treatment modalities are available but no one is ideal. We did 30 cases in our institution. Grp 1-15 with simple pterygium excision & putting mitomycin C for 1 minute. Grp 2 -15 cases with conjunctival autograph. Recurrence rate in Grp 1 is above 25% while in Grp 2 it was in 1 case only that was too small. Hence in our study after 6 months follow up result is that conjunctival autograph method is economical with higher success rate.

Pterygium was first described in 1000 BC by Sushruta. The prevalence rates vary in different parts of the world, and is highest in the "Pterygium belt" described by Cameron between the latitudes 37° north and south of the equator¹. The prevalence in India ranges from 9.5 to 13%² and is more common in rural & dusty parts of the country. The earliest described surgical approach was simple excision leaving the scleral bed bare. Although this can be performed as an office procedure, the recurrence rates range from 30 to 80%. Since then, various modifications in technique have been reported and with current approaches, the recurrence rates after surgery can be as low as 0%⁴.

Pathophysiology

Among the several risk factors reported, exposure to UV rays & dust is perhaps the most accepted risk factor for the occurrence of pterygium.³ UV radiation can cause mutations in genes such as the p53 tumor suppressor gene, resulting in abnormal pterygial epithelium. Recent studies have suggested that human papilloma virus may also be implicated in pterygium pathogenesis.⁴ Matrix Metalloproteinases (MMPs) and tissue inhibitors of MMPs (TIMs) at the advancing pterygium edge may be responsible for the inflammation, tissue remodeling, destruction of Bowman's layer and pterygium invasion into the cornea.⁵ It has also been speculated that a pterygium may represent an area of localized limbal stem cell deficiency, with result invasion of the adjacent cornea by the conjunctiva.

Evolution of Approaches to Management of Pterygium Bare Sclera Technique

This technique involves surgical excision of the pterygium with the exposed sclera left bare. This has a high recurrence rate ranging from 30-80 %, and is hence, seldom used today. Other variations of this approach were tried to mitigate the high recurrence rate, and these named procedures include - primary closure of the defect, splitting the head of the pterygium, rotation of the pterygium head away from the cornea and repositioning the head of the pterygium.⁶ While these modifications did improve the results, recurrences were still common, and the technical complexity of these procedures limited their use.

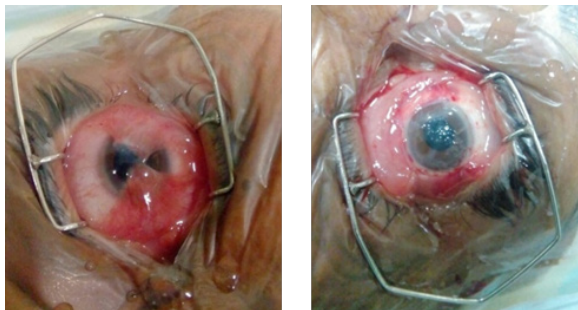
Conjunctival Flap

Sliding conjunctival flaps harvested from the inferior or superior bulbar conjunctiva were used to close the scleral defect. Although the recurrence rate reported by this technique is 1-5%, the surgery is technically complicated with suboptimal cosmesis.⁷

Conjunctival Autograft

The first real advance in Pterygium management was the description of the technique of conjunctival-limbal autograft transplantation after Pterygium excision, by Kenyon in 1985.⁸ Conjunctival-limbal autografts are associated with recurrence rates ranging from 0 to 15%. In a series from India, Rao et al reported the outcomes of this procedure in 53 eyes with 36 primary and 17 recurrent pterygia, with a mean follow-up of 18.9 + 12.1 months. The recurrence rate was 3.8%.⁹ A wire speculum is used to separate the lids. A superior rectus bridle suture is inserted. The suture is used to abduct the eye maximally (assume nasal pterygium) by clipping it to the drapes adjacent to the lateral canthus. A small incision is made in the conjunctiva just medial to the head of the pterygium. The conjunctiva is progressively dissected from the body of the pterygium towards the caruncle. The head of the pterygium is left attached to the cornea, enabling easier dissection of the conjunctiva. The corneal epithelium 2 mm ahead of the head of the pterygium is scraped off. Once the plane is defined, the pterygium head is easily avulsed using a combination of blunt dissection and traction. Residual fibrous tissue on the cornea is removed by sharp dissection with a No. 15 Bard-Parker blade. The body of the pterygium with the involved Tenon's capsule and cicatrix is then excised, taking care to ensure the safety of the underlying medial rectus muscle and the overlying conjunctiva. The size of the conjunctival graft required to resurface the exposed scleral surface is determined using Castroviejo calipers. The measured dimensions are marked on to the superiotemporal conjunctiva the graft is excised starting at the forniceal end. Once the limbus is reached, the graft is flipped over on to the cornea and the Tenon's attachments at the limbus were meticulously dissected. The flap is then excised using a Vannas scissors, taking care to include the limbal tissue. After excision, the conjunctival-limbal graft is slid onto the cornea. Without lifting the tissue off the cornea, it is rotated and moved onto its scleral bed with fine non-toothed forceps. A limbus-limbus orientation is maintained. The graft is secured using interrupted 10-0 nylon sutures. The four corners of the graft are anchored with episcleral bites to maintain position. The donor area is covered by pulling the forniceal conjunctiva forward and anchoring it to the limbal episcleral tissue with 2 interrupted 10-0 nylon sutures. 0.5cc dexamethasone is injected subconjunctivally at the conclusion of the procedure and the eye is patched firmly with antibiotic eye ointment.

Postoperatively, topical betamethasone eye drops are used in tapering dose for a month with Antibiotic drops. Any retained sutures are removed at 6 weeks.



Before

After

P.E.R.F.E.C.T Surgery:

Dr Hirst from Australia reports a recurrence rate of 0.5% with a technique he calls P.E.R.F.E.C.T. which stands for Pterygium Extended Removal Followed by Extended Conjunctival Transplant'. In this approach, he does an extensive conjunctival autografting of about 15mm by 12 mm.¹⁰ The main limitation is that this is time consuming and technically challenging procedure.

Free Conjunctival Autograft

It has been suggested that including limbal stem cells in the conjunctival auto graft (limbal-conjunctival graft) may act as a barrier to conjunctival cells migrating onto the corneal surface and help prevent recurrence. The recurrence rates after limbal-conjunctival auto graft surgery range from 0 to 15%. This technique may also be advantageous when surgery is performed in a patient with a subsequent risk of glaucoma and the need to preserve the superior bulbar conjunctiva. However, it is possible that limbal-conjunctival autografts are more effective than conjunctival autografts for recurrent pterygium.¹¹

Conjunctival Rotation Autograft Surgery

Conjunctival rotation autografting was first described by Tan et al,¹² and requires the removal of conjunctiva over the body of the pterygium. This tissue is stored in saline, while the rest of the surgery is performed to remove the Pterygium. Subsequently, the tissue is replaced and sutured in place in the bare scleral bed, with the limbal aspect of the graft now facing the fornix and vice versa. This is a useful technique for cases in which it is not possible or desirable use the superior conjunctiva as a donor source, such as with excision of extensive pterygium, which leaves insufficient conjunctival tissue for the autograft, double pterygium glaucoma surgery etc. Recurrence rate with this technique has been described as 4%.¹³

Amniotic Membrane Transplantation

Amniotic membrane transplantation has recently been proposed as a treatment option to prevent recurrences. Amniotic membrane possesses anti-scarring, anti-angiogenic and anti-inflammatory properties, which may be useful for treating pterygium. An additional advantage is that it removes the need for harvesting large autografts, thereby minimizing iatrogenic injury to the rest of the conjunctival surface. Besides the conventional de-epithelialized cryopreserved human amniotic membrane, the efficacy of freeze dried or lyophilized membranes have also been studied. Recurrence rate of pterygium with amniotic membrane use ranges from 12 to 40%.¹⁴

Cultivated Conjunctival Transplantation

A novel method of closing the surgical defect involves the use of an ex-vivo expanded conjunctival epithelial sheet on an amniotic membrane substrate. The efficacy of this approach was studied in the management of Pterygium surgery, comparing it to standard amniotic membrane transplantation, and a recurrence rate of 23 % was noted. Further studies are needed to evaluate the success of this approach in pterygium surgery.

Adjunctive Methods for Prevention of Recurrence Radiation

Radiation of the bare sclera with Strontium 90 is largely given up due to patients developing scleral necrosis at the site. It has been replaced by other safer adjuvants.

Mitomycin C (MMC)

The adjunctive use of Mitomycin C during pterygium surgery has been shown to decrease the recurrence rate. MMC is used in two forms, intra-operative application to the bare scleral bed and post operative drops. The reported recurrence rates associated with intraoperative mitomycin C use range from 10.5. to 38%. Increasing the duration of intra operative exposure to MMC reduces recurrences. Its use has been associated with serious sight-threatening complications such as infectious scleritis, severe secondary glaucoma, corneal edema, corneal perforation, corectopia, iritis, sudden onset mature cataract, scleral calcification and incapacitating photophobia and pain.

Corticosteroids

As inflammation is considered to be one of the risk factors for primary and recurrent pterygium, corticosteroids have a definite role to play. The postoperative use of subconjunctival triamcinolone seems to benefit patients having risk factors like conjunctival inflammation, hemorrhage, granuloma and fibrovascular proliferation by preventing recurrences. Post-operative topical corticosteroid eye drops also decrease the incidence of recurrences by reducing the inflammation.

Others

Daunorubicin, doxorubicin and 5-fluorouracil (5FU) have also been used as adjuvants to prevent recurrences and have shown promising results in some studies.

Other Advances for Ease of Surgery

Fibrin Glue

Fibrin glue has been used as an alternative to sutures for securing conjunctival grafts. The use of fibrin glue shortens operating times significantly, is associated with less post-operative discomfort with success rates that are comparable to sutured grafts.

Autologous Serum

Patients own blood is used as a bio adhesive in pterygium surgery and the recurrence rate was found to be similar to fibrin glue. It is more cost effective with no risk of transmission of infections. The drawback of this technique is that the complications regarding graft displacement and graft retraction are more common in patients with grafting with autologous blood than with the glue.

Complicated Cases and Approach to their Management

Lamellar Keratoplasty

Lamellar keratoplasty has been used to replace the thinning and corneal scarring seen after pterygium excision. This has mostly been used to treat recurrent pterygium to restore corneal thickness in thinned, scarred corneas or as-

sociated corneal opacity in the visual axis. The main limitations are the need for donor corneal tissue with the attendant risks of graft rejection and transmission of infection, as well as, the increased complexity of the procedure.

Combination of Approaches

In recurrent cases, amniotic membrane is used to cover the muscle to prevent fibrosis and restriction of movements while the conjunctival autograft is used to close the defect from the pterygium surgery.

Future Prospects Bevacizumab

Studies are underway to try Bevacizumab as an adjuvant in pterygium surgery to prevent recurrence.

Complications of Pterygium Surgery

Recurrence, Medial rectus damage, Graft dislodgment/Necrosis

Limbal deficiency at donor site, Corneal or scleral infection, Graft infection, Scleral necrosis, Dellen, Ocular perforation and retinal detachment, Endophthalmitis, Episcleral pyogenic granuloma.

No Financial & Competing Interest.

References:

1. Demartini DR, Vastine DW. Pterygium. Surgical interventions Corneal and External diseases. Orlando, USA: Grune and Stratton; 1987. P.141
2. Nangia V, Jonas JB, Nair D, Saini N, Nangia P, et al. (2013) Prevalence and Associated Factors for Pterygium in Rural Agrarian Central India. The Central India Eye and Medical Study. Plos ONE 8(12): e82439.
3. Moran DJ, Hollows FC. Pterygium and ultraviolet radiation: a positive correlation. British Journal of Ophthalmology 1984; 68: 343-6.
4. Gallagher MJ, Giannoudis A, Herrington CS, Hiscott P. Human papilloma virus in pterygium. British Journal of Ophthalmology 2001; 85:782-4.
5. Di Girolamo N, Chui j, Coroneo MT, Wakefield D. Pathogenesis of pterygia: role of cytokines, growth factors, and matrix metalloproteinases. Progress in Retinal and Eye Research 2004; 23:195-228.
6. Johnson RD, Pai VC, Hoft RH. Historical approaches to pterygium surgery, including bare sclera and adjunctive beta radiation techniques. In: Hovanesian JA, editor. Pterygium:
7. Tomas T. Sliding Flap of Conjunctival Limbus to Prevent Recurrence of Pterygium. Refractive Corneal Surgery 1992; 8:394-5.
8. Kenyon KR, Wagoner MD, Hettinger ME. Conjunctival Autograft Transplantation for Advanced And Recurrent Pterygium. Ophthalmology 1985; 92:1461-70.
9. Rao SK, Lekha T, Mukesh BN, Sitalakshmi G, Padmanabhan P. Conjunctival-Limbal autografts for primary and recurrent Pterygia: Technique and results. Indian Journal Ophthalmology 1998; 46:203-9.
10. Hirst L. W. Prospective Study of Primary Pterygium Surgery using Pterygium Extended Removal Followed by Extended Conjunctival Transplantation. Ophthalmology 2008; 115:1663-72.
11. Al-Fayez M-F. Limbal versus conjunctival autograft transplantation for advanced and recurrent pterygium. Ophthalmology 2002; 109:1752- 5.
12. Aliza Jap, Cordelia Chan, Li Lim, Donald T.H Tan. Conjunctival rotation autograft for pterygium: An alternative to conjunctival autografting. Ophthalmology: Journal of the AAO Volume 106, Issue 1, Pages 67-71, January 1,1999
13. Jap A, Chan C, Li L, et al. Conjunctival rotation autograft for pterygium. Ophthalmology 1999; 106:67-71.
14. Arain MA, Yaqub MA, Ameen SS, Iqbal Z, Naqvi AH, Niazi MK. Amniotic membrane transplantation in primary pterygium compared with bare sclera technique. Journal of College of Physicians and Surgeons Pakistan. 2012; 22:440-3.