



DIRECT MAXILLARY SINUS LIFT WITH SIMULTANEOUS IMPLANT PLACEMENT: A CLINICAL AND RADIOLOGICAL EVALUATION

Mohinder Panwar	Professor, Division of Periodontology, Dept Of Dental Surgery & Oral Health Sciences, AFMC, Pune
Dushyant Malik	PG Resident, Division of Periodontology, Dept Of Dental Surgery & Oral Health Sciences, AFMC, Pune
Manab Kosala	Associate Professor, Division of Periodontology, Dept Of Dental Surgery & Oral Health Sciences, AFMC, Pune
Jacqueline Jacinta Dias*	PG Resident, Division of Periodontology, Dept Of Dental Surgery & Oral Health Sciences, AFMC, Pune *Corresponding Author

ABSTRACT Maxillary sinus pneumatization along with resorption of the alveolar bone result in reduced height of residual alveolar bone. Various methodologies have been introduced to elevate the sinus membrane. Direct and indirect sinus lift procedures aid in lifting the sinus membrane, permitting implant placement. This case report discusses one such case of reduced deficient alveolar bone height which was managed by direct sinus elevation for placement of implant

KEYWORDS : sinus lift, implant, piezosurgery

INTRODUCTION

Tooth loss is followed by accentuated resorption of alveolar bone, leading to alveolar ridge deficiency in both horizontal and vertical direction. Loss of tooth results in decrease in alveolar bone height and bone density, resulting in ridge deficiency.

Maxillary sinus pneumatization is the result of progressive hollowing of alveolar process on apical aspect. This is result of osteoclast mediated resorption due to absence of bone stimulation and increase in positive antral pressure. In such a situation there is decent of sinus floor reducing the residual alveolar bone height. This makes conventional implant placement difficult.

Maxilla is made up of spongy bone and is less dense when compared to mandible. Poor quality of residual bone along with maxillary sinus pneumatization poses challenges towards success of implant in maxillary region.

To adapt and evade the above limitation, sinus elevation procedure has become an essential part in implant therapy. Maxillary sinus elevation was first described by Tatum and later modified by Boyne and James. Various different methodologies have evolved since then. While some procedures involve minimal elevation of maxillary sinus, other procedures involve use of various types of grafts such as allografts, xenografts etc.

There are mainly two ways of sinus elevation- Direct sinus lift and Indirect sinus lift technique. Both the methods have delineated indications and contra indications. Direct sinus lift procedure involves elevating the Schneiderian membrane through a lateral window to create sufficient vertical space for bone augmentation. Indirect sinus lift involves the maxillary sinus to be accessed through the alveolar crest.

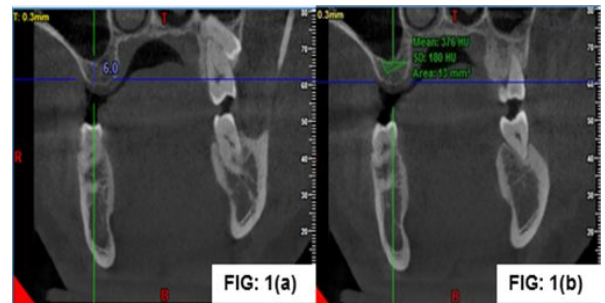
This article describes a case of deficient residual ridge height managed by sinus lift procedure along with use of bone grafts.

CASE REPORT

A 38-year-old male patient, businessman by profession, presented with the chief complaint of missing upper right posterior teeth and finding difficulty in chewing. History revealed that tooth was extracted due to caries three and half years back, which was uneventful. His medical history was non-contributory with no signs or symptoms of systemic illness. On intra oral clinical examination patient was having good oral hygiene with edentulous 16 having thick tissue biotype.

The Cone Beam Computed Tomography (CBCT) finding showed that the available sub-antral bone was insufficient in height ie 6mm and 8.4mm bucco-palatally [Fig 1(a)] and also the residual bone density as

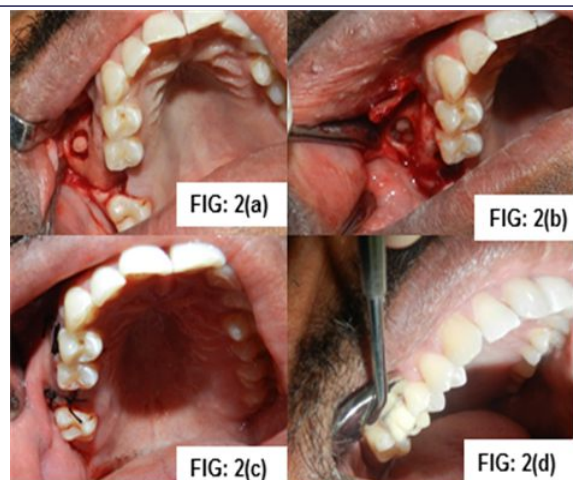
376 HU [Fig 1(b)]. Routine blood investigations were done which came out to be within normal limit. Alginate impression was recorded and pre-surgical casts were prepared, interocclusal as well as interdental distance was measured. After correlating clinical and radiographic findings treatment plan was discussed with the patient and was planned for sinus augmentation with lateral window approach in relation to edentulous 16.



Surgical procedure

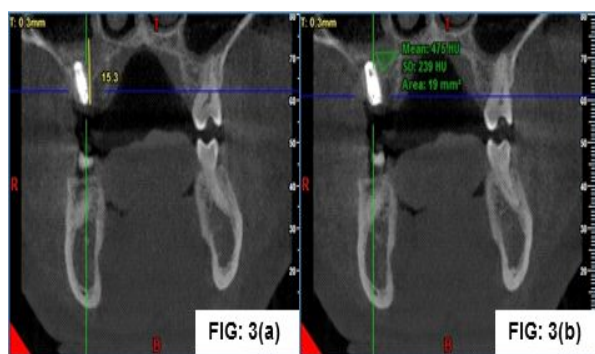
The maxillary posterior segment was anaesthetised with buccal and palatal infiltration using local anaesthesia of 2% lignocaine with 1:80,000 adrenaline. A full thickness buccal flap was raised until the zygomatic buttress. A bony window was then traced using a Piezosurgical unit. The initial bone marking was done. This was followed by the deepening of the mark. The bone tracing was made until a very thin plate of buccal bone remained over the sinus lining [Fig 2(a)].

Then the section was fractured using direct sinus lift elevators. The fractured section of bone was kept attached to the antral lining and no attempt was made to separate it from the lining. The detached "window" was elevated medially and apically while simultaneously reflecting the sinus membrane with the help of elevators [Fig 2(b)]. Following adequate reflection, the sinus membrane was inspected for tears. The augmentation procedure was completed with calcium phosphosilicate bone substitute (nova bone putty) as graft material and the implant (Equinox myriad plus 4.5 × 11mm) was simultaneously placed. The remaining sub-antral space after implant placement was then filled with the graft material [Fig 2(c)]. Flap was stabilized and sutured with biotech collagen membrane. Patient was given postoperative antibiotic and anti-inflammatory coverage. After postoperative instructions were given, the patient was recalled after 10 days for re-evaluation and suture removal. Patient was followed up after period of 6 months for rehabilitation. Healing abutment was placed and after a period of ten days cemented retained prosthesis was given [Fig 2(d)].



RESULT

In the present intervention, the height of the alveolar process in the intended implant site was 6mm. Implant analyzed was installed in site simultaneously with sinus lift. Post-operative sub-antral bone height along with implant placement came out to be 15.3mm [Fig 3(a)]. Gain in height of sub-antral bone after a duration of 6 months was 9.3mm. Also the bone density after remodeling of the grafted site came out to be 475HU [Fig 3(b)], in comparison of residual bone density 376HU (pre operatively). So the gain in residual bone density was 99HU.



DISCUSSION

In posterior maxilla, sinus floor augmentation is an established protocol for increasing the bone volume. In the present case report on the radiographic examination by Cone beam computed tomography (CBCT), the available bone height in the molar region was found to be only 6mm from the maxillary sinus lining. Reason for the same was the missing molars since long so there were atrophic changes of the edentulous area. Also due to increase of pneumatization of antrum there was continuous loss of bone height as well as density (5). Decision of procedure was made by the pre existing tooth form and position, its relation with the opposing arch, soft tissue as well as maxillary sinus anatomy and bone dimension. Clinical studies in relation to dental implants placed into the augmented sinus with graft demonstrate a similar or even higher survival rate than for implant placed without sinus lift procedure(6).

Old modality of lifting sinus membrane had a greater percentage of perforating 'Schneiderian membrane'. Sinus lining perforation may occur either during preparing window or while separating the sinus membrane during osteotomy using surgical bur (7). 'Piezosurgical technique' is the new advancement for overcoming these draw backs with minimal postoperative complications. Also the histomorphological studies done in recent past shows that there is an increase in concentration of Bone morphogenic protein(BMP-4), transforming growth factor- β , tumor necrosis factor- α and Interleukin -1,10 and there is also a decrease in some pro-inflammatory cytokines in bone(8). Also there are fewer chances of necrotic changes in relation to bone modification procedures by using piezo surgical technique so the regeneration process is at an accelerated rate. Piezo surgical procedure also have an additive advantage that they are designed for activation in contact of mineralized tissue and becomes inactive while coming in contact of soft tissue reducing the chances of damaging the

sinus lining(9). Once the access through bony window is prepared, widening of osteotomy is done protecting the sinus lining; also the window trephined autogenous bone is used for vertical augmentation of sinus floor. Although the potential of bone formation in sinus without the use of bone substitutes has been proposed but the results remain controversial and also the stability of the blood clot with sinus lifting is questionable. Despite the ability of osteogenesis of autografts, resorbable bone grafts may also be suitable in sinus augmentation procedures for dimension maintenance. Therefore, different types of bone replacement grafts can be used in sinus augmentation procedures.

The graft material used in the present study is calcium phosphosilicate putty. A significant difference in the density of new bone formed (at the end of 6 months) in comparison to the residual bone was noted. It was observed that the bone formed 6 months post op was denser than the residual bone pre treatment. Nova Bone's graft substitute is engineered to accelerate the body's natural healing process with a measured release of ions and changes in surface chemistry that supercharge cellular activity with preferential development of cells that form new bone. The term osteostimulation is used to define this unique process (10).

CONCLUSION

The success of the dental implant placement with sinus augmentation is a technique sensitive procedure and depends on the skill of the operator, adequate preoperative planning, technique used and the type of graft material used.

Implant placement in maxillary posterior region is complicated especially in cases of long edentulous span due to inadequate bone density and height. The case was challenging because of ridge resorption, with reduced vertical bone height and pneumatization of the maxillary sinus. So piezo-surgical technique for intervention which is a comparatively a safer approach to the maxillary sinus was tried, allowing sinus membrane integrity to be maintained. Also bone graft material (novabone putty) used for augmentation presented a remarkable difference in the bone fill after a duration of six months.

As observed in this case, the bone density of the bone formed was much higher than the residual bone height. However further radiological and histological studies are required to substantiate the use of different types of grafts in such procedures.

REFERENCES

1. Raja SV. Management of the posterior maxilla with sinus lift : Review of techniques. *J Oral Maxillofac Surg* 2009;67:1730-4.
2. Alberti PW. Applied surgical anatomy of the maxillary sinus. *Otolaryngol Clin North Am* 1976;9:3-20.
3. Boyne PJ, James RA. Grafting of the maxillary sinus floor with autogenous marrow and bone. *J Oral Surg* 1980;38:613-616.
4. Misch C. Maxillary sinus augmentation for endosteal implants: Organized alternative treatment plans. *Int J Oral Implantol* 1987;4:49-57.
5. Garg AK. Augmentation grafting of the maxillary sinus for the placement of dental implants: Anatomy, physiology and procedure. *Implant Dent*. 1994;8:36-46.
6. Jensen OT, Shulman LB, Block MS, Iacono VJ. Report of the sinus consensus conference of 1996. *Int J Oral Maxillofac Implants*. 1998;13:11-45.
7. Schlee M, Steigmann M, Bratu E, Garg AK. Piezosurgery: basics and possibilities. *Implant Dent*. 2006;1:334-40.
8. Vercelotti T, Nevins ML, Kim DM, Wada K, Schenk RK, Fiorellini JP. Osseous response following resective therapy with piezosurgery. *Int J Perio Rest Dent*. 2005;25:543-49.
9. Heinemann F, Hasan I, Kunert-Keil C, Götz W, Gedrange T, Spassov A, et al. Experimental and histological investigations of the bone using two different oscillating osteotomy techniques compared with conventional rotary osteotomy. *Ann Anat*. 2012;194:165-70.
10. Kotsais GA, Salama M, Chrepa V, Hinrichs J, Gaillard P. A randomized blinded controlled clinical study of particulate anorganic bovine bone mineral and calcium phosphosilicate putty bone substitutes for alveolar ridge preservation. *Int J Oral Maxillofac Implants*. 2014 Jan-Feb;29(1):141-51.