



## A STUDY OF ORIGIN, COURSE AND VARIATIONS OF INFERIOR MESENTERIC ARTERY AND ITS BRANCHES

Deepa S

Senior Resident, Department of Anatomy, Government medical college Calicut, Kerala 673008

Ashalatha P R

Additional professor, Department of Anatomy, Government medical college, Calicut, Kerala 673008

**ABSTRACT** Knowledge of inferior mesenteric arteries is essential for surgical and radiological procedures.

**AIM:** To study the origin, course, branches and variations of inferior mesenteric arteries.

**MATERIALS AND METHODS:** 50 human cadavers by dissection method.

**RESULT:** Inferior mesenteric artery arose from aorta in all 50 cases. Left colic artery arose either directly from IMA or as sigmoid trunk in common with LCA or separately from IMA

**KEYWORDS :** superior mesenteric artery, inferior mesenteric artery, aorta.

### INTRODUCTION

The mesenteric arterial supply is a combination of rich collateral networks and commonly encountered variant anatomy. The effect of normal and variant anatomy has implications on pathology, treatment choices, and planning interventions. A review of anatomic variants will assist in understanding the implications of abnormal anatomy on treatment for diseases associated with the mesentery.

Differences arising during several developmental stages in the embryonal process lead to a range of variations in these vascular structures.

### Inferior Mesenteric Artery

The inferior mesenteric artery is responsible for supplying blood to the distal third of the transverse colon, descending colon, sigmoid colon, as well as the upper rectum – the structures derived from hindgut. Hence it is referred as the artery of the hindgut. It originates in an antero-lateral orientation to the left just above the aortic bifurcation, typically between the L2 and L4 vertebral bodies. It travels in a retroperitoneal plane towards the sigmoid colon. Branches include:

1. Left colic artery
2. Sigmoid arteries
3. Superior rectal artery

The left colic artery is comprised of an ascending and descending branch. The ascending collateralizes to the middle colic artery, at the distal transverse colon, and splenic flexure (Griffith's point). This collateralization is important, as this area is at high risk for watershed ischemia in the setting of dehydration or mesenteric occlusive disease. The descending left colic artery branch collateralizes to the sigmoid arteries. These are comprised of two or three sigmoid artery branches within the mesocolon. The uppermost sigmoid artery collateralizes to the left colic artery, whereas the lowermost collateralizes to the superior rectal artery. The superior rectal artery descends into the pelvis dividing into right and left branches. The superior rectal artery collateralizes with both the middle rectal (branch of the internal iliac artery) and the inferior rectal artery (branch of the internal pudendal artery).

The anatomy of the communicating arteries between superior and inferior mesenteric is essential during oncological abdominal surgeries to avoid colonic necrosis and for successful vascular anastomosis.

### AIM AND OBJECTIVES

#### AIM

The aim of the study is to determine the origin, course, branches and the variations of inferior mesenteric artery by dissection method in human cadavers.

#### OBJECTIVES

1. Distance between origin of superior and inferior mesenteric artery
2. Branches of inferior mesenteric artery

3. Variations in the branching pattern
4. Presence of any uncommon branches

### MATERIALS AND METHODS

The material examined consisted of 50 formalin fixed cadavers obtained from the Department of Anatomy, Government Medical College, Kozhikode. The abdomen was opened by roof top incision. The mesentery of the small intestine in the infracolic compartment was exposed by turning the transverse colon and its mesentery upwards. The oblique attachment of the mesentery of the small intestine on the posterior abdominal wall was traced.

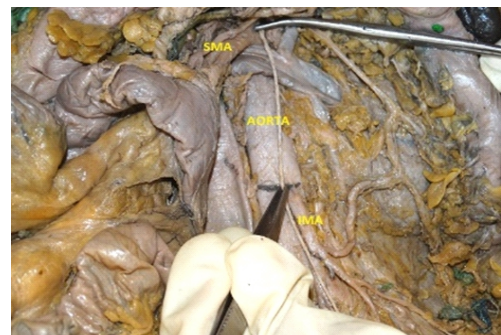
The small intestine mesentery was turned to the right. The peritoneum and fat on the posterior abdominal wall between the mesentery and the descending colon was removed to expose the inferior mesenteric artery. The branches of inferior mesenteric artery were traced<sup>1</sup>.

Photographs were taken to document the variations. The results obtained were then tabulated.

### Results

#### Inferior mesenteric artery

Inferior mesenteric artery is the third ventral branch of abdominal aorta. In all 50 cadavers the artery was identified. In all the cadavers the artery arose from the aorta below the superior mesenteric artery and no abnormal site of origin was found. The distance between the origin of SMA and IMA was measured (fig:1).



**FIG. 1: Measuring the distance between SMA and IMA**

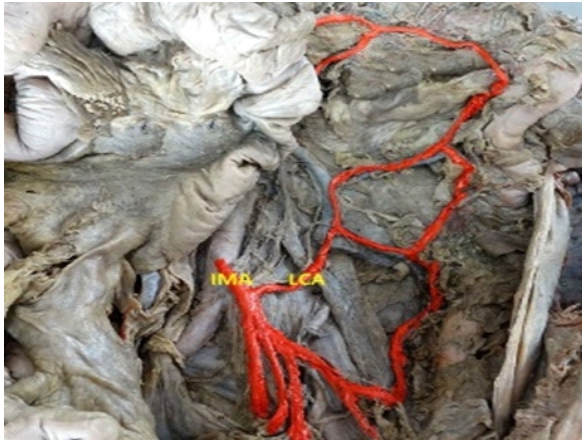In 2 cadavers the distance was between 4 to 4.9cms, in 7 cadavers it was 5 to 5.9cms, in 11 cadavers it was 6 to 6.9cms, in 21 cadavers it was 7 to 7.9cms, in 5 cadavers it was 8 to 8.9cms and in 4 cadavers it was 9cms. The mean was 6.87cms.

From the chart it is clear that the most frequent distance of IMA from SMA is between 7 and 7.9cms and the least is 4 to 4.9cms.

#### Branches of inferior mesenteric artery

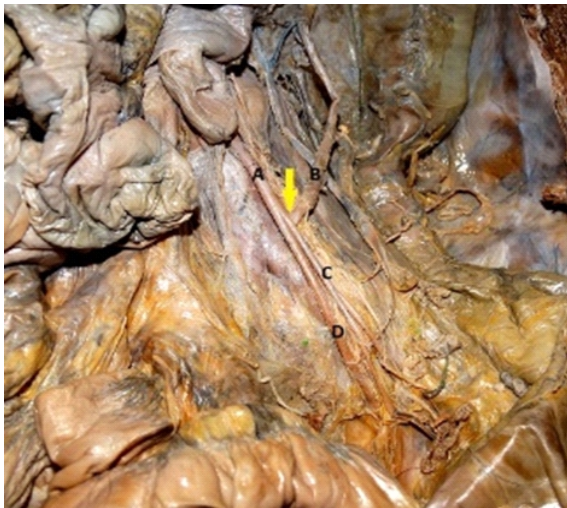The inferior mesenteric artery gives off three branches – left colic

artery, sigmoid arteries and superior rectal artery which is a downward continuation of inferior mesenteric artery. In the present study the left colic artery arose from the inferior mesenteric artery in all the 50 cadavers and divided into ascending and descending branches (fig:2).

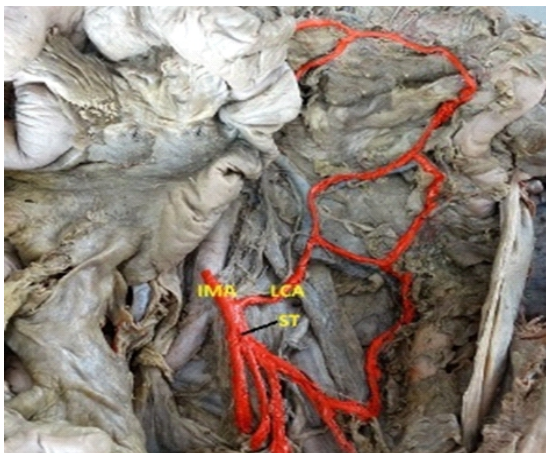

**FIG. 2: Left colic artery (LCA) arising from IMA**

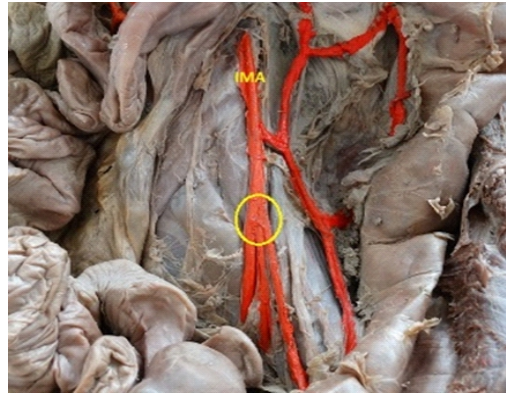
The sigmoid arteries also were present in all the 50 cadavers. The number of sigmoid arteries varied from 2 to 3. The origin of sigmoid arteries was as follows- a single trunk arising from IMA as sigmoid trunk and dividing into 2 or 3 branches (fig:4) or sigmoid trunk arising in common with left colic artery (fig:3) or 2 or 3 sigmoid arteries from IMA directly (fig:5).



**FIG.3: Yellow arrow – LCA and sigmoid trunk shows common origin (A – IMA, B – LCA, C – sigmoid trunk, D – superior rectal artery)**



**FIG.4: LCA and sigmoid trunk arising separately**



**FIG.5: yellow circle shows sigmoid arteries arising from IMA**

Predescu<sup>2</sup> et al (2013) systematized the inferior mesenteric artery based on their left colon arteriographic study as follows

Type I - distribution through two IMA terminal branches, just one left colic a. and the recto-sigmoid trunk

Type II - three split of the IMA (Debieerre's trident):

- a) Three branches of the IMA, namely the left colic a.(LCA), the sigmoid trunk, superior rectal a. (Sra);
- b) One trunk from which all three arteries split as a trident
- c) A colic trunk from which the LCa detaches and eventually the medium left colic a. (MLCa) as well, or the inferior left colic a. (ILCa), and the sigmoid a. and the SRA are separate branches,
- d) A trunk that splits in two forming the LCa and the sigmoid artery (colo-sigmoid trunk) and the SRA is a separate branch

Based on this study the inferior mesenteric arteries of the present study were also systematized as follows in table 1.

IMA	No. of cadavers	Percentage
Type I	0	0
Type II a	23	46%
Type II b	12	24%
Type II c	0	0
Type II d	15	30%
Total	50	100%

Thus type II a is found to be more common in the present study, while there were no cadavers that could be categorized under type I and type II c.

**DISCUSSION**

**Inferior mesenteric artery**

The distance between the origin of inferior mesenteric artery and superior mesenteric artery was measured and compared with the values of the other studies. (Table 2)

Study (year)	Distance between SMA & IMA	Range
Ahmet Songur <sup>3</sup> (2010)	57.76±8.04 mm	5 – 10 cm
Rekha Mane <sup>4</sup> (2015)	6.6 cm	4.2 – 10.3 cm
George R <sup>5</sup> (1935)	7.1 cm	4.2 – 10.3 cm
Simeon Sinkeet <sup>6</sup> (2013)	6.09±1.46 cm	1.2 – 8.4 cm
Present study (2015)	6.87 cm	4.5 – 9.5 cm

The comparison of the values obtained from the present study along with the values cited by other studies show that the mean distance is almost close to all the studies cited above. The range obtained also coincides well with that of the other studies.

**Branches**

The branches of the inferior mesenteric artery – left colic, sigmoid and superior mesenteric arteries were present in almost all the cases. There was only variation in the arrangement of the sigmoid arteries. Either they arose directly from the inferior mesenteric artery or from a common sigmoid trunk which took its origin from IMA.

Sigmoid arteries arising directly from IMA is said to be the classical branching pattern. This pattern was noted only in 4% of the cases in the present study. Simeon Sinkeet<sup>6</sup> (2013) reported an incidence of 12% of the classical pattern.

Sigmoid arteries branching off from a sigmoid trunk was noted in 96% of the cases. Either the sigmoid trunk branched off separately from IMA (66%) or along with left colic artery (30%).

Categorizing the findings of inferior mesenteric artery based on the systematization of D.Predescu<sup>2</sup> et al (2013) it was found that in the present study type IIa was most common (46%) which is not the same as the study of D. Predescu<sup>2</sup> (2013). Type IIc is the most common variety (70%) found in their study.

Manoharan<sup>7</sup> et al (2010) presented a case of LCA arising from celiac trunk.

Katagiri H<sup>8</sup> et al (2007) reported case of LCA arising from SMA.

Ronald A Bergman<sup>9</sup> also reported case of LCA from SMA.

Rekha Mane<sup>4</sup> et al (2015) says LCA was absent in 2% of the cases.

None of these variations were observed in the present study.

### Conclusion

The present study was conducted in the department of Anatomy, Government Medical College, Kozhikode, Kerala. A total of 50 adult cadavers were dissected to study the origin, course and branches of SMA and IMA and the variations were noted. The findings of the study can be summarized as follows:

1. Inferior mesenteric artery arose from aorta in all 50 cases.
2. Left colic artery arose from IMA in all 50 cases.
3. Sigmoid arteries arose either directly from IMA or as sigmoid trunk in common with LCA or separately from IMA.

Keeping in mind such possible variations the surgeons should be careful during the surgeries of liver transplant and colonic surgeries. In cases where the marginal artery is not continuous the arterial ligation in colon surgeries may lead to ischemia. So an arteriogram is a must before doing surgeries to avoid complications.

### References:

1. Romanes GJ. The abdominal cavity. Cunningham's Manual of Practical Anatomy. Thorax and Abdomen, 15th Ed. London, Oxford University Press, 1986;135-138.
2. D. Predescu, B. Popa, M. Gheorghe, I. Predescu, G. Jinescu, M. Boeriu, S. Constantinoiu The Vascularization Pattern of the Colon and Surgical Decision in Esophageal Reconstruction with Colon. A Selective SMA and IMA Arteriographic Study *Chirurgia* (2013) 108: 161-171 No. 2, March - April
3. Ahmet Songür, Muhsin Toktaş, Ozan Alkoç, Tolgahan Acar, İbrahim Uzun, Orhan Baş, Oğuz Aslan Özen. Abdominal Aorta and Its Branches: Morphometry - Variations in Autopsy Cases. *Eur J Gen Med* 2010;7(3):321-325
4. Rekha Mane, Charushila D. Shinde. Morphometric study of Inferior Mesenteric Artery & its Branches. *Indian Journal of Applied Research*. Volume : 5 Issue :4 April 2015 ISSN - 2249-555X
5. George R. Topography of the Unpaired Visceral Branches of the Abdominal Aorta. *J Anat.* 1935 Jan;69(Pt 2):196-205 cited by Rekha Mane, Charushila D. Shinde. Morphometric study of Inferior Mesenteric Artery & its Branches. *Indian Journal of Applied Research*. Volume : 5 Issue :4 April 2015 ISSN - 2249-555X
6. Simeon Sinkeet, Philip Mwachaka, Johnstone Muthoka, and Hassan Saidi. Branching pattern of Inferior Mesenteric Artery in Black African Population: A Dissection Study. *ISRN Anatomy* Volume 2013, Article ID 962904.
7. Manoharan B, Aland RC. Atypical coeliomesenteric anastomosis: The presence of an anomalous fourth coeliac trunk branch. *Clin Anat.* 2010 Nov;23(8):9046. doi: 10.1002/ca.21024.
8. Katagiri H, Ichimura K, Sakai T. A case of celiacomesenteric trunk with some other arterial anomalies in a Japanese woman. *AnatSci Int.* 2007 Mar;2(1):53-8
9. Ronald A. Bergman, Adel K. Affi, Ryosuke Miyaguchi, Illustrated encyclopedia of Human anatomic Variation: Opus 11; Cardiovascular system; Arteries; Abdomen cited by N. B. S. Parimala Multiple Accessory Middle Colic Arteries – A Rare Case Report. *Int J Med Health Sci.* April 2013, Vol-2; Issue-2