



EPIDERMOID CYST – CASE REPORT AND REVIEW OF LITERATURE

KEYWORDS

Epidermoid cyst, swelling, congenital

Dr. Kshitija Kale

Reader, Department Of Oral Medicine and Radiology
NH-216, Chaitanya Health City, East Godavari District,
Amalapuram 533201, Andra Pradesh, India

Dr. Asha Iyengar

Professor and HOD, Oral Medicine and Radiology,
DAPMRVDC, Bangalore

ABSTRACT

Epidermoid cysts are rare, slow-growing, benign, developmental cysts that are derived from abnormally situated ectodermal tissue. Dermoid and epidermoid cysts in the oral cavity are uncommon and account for less than 0.01% of all oral cysts (Rajayogeswaran & Eveson, 1989), (Worley & Laskin, 1993). Many of them occur in the floor of the mouth, but there are rare and usually individual case reports of examples in other sites.

These cysts may remain asymptomatic for years or there may just be a cystic swelling. These cysts might enlarge until they reach a size that causes functional problems, such as difficulties with deglutition, speech and respiration. However, they also can become acutely symptomatic if they are secondarily infected (Lian Timothy, 2005).

The present article describes a case report and brief overview of epidermoid cyst.

INTRODUCTION

Epidermoid cysts are closed sacs with a definite wall that results from proliferation of surface epidermal cells. Production of keratin and lack of communication with the surface are responsible for cyst formation (Kuniyuki, Yoshida, Maekawa, & Yamanaka, 2008).

It is suggested that epidermoid cysts are derived from epithelial remains from the closure process of the first and second branchial arches (Worley & Laskin, 1993).

CASE REPORT

A 19 year old male patient reported to the Department of Oral Medicine and Radiology at DAPM R V Dental College with a chief complaint of swelling with respect to left side of the face since 8 months (Figure 1). The swelling was insidious in onset and progressive in nature and had progressive to the present size. Patient used to manipulate the swelling with the fingers when the swelling was very small and suggests that it might have led to increase in the size of the swelling. No pain or any other associated symptoms were present. No treatment was taken for the same.

On extraoral examination, there was a diffuse swelling on the left side of the face 3 cm posterior to the angle of the mouth measuring about 1 cm * 1 cm on the line joining the tragus and the angle of the mouth. The skin over the swelling was stretched. There was no change in the colour and texture of the skin over the swelling and no discharge or sinus were present. Surrounding mucosa appeared normal. On palpation, swelling was well defined, non-tender, firm and doughy in consistency and not related to the left masseter muscle.

On intraoral examination, slight, diffuse, roughly spherical swelling on the left buccal mucosa was palpable measuring about 1 cm*1 cm along the plane of occlusion. The mucosa over the swelling appeared normal. No discharge, bleeding was evident. There was no change in the salivary pooling, or salivary discharge.

Ultrasonography of the swelling revealed a well-defined thick walled cystic lesion measuring 16 x 12 mm in the plane of left cheek. Also, echogenic sediments were noted within and there was no evidence of calcification.

Fine needle aspiration cytology (FNAC) yielded very scanty turbid brown fluid which on microscopic examination revealed epithelial squames and very few epithelial cells.

Finally, excisional biopsy was done and the histopathological picture

revealed a cyst lined by stratified squamous epithelium (epidermis like) with no evidence of adnexal structures, and cystic lumen showed a laminar arrangement of keratin flakes with numerous adipocytes in delicate collagenous stroma. These features were suggestive of epidermal cyst. (Figure 2, Figure 3)

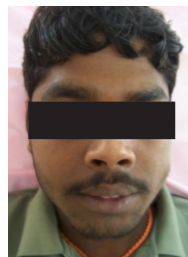

Figure 1

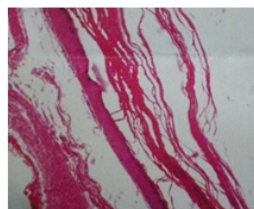


Figure 2

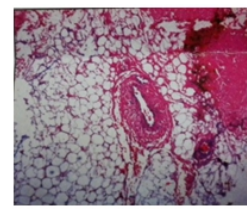


Figure 3

DISCUSSION

Epidermoid, dermoid, and teratoid cysts are nonodontogenic cystic lesions (Naik & Prusty, 2014). They are rare lesions derived from germinal epithelium.

Dermoid cysts can be found anywhere in the body, especially in the areas where embryonic elements fuse together. Dermoid cysts constitute 1.6% to 6.9% of all cysts in the head and neck area. Histologically, they can be further classified as epidermoid (lined with simple squamous epithelium), dermoid (when skin adnexa are found in the cyst wall) or teratoid (when other tissues, such as muscle, cartilage and bone are present) (De Ponte, Brunelli, Marchetti, & Bottini, 2002).

Epidermoid cyst is a congenital cyst that may appear due to trapping of ectoderm at the time of fusion of neural tube or other epithelial linings. They may also be secondary or acquired due to inclusion of epidermal elements into dermis posttraumatically or iatrogenically

in which case the term epidermal inclusion cyst may be preferred (Abhishek, Arpit, Jyoti, & Abhijit, 2010).

Epidermoid cysts may be found in any age group but are more common between 10 and 35 years of age with no gender predilection, while others have found predominance of women (Koca, Seckin, Sipahi, & Kazanc, 2007). However, Longo and others (Longo, Maremonti, Mangone, De Maria, & Califano, 2003) found that men are affected more often than women in the ratio 3:1, with mean age 28 years.

Epidermoid and dermoid cysts represent less than 0.01% of all oral cavity cysts (Kandogan, Koç, Vardar, Selek, & Sezgin, 2007). Epidermoid cysts have been described in various parts of the body, out of them only 1.6% are found in the oral cavity (Turetschek, Hospodka, & Steiner, 1995).

In a study, out of 1007 tumors of the head and neck area in children, 95 (9.4%) were dermoid cysts and only 3 (0.3%) occurred in the floor of the mouth. In another study, of a total of 541 evident dermoid cysts of the body, 184 (34%) occurred in the head and neck and 35 (6.5%) of these in the floor of the mouth (Taylor, Erich, & Dockerty, 1966).

Although floor of the mouth in the midline is the most favoured site, an occasional occurrence involving the buccal mucosa, tongue, lips, uvula, temporomandibular joint dermal graft, intradiploic, intracranial, and intraosseous location within the mandible and maxilla also have been cited in the literature (Shear & Speight, 2007). Clinically, these lesions are characterized by the slow growth of a normal- or yellow-reddish-coloured painless swelling with soft consistency on palpation. The diameter can vary from a few millimetres to even 10 centimetres (Laskaris, 2000).

Epidermal cysts can become infected, and when an abscess develops they may need to be surgically drained, followed by administration of systemic antibiotics (Kuniyuki, Yoshida, Maekawa & Yamanaka, 2008).

The epidermoid cyst rarely discloses malignancy (Ozan, Polat, Ay & Goze, 2007). The occurrence of Basal cell carcinoma, Bowen disease, and Squamous cell carcinoma has been reported in the literature that had evolved from epidermoid cyst (Rajendran & Sivapatha sundharam, 2007). An article (Ikeda & Ono, 1990) presented a case stating that basal cell carcinoma originates from an epidermoid cyst in which nests of basal cell carcinoma connected with the epidermoid cyst and partially replaced the cyst wall. Another report (López-Ríos, Rodríguez-Peralto, Castaño & Benito, 1999) described a case in which squamous cell carcinoma had developed in the wall of conventional epidermoid cyst.

An incorrect diagnosis could result in inappropriate therapy and if the lesion is completely excised, the treatment is definitive (Ozan, Polat, Ay & Goze, 2007). Multiple epidermoid cysts may be part of Gardner syndrome (Leppard & Bussey, 1975).

The differential diagnosis should include various conditions such as developmental, neoplastic and infectious processes. Infectious processes like swellings on the face which are commonly odontogenic in origin, buccal space infections and masseteric space infections were ruled out in our case as the associated clinical symptoms were absent. Neoplastic conditions were also excluded due to the benign appearance of the lesion and lack of nodal involvement. Other benign swellings to be considered are: lipoid, salivary, and vascular lesions. Comprehensive physical examination and results of investigative procedures like FNAC and ultra sonography were important to rule out these conditions.

Surgical excision is the treatment of choice and may be performed under local anaesthesia through intraoral access, with no recurrence expected (Bruno, Gabriela, Andre, & Cassio, 2007).

CONCLUSION

This case of epidermoid cyst was successfully diagnosed and managed by surgical excision. However, ample understanding and vigilance about this slow growing mass is essential not only because of the symptoms it produces but also due to rare occurrence of malignancy. Surgical excision is the treatment of choice and may be performed under local anaesthesia through intraoral access, with no recurrence expected.

REFERENCES

1. Rajayogeswaran, V., & Eveson, J. W. (1989). Epidermoid cyst of the buccal mucosa. Oral surgery, oral medicine, oral pathology, 67(2), 181-184.
2. Worley, C. M., & Laskin, D. M. (1993). Coincidental sublingual and submental epidermoid cysts. Journal of oral and maxillofacial surgery, 51(7), 787-790.
3. Lian Timothy S. (2005). Benign tumours and tumour like lesions of the oral cavity. In: Cummings Otolaryngology and Head and Neck Surgery. 4th ed. St Louis: Elsevier Mosby Year Book, 2:1571-1577.
4. Kuniyuki, S., Yoshida, Y., Maekawa, N., & Yamanaka, K. (2008). Bacteriological study of epidermal cysts. Acta dermatovenereologica, 88(1), 23-25.
5. Naik C, Prusty N (2014). Epidermoid Cyst of Tongue A Case Presentation. Int J Otorhinolaryngol Clin, 6(3):134-136.
6. De Ponte, F. S., Brunelli, A., Marchetti, E., & Bottini, D. J. (2002). Sublingual epidermoid cyst. Journal of Craniofacial Surgery, 13(2), 308-310.
7. Abhishek, V., Arpit, S., Jyoti, D., & Abhijit, R. (2010). An unusual case of epidermal inclusion cyst of maxilla. International Journal of Head and Neck Surgery Jan-April, 1(1), 43-47.
8. Koca, H., Seckin, T., Sipahi, A., & Kazanc, A. (2007). Epidermoid cyst in the floor of the mouth: report of a case. Quintessence International, 38(6).
9. Longo, F., Maremonti, P., Mangone, G. M., De Maria, G., & Califano, L. (2003). Midline (dermoid) cysts of the floor of the mouth: report of 16 cases and review of surgical techniques. Plastic and Reconstructive Surgery, 112(6), 1560-1565.
10. Kandogan, T., Koç, M., Vardar, E., Selek, E., & Sezgin, Ö. (2007). Sublingual epidermoid cyst: a case report. Journal of medical case reports, 1(1), 87.
11. Turetschek, K., Hospodka, H., & Steiner, E. (1995). Epidermoid cyst of the floor of the mouth: diagnostic imaging by sonography, computed tomography and magnetic resonance imaging. The British journal of radiology, 68(806), 205-207.
12. Taylor, B. W., Erich, J. B., & Dockerty, M. B. (1966). Dermoids of the head and neck. Minnesota medicine, 49(10), 1535.
13. Shear, M., & Speight, P. (2007). Odontogenic keratocyst. Cysts of the Oral and Maxillofacial Regions, Fourth Edition, 6-58.
14. Laskaris, G. (2000). Atlas colorido de doenças bucais da infância e da adolescência. Santos.
15. Ozan, F., Polat, H. B., Ay, S., & Goze, F. (2007). Epidermoid cyst of the buccal mucosa: a case report. J Contemp Dent Pract, 8(3), 90-96.
16. Rajendran R, Sivapathasundharam B, editors (2007). Disturbances of development and growth. Shafer's Textbook of Oral Pathology, 6th ed. Elsevier, 67-70.
17. Ikeda, I., & Ono, T. (1990). Basal cell carcinoma originating from an epidermoid cyst. The Journal of dermatology, 17(10), 643-646.
18. López-Ríos, F., Rodríguez-Peralto, J. L., Castaño, E., & Benito, A. (1999). Squamous cell carcinoma arising in a cutaneous epidermal cyst: case report and literature review. The American journal of dermatopathology, 21(2), 174-177.
19. Leppard, B., & Bussey, H. J. R. (1975). Epidermoid cysts, polyposis coli and Gardner's syndrome. British Journal of Surgery, 62(5), 387-393.
20. Jham, B. C., Duraes, G. V., Jham, A. C., & Santos, C. R. (2007). Epidermoid cyst of the floor of the mouth: a case report. Journal-Canadian Dental Association, 73(6), 525.