



## Giant protruding hepatic hemangioma in an adult – An accidental finding in a patient of cerebro-vascular accident who was on Aspirin for many years.

### KEYWORDS

#### Dr. Gogate Bageshri

P, MD, Professor, Department of Pathology, Smt. Kashibai Navale Medical College & General Hospital, Narhe, Off Pune-Mumbai Bypass, Pune-411041, Maharashtra, India

#### Dr. Yash Nene

MBBS, Smt. Kashibai Navale Medical College & General Hospital, Narhe, Off Pune-Mumbai Bypass, Pune-411041, Maharashtra, India - Corresponding Author

#### Dr. Parth Sampat

MBBS, Smt. Kashibai Navale Medical College & General Hospital, Narhe, Off Pune-Mumbai Bypass, Pune-411041, Maharashtra, India

#### Dr. Pradny Naik

MBBS, Smt. Kashibai Navale Medical College & General Hospital, Narhe, Off Pune-Mumbai Bypass, Pune-411041, Maharashtra, India

#### Dr. Avinash R Joshi

MD, Professor, Department of Pathology, Smt. Kashibai Navale Medical College & General Hospital, Narhe, Off Pune-Mumbai Bypass, Pune-411041, Maharashtra, India

**ABSTRACT** Hemangiomas are the most common benign tumors of the liver<sup>1</sup>. Most hemangiomas are asymptomatic and therefore remain undiagnosed. Sometimes, patients present with anaemia or thrombocytopenia. Known as Kasabach-Meritt syndrome, this condition occurs when erythrocytes or platelets are destroyed by the tumour. Either way, these patients become 'High Risk Patients' if treated with Aspirin as they are predisposed to haemorrhage. We are reporting a case of cerebro-vascular accident. The patient was on Aspirin for a long time. He was admitted with duodenal perforation. On laparotomy, protruding giant hepatic hemangioma was detected.

### Introduction-

Hepatic hemangiomas are common. Most of them are small and asymptomatic. Giant hemangiomas of liver are reported in literature as uncommon entities. Exophytic, pedunculated hepatic hemangiomas are extremely rare.

Cavernous hemangiomas are 3 times more common in women than in men.<sup>2</sup>

As most of these lesions do not give rise to any symptoms, they may either get discovered during screening tests or autopsies for some other cause or remain unnoticed throughout life. Presence of these tumors may however pose danger to patients who are on thrombolytic therapy as it facilitates hemorrhage.

### Case Report-

A 60 year old male patient was admitted with complaints of epigastric abdominal pain and vomiting for one day. There was severe guarding and rigidity with tenderness. The bowel sounds were absent. There was fullness in the right upper quadrant. The edge of the liver was palpated well below the costal margin.

He had history of stroke 3 years ago and was on aspirin ever since. He also gave history of a 4 kg weight loss. He was diagnosed as a case of duodenal perforation and emergency laparotomy was done for perforation closure and omental patch. During surgery, a large nodular vascular mass was observed protruding from liver surface. The mass measured 10 x 10 cm in size. Multiple small nodules of similar consistency were seen all over the left lobe of liver. Biopsy was taken from the mass and sent for histopathological examination which revealed multiple large vascular channels filled with blood. The channels were lined by a single layer of endothelial cells and supported by collagenous wall.

### Discussion-

Review of literature shows that, though hemangiomas are commonly detected in liver, they are either detected during screening tests or

remain silent throughout life. In our case, the hemangioma was large and protruding from the liver surface. The term 'Giant Hemangioma' is reserved for lesions larger than 5 cm. Even with this size, the tumor may remain asymptomatic.

Some patients may present with right upper quadrant pain or fullness. Patients may also present with symptoms secondary to mass effect on adjacent structures.<sup>2</sup> Physical examination and laboratory values are generally normal.

The differential diagnosis includes cysts, abscess, hypervascular metastases, hepatic adenoma, hepatocellular carcinoma, intrahepatic cholangiocarcinoma or focal nodular hyperplasia<sup>2</sup>.

USG findings include focal, homogenous, hypovascular, echogenic lesions. Posterior acoustic enhancement and a hypoechoic center can also be seen. Giant hemangiomas may appear heterogeneous<sup>2</sup>.

The classic CT findings are a well circumscribed, round or lobular, hypoattenuating lesion at nonenhanced imaging, with peripheral nodular puddling on the initial images obtained after contrast administration followed by centripetal enhancement during the later phases<sup>2</sup>.

Technetium 99m labelled red blood cells can also be used to diagnose hemangiomas with a high degree of sensitivity and specificity, although this technique is less sensitive for lesions smaller than 2cm.

MR imaging reveals low signal intensity on T1 weighted images and markedly high signal intensity on T2 weighted images, these characteristics are likely due to slow flow within the lesion<sup>2</sup>.

Complications include inflammatory changes, intralesional or intraperitoneal hemorrhage and potential volvulus of a pedunculated lesion. Kasabach-Meritt syndrome which is described in the beginning may also occur.

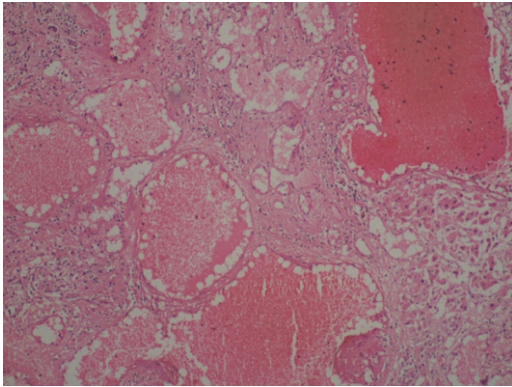
Management is largely conservative. Nonsurgical management techniques include arterial embolization with radiation therapy and interferon therapy in paediatric population.

Surgical treatment includes liver resection, enucleation, hepatic artery ligation or liver transplantation.

The patient was on Aspirin treatment for 3 years and was fortunate that the hemangioma didn't rupture.

#### **Conclusion-**

Our case highlights that the possibility of hepatic hemangiomas should be kept in mind before administering thrombolytic agents like Aspirin to a patient. Though rare, they may pose a danger of intraperitoneal hemorrhage.



**Fig. 1: HPE revealed multiple large vascular channels filled with slowly moving blood. The channels were lined by a single layer of endothelial cells and supported by collagenous wall.**

#### **References-**

1. M.Joshua Shellenberger, Robert Smith, Chintalapati Varma, Anil Kotru, Manoj Maloo, Heather Gerst; JAOA, Vol 110, No. 11, Nov 2010, 675-677
2. Prasanth M. Prasanna, Scott E. Fredericks, Steven S. Winn, Robert A. Christman; RadioGraphics Vol 30 No. 4, Jan 2010, 1139-1144