Original Research Paper

Volume-7 | Issue-11 | November-2017 | ISSN - 2249-555X | IF : 4.894 | IC Value : 79.96

General Surgery

HASHIMOTO'S THYROIDITIS VARYING CLINICAL PRESENTATIONS AND CHANGING MODALITIES OF TREATMENT

Khathir. S	Post graduate, Department of General surgery, Meenakshi Medical College Hospital and Research Institute, Enathur, Kanchipuram.
Ravinthar. A	Professor, Department of General surgery, Meenakshi Medical College Hospital and Research Institute, Enathur, Kanchipuram.
Chaitanya Krishna Ponnaganti	Post graduate, Department of General surgery, Meenakshi Medical College Hospital and Research Institute, Enathur, Kanchipuram.
Radhakrishnan. D	Professor, Department of General surgery, Meenakshi Medical College Hospital and Research Institute, Enathur, Kanchipuram.

ABSTRACT Majority of the Hashimoto's thyroiditis are managed medically. The role of surgery and the long-term complications of the disease in medically managed disease hasn't been adequately studied.

Aim: To study the varying presentations and the role of surgery in patients with Hashimoto's thyroiditis. To study the incidence of malignancy in Hashimoto's thyroiditis.

Material and Methods: in this case series 100 patients were studied. This study was conducted from October 2015 to April 2017. The protocol for the study was approved by both Department of General Surgery and the Ethical Review Committee of Meenakshi Medical College and research Institute, Enathur, Kanchipuram.

Results: Findings were tabulated accordingly.

Conclusion: Most of the cases of Hashimoto's thyroiditis an autoimmune disease are managed medically. In our study most of the patients presented for Multinodular goiter whose symptoms and swelling did not subside with medical management. In the patients who had FNAC suggestive of Hashimoto's had malignancy on histopathological examination. So, the patients have to be under careful surveillance for malignancy. The patients who do not respond to medical management can be successfully managed with surgery

KEYWORDS :

INTRODUCTION

CHRONIC (HASHIMOTO'S) THYROIDITIS is an autoimmune disease that may be associated with varying degrees of thyroid enlargement. A common cause of thyromegaly, it may coexist with benign (adenomatous goiter) or malignant thyroid disease[1,10]. In the selection of patients for surgical treatment, a discriminating approach is necessary to avoid operating on patients with chronic thyroiditis while providing every patient with malignant disease an opportunity for cure[2].

This was first described by Hashimoto in 1912. Chronic disorder of the thyroid gland – diffuse lymphocytic infiltration, fibrosis, parenchymal atrophy, and eosinophilic changes[3]. Also known as struma lymphomatosa. Mostly managed medically. The diagnosis can usually be made on the basis of clinical findings. Histologic confirmation is not usually required. Thyromegaly results from compensatory hyperplasia of the thyroid epithelium and diffuse lymphocytic infiltration. Regression over the course of several months usually follows the administration of thyroid hormone with suppression of TSH[5]. In patients with asymmetrical enlargement of the thyroid gland, nodular thyroiditis, or with incomplete failure of regression on suppressive therapy, a cutting needle biopsy procedure may be indicated to confirm the clinical diagnosis. Despite this characteristic clinical picture, patients undergoing thyroidectomy to differentiate "nodular goiter" from thyroid cancer, not infrequently are found to have chronic thyroiditis.

AIM

To know the varying presentation and role of surgery in patients with Hashimoto's thyroiditis To know the incidence of malignancy in Hashimoto's thyroiditis

MATERIALS AND METHODS

It is a retrospective study, involving 100 patients who underwent thyroidectomies for Hashimoto's thyroiditis in Meenakshi Medical College Hospital and Research Institute, Kanchipuram. Data was collected from the files of the Department of Pathology of Meenakshi Medical College Hospital and Research Institute. Study duration was from October 2015 to April 2017. Study was conducted after obtaining clearance from ethical committee of Meenakshi Medical College Hospital and Research Institute. All the patients were operated after obtaining formal informed written consent. The diagnosis by pathologist was accepted without further appraisal.

Thyroiditis was classified as Hashimoto's thyroiditis (diffuse lymphocytic in filtration with germinal centers, small follicles depleted of thyroglobulin, distorted, enlarged epithelial cells with large nuclei and eosinophilic cytoplasm Askanazy cells and varying degrees of fibrosis) and nonspecific or focal thyroiditis. The pathologic findings in patients undergoing thyroid surgery were reviewed.

RESULTS

Females more commonly affected. Mean age was 36 ± 7 years. Indications for surgery differed, some patients had more than one. The indications for surgery differed in patients with many patients having more than one indications for surgery. The main indication for surgery was Multinodular Goiter (n = 34, 34%) followed by cosmetic reasons (n = 27, 27%). The indications are represented in Fig.1. The mean duration of thyroid swelling was 10±2.4 years. The hyperthyroid patients are patients who are not controlled on medical management (n = 4, 28.57%) or who were taking anti-thyroid medications for more than 6 years (n = 10, 71.42%). All patients were in euthyroid state before surgery (TSH – 1.49±1.24). Of the 100 FNAC specimen of Hashimoto's thyroiditis histopathology had Hashimoto's thyroiditis in only 70 cases. Of the 30 cases 12 (12%) were reported differentiated thyroid carcinomas and the remaining 18 cases (18%) had nodular goiter. Of the 12 cases of malignancy 10 cases (83.33%) were papillary carcinomas and the remaining 2 cases (16.67%) had lymphoma. In all cases total thyroidectomy was done. All patients underwent pre-operative and post-operative indirect laryngoscope and serum calcium measurements which were normal except for 2 cases of transient hypocalcemia and 1 case of transient RLN palsy which recovered in 2 weeks. No significant post-operative complications were noted. There was an improvement in tiredness and overall wellbeing in 86% of cases at 6 months of follow-up.

Table 1. Demographic parameters

PARAMETERS	OBSERVATION
Male: Female	17: 83
Age	36±7 years

Table 2. Histopathological examination report

	PERCENTAGE	n	Total
CHRONIC THYROIDITIS (HASHIMOTO'S)	70%	70	100
NODULAR GOITER	18%	18	
MALIGNANCY	12%	12	
PAPILLARY CARCINOMA	83.33%	10	12
LYMPHOMA	16.67%	2	

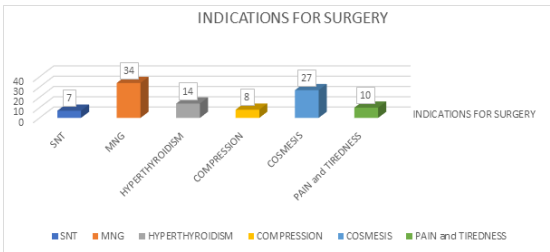

Fig. 1 Graphical representation of indications

DISCUSSION

- The indications cited for surgery is different in different series. Pain, compression, cosmesis and suspicion for malignancy were cited as indications in most of the studies[4]. Nenkov *et al*.[7] in their series of 132 cases reported that compressive symptoms, lack of response to thyroxine suppression, nodularity and cosmetic reasons as the indications for surgery. Majority of the patients in our series underwent surgery due to swelling and cosmetic reasons corresponding with other studies. Apart from these indications follicular neoplasm on FNAC in cases were also considered on the suspicion of malignancy. MacDonald et al.[6] reported that 31% of cases who had histopathological diagnosis of Hashimoto's Thyroiditis did not correlate with the preoperative cytology. In our study only 70 patients who had a cytology report of Hashimoto's had correlation with the histological report. Source of error were Hurthle cell neoplasm and follicular neoplasm. Presence of hyperplastic follicular cells and pleomorphic Hurthle cells in the FNAC specimen was often misinterpreted[6]. Gyory et al.[8] reported a 6.7% incidence of temporary RLN palsy and 5.1% permanent RLN palsy. In their series, the temporary hypocalcemia rate was 5.1%. One of the indications mentioned for surgery in HT has been the association of papillary carcinoma and lymphoma[9]. In ousr study temporary RLN palsy was 1% (n = 1), and transient hypocalcemia was 2% (n = 2).

CONCLUSION

Most of the cases of Hashimoto's thyroiditis, an autoimmune disease are managed medically. In our study most of the patients presented for Multinodular goiter whose symptoms and swelling did not subside with medical management. In the patients who had FNAC suggestive of Hashimoto's had malignancy on histopathological examination. So, the patients have to be under careful surveillance for malignancy. The patients who do not respond to medical management can be successfully managed with surgery in view of lesser complications and advancement in minimally invasive approaches.

REFERENCES

1. Matesa-Aniæ D, Matesa N, Dabeliæ N, Kusiæ Z. Coexistence of papillary carcinoma and Hashimotos thyroiditis. Acta Clin Croat 2009;48:9-12.
2. Shin ML, Lee JA, Hseih CB, Yu JC, Liu HD, Kekebew E, et al. Thyroidectomy for Hashimoto's thyroiditis: complication and associated cancers. Thyroid 2008;18:729-34.
3. Takami HE, Miyabe R, Kameyama K. Hashimoto's thyroiditis. World J Surg 2008;32:688-692.
4. Thomas CG, Rutledge RG. Surgical indications in chronic (Hashimotos) thyroiditis. Ann Surg 1981;193:769-76.
5. Kasagi K, Kousaka T, Higuchi K, Iida Y, Misaki T, Alam MS, et al. Clinical significance of measurements of antithyroid antibodies in the diagnosis of Hashimoto's thyroiditis: comparison with histological findings. Thyroid 1996;6:445-50.
6. MacDonald L, Yazdi HM. Fine needle aspiration biopsy of Hashimoto's thyroiditis. Sources of diagnostic error. Acta Cytol 1999;43:400-6.
7. Nenkov R, Radev R, Khristozov K, Kuzmanov Ia, Kornovski S, Kuzmanov S, et al. Hashimoto's thyroiditis: indications for surgical treatment. Khirurgiia (Sofiia) 2005;3:28-32.
8. Györy F, Lukács G, Juhász F, Mezösi E, Szakáll S, Végh T, et al. Surgically treated Hashimotos thyroiditis. Acta Chir Hung 1999;38:243-7.
9. Foppiani L, Secondo V, Arlandini A, Quilici P, Cabria M, Del Monte P. Thyroid lymphoma: a rare tumor requiring combined management. Hormones (Athens) 2009;8:214-8.
10. Colin G. Thomas, Jr., M.D., Robert G. Rutledge, M.D. Surgical Intervention in Chronic (Hashimoto's) Thyroiditis. Ann Surg 1981: 193: 769-773.