Original Research Paper

Volume-7 | Issue-11 | November-2017 | ISSN - 2249-555X | IF : 4.894 | IC Value : 79.96

Orthopaedics

PROXIMAL END HUMERUS FRACTURE IN ELDERLY OSTEOPOROTIC PATIENTS WITH CO-MORBIDITIES TREATED WITH CLOSED REDUCTION AND UNIVERSAL MINI EXTERNAL FIXATOR (UMEX) FIXATOR – A CASE SERIES

Dr. Sonawane Darshankumar — Shashwat Hospital Aundh, Pune.

Dr. Darawade Nilesh — Smt. Kashibai Navale Medical College and General Hospital, Pune.

ABSTRACT

Introduction : To assess the results of fixation of fracture proximal end humerus in elderly osteoporotic individuals with medical co-morbidities.

Materials and Methods : We did a retrospective analysis of 21 patients with fracture proximal end humerus operated with Closed Reduction and UMEX fixator application.

Results : All the 21 patients achieved union of the fracture. None of the patients suffered from any Anaesthesia related complications or required prolonged ICU stay. All patients achieved functional range of motion of the shoulder with supervised physiotherapy.

Conclusion : Closed reduction and UMEX fixator application is a safe, less morbid, reliable and effective procedure for the treatment of proximal end humerus fractures in elderly osteoporotic individuals with multiple medical co-morbidities.

KEYWORDS : Proximal end Humerus fractures, Closed Reduction, UMEX fixator.

Introduction

Fractures of the proximal end Humerus are a common occurrence in elderly patients after a fall on outstretched hand due to osteoporosis.[1] There are numerous treatment modalities available for managing these fractures ranging from non-operative treatment with Universal Shoulder Immobilizer or Chest Arm Strapping to different Operative methods such as closed reduction and percutaneous fixation with K-wires, external fixator application, open reduction and plating and hemiarthroplasty[2,3,4,5,6]. Most often these patients also have associated co-morbidities such as Diabetes Mellitus, Ischaemic Heart Disease and Hypertension among others. Often these co-morbid conditions can make an extensive surgery more risky for the patient as there is high mortality rate associated with fracture Proximal End Humerus in the elderly[7]. Hence we decided to perform closed reduction and percutaneous fixation with a UMEX fixator on these patients. This avoided the risks associated with more extensive surgeries in these fragile elderly patients with medical co-morbidities.

Materials and Methods

A retrospective analysis of patients operated between March 2008 and August 2014 was done. We included a total of 21 patients in the study, 15 females and 6 males. All patients had some medical co-morbidity and were not fit to undergo extensive – open surgery. All patients were available for follow up. The average follow up duration was 1 year (range 5 months – 4 years).

The inclusion criteria were

- 2 or 3 part proximal end Humerus fractures.
- Elderly patients with co-morbidities.
- Age more than 60 years.

Exclusion criteria were

- Patients without co-morbidities.
- 4 part fracture of proximal end Humerus.
- Fracture dislocation proximal end Humerus.
- Age less than 60 years

The average age of patients was 68 yrs (range 60-78 years).
We operated 18 patients under short General Anaesthesia and 3 patients were operated under Local Anaesthesia + Sedation.

Under image intensifier control closed reduction of the fracture and fixation with 5-6 percutaneously placed Kirchner wires (K-wires) was done. We used 1.5 or 1.8 mm K-wires for all the cases. These K-wires were then inter-connected externally with the help of beta clamps, fish mouth clamps and the connecting rods of the UMEX fixator assembly system.

Post-operatively all patients were given an Arm Pouch Sling support. Physiotherapy was started on the second post-operative day. Patients were allowed to do only pendulum exercises and shoulder shrugs in the first 10 days. Gentle range of motion exercises – flexion and extension, assisted abduction and rotations were started on the 11th postoperative day. Range of Motion was increased as per tolerance.

Patients were reviewed every week for assessment of the fixator assembly. Pin tract care and dressings were done for all patients on a regular basis. Xray evaluation was done immediate post-op and then later at monthly intervals.

The UMEX and K-wires were removed after radiological union of the fracture, at 3 -5 months after surgery (average 4 months) as an Out Patient Department (OPD) procedure without anaesthesia under aseptic conditions. Dressings for Pin tracts was done till complete healing.

Physiotherapy was continued after fixator removal

Fig – 1 : Xrays of an Typical fracture fixed with K wires and UMEX fixator

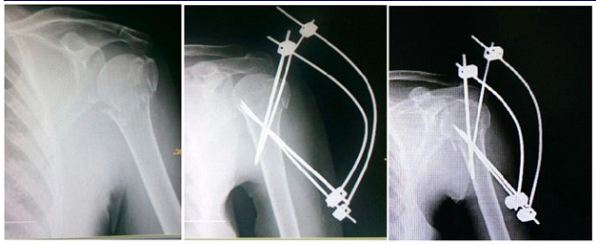

Fig – 2 : Xrays of a Typical fracture fixed with K wires and UMEX fixator.

Fig – 3 : Clinical pictures showing the UMEX fixator assembly and Range of Motion with UMEX fixator assembly in situ.

Results

All 21 patients were available for follow up evaluation.
Radiological union was achieved in all patients.

All the patients recovered uneventfully in the post-operative period. None of the patients suffered from any anaesthesia related complications, morbidity and mortality. None of the patients required prolonged ICU stay.

VAS scores reduced gradually from a mean of 6 (immediate post-op) to 3 (at 1 month) and 1 (at 6 months).

Range of Motion of all patients improved gradually over the post operative period with supervised Physiotherapy. All patients achieved functional range of motion of the shoulder 4-6 months after surgery.

We had complications in the form of superficial pin tract infection in 3 patients and K-wire back out in 2 patients. The superficial pin tract infection resolved with oral antibiotics and regular sterile dressings.

Discussion

Fractures of the proximal end of Humerus are very common and their incidence has been increasing in the recent past[1,8,9]. As such these fractures occur in all age groups, but their occurrence has increased in the elderly especially due to senile osteoporosis[1]. There are various modalities that have been described for the management of these fractures in the elderly ranging from non-operative treatment with Universal Shoulder Immobilizer or a Chest Arm Strapping to different Operative methods such as closed reduction and percutaneous fixation with K-wires, external fixator application, closed reduction and fixation with retrograde elastic nailing, open reduction and internal fixation with locking and non-locking plates and prosthetic replacement[2,3,4,5,6]. All of these modalities have their own advantages and disadvantages[10].

Of more concern in these elderly patients is the co-existence of multiple medical co-morbidities such as diabetes mellitus, hypertension, ischaemic heart disease, renal or hepatic function derangement which poses multiple risks in terms of anaesthesia and immunity levels[7, 10]. There is a high risk of mortality associated with fracture proximal end Humerus, as high as 19%[10]. Patients also may not co-operate with the rigorous physical therapy due to pain after extensive surgery and dissection around the shoulder. Also with extensive surgery and dissection, the risk of excessive blood loss, wound healing issues and infection also increases[9,10].

We therefore performed closed reduction and fixation with k wires which were then interconnected with the UMEX fixator system. This is a relatively easy to perform surgery. The duration and requirement of anaesthesia was significantly lower in this method as compared to what is required during open reduction and fixation with plate. Patient compliance to the UMEX fixator was also excellent. All of our patients achieved union of the fracture and returned to their normal daily functions and activities of daily living. More importantly none of the patients suffered from any anaesthesia related complications and the morbidity-mortality associated with the more extensive surgeries around the shoulder. There was a gradual and steady improvement in the VAS scores. All of the patients achieved a good and functional range of motion which did not interfere with their day to day functions and activities of daily living.

Conclusion

Closed reduction and fixation with k-wires and UMEX fixator system is an excellent operative modality available to the orthopaedic surgeon for the management of proximal end Humerus fractures in elderly patients with medical co-morbidities. This method reduces especially the short term or immediate post-operative morbidity and mortality associated with extensive surgeries in these high risk individuals. It is possible to achieve union and good range of motion of the shoulder with this operative modality. A longer follow up is essential to evaluate the long term outcomes of this procedure.

References

1. The Structure of the Upper End of the Humerus with Reference to Osteoporotic Changes in Senescence Leading to Fractures. Hall MC, Rosser M et. al. Can Med Assoc J. 1963 Feb 9;88(6):290-4.
2. Mid-term results of internal fixation of proximal humeral fractures with the Philos plate. Papadopoulos P, Karataglis D et al. Injury. 2009 Dec;40(12):1292-6. doi: 10.1016/j.injury.2009.03.008. Epub 2009 Jun 17.
3. Factors associated with the decision for operative versus non-operative treatment of displaced proximal humerus fractures in the elderly. Okike K1, Lee OC et.al. Injury. 2013 Apr;44(4):448-55. doi: 10.1016/j.injury.2012.09.002. Epub 2012 Sep 27.
4. Conservative treatment of fractures and fracture-dislocations of the upper end of the humerus. Young TB, Wallace WA. J Bone Joint Surg Br. 1985 May;67(3):373-7.
5. Long-term results of conservatively treated fractures of the upper end of the humerus. Sartori E, Fusi M et al. Arch Putti Chir Organi Mov. 1989;37(2):389-96.
6. Osteosynthesis using the "palm-tree" nail technic in fractures of the surgical neck of the humerus. Kapandji A et al. Ann Chir Main. 1989;8(1):39-52.
7. Increased mortality after upper extremity fracture requiring inpatient care. Somersalo A, Paloneva J et.al. Acta Orthop. 2015;86(5):533-57.
8. Changes in the incidence of fracture of the upper end of the humerus during a 30-year period. A study of 2125 fractures. Bengnér U, Johnell O et al. Clin Orthop Relat Res. 1988 Jun;(231):179-82.
9. Do injuries of the upper extremity in geriatric patients end up in helplessness? A prospective study for the outcome of distal radius and proximal humerus fractures in individuals over 65. Einsiedel T, Becker C et al. Z Gerontol Geriatr. 2006 Dec;39(6):451-61.
10. Complications and hardware removal after open reduction and internal fixation of humeral fractures. Lovald S, Mercer D et. al. J Trauma. 2011 May;70(5):1273-7; discussion 1277-8.