



## MANGLED HAND INJURIES-MEANING OF PRESERVING THE REMNANTS

**Dr.M.Sugumar**

Senior Assistant Professor, 701, Department of Plastic Surgery, Stanley Medical College, Chennai-1, Tamil Nadu, India

**Dr G S Radhakrishnan**

Associate Professor, Department of Plastic Surgery, Tiruvarur Medical College, Tiruvarur, Tamil Nadu-610004 -Co-Author

**Dr Kaushik Kumar E**

Post Graduate, 701, Department of Plastic Surgery, Stanley Medical College, Chennai-1, Tamil Nadu, India

**ABSTRACT**

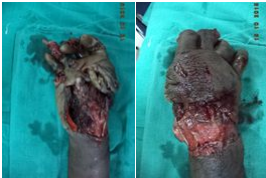Mangled hand injuries are very common devastating injuries encountered in our institute that result in total/near total hindrance of hand function. This study includes 19 patients of varying age group dominantly male sex from August 2015 to October 2016. Majority of patients are from industrial sector. These group of patients were present with different presentation of remnants of the hand either finger or multiple digits/remnants. Preoperatively they were counselled for reconstruction/amputation. All the patients want to retain the remnants of the hand whichever is present even after explaining about the reduction of Disability percentage which will be useful to their future compensation benefit. They were managed by standard principles of reconstruction. Post operatively again they were evaluated and they are happy with the remnants as it avoids prosthesis and they have some useful supportive hand function.

**KEYWORDS :** Mangled Hand injuries, Crush injuries hand, remnants in hand injuries**INTRODUCTION**

A "mangled" extremity injury has injuries to at least three of the four following tissue groups (1)

- Integument/soft tissue,
- nerve,
- vasculature, and
- bone

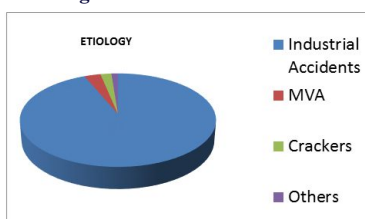
Mutilating hand injuries are a common but devastating injuries encountered in our institute that result in total/near total loss of hand function.

**Figure 1 Mangled Right Hand in an Industrial Worker****Materials and Methods:**

This is a descriptive study of the patients who have suffered major hand injuries resulting in a mangled hand referred to a Government tertiary care centre. Patients who have suffered major injuries (MVA, Occupational Injury, Blast Injuries) presenting to our institute during the period from August 2013 to February 2016 were included in this study (Ref:Dept Registry). Patients underwent sequence of early debridement, skeletal stabilization, soft tissue cover, reconstruction in stages.

**Etiology**

- 92%-Industrial accidents
- 3% Motor Vehicle Accidents
- 3% Cracker/Country bomb blasts
- 2% others

**Figure 2 % of Etiological factors****Age group**

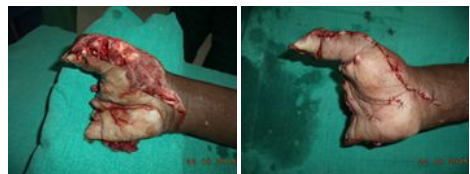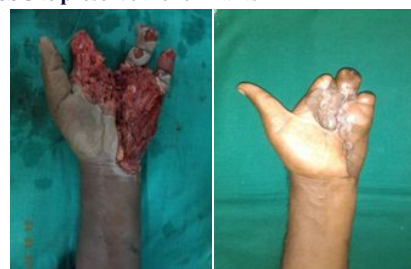- predominantly 19 to 27 years
- 99% of them being males-Breadwinners
- 1% children
- Of the industrial accident category >85% were **migrant population**

**Risk factors:**

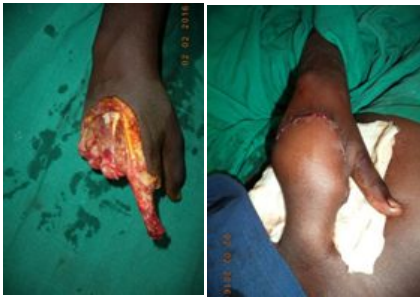- Inadequate training
- Language
- Safety Measures
- Prolonged work hours
- Illiteracy
- Common timings of accidents: 14.00-15.30hrs and 22.30-02.00 hrs.

**MANAGEMENT SEQUENCE:**

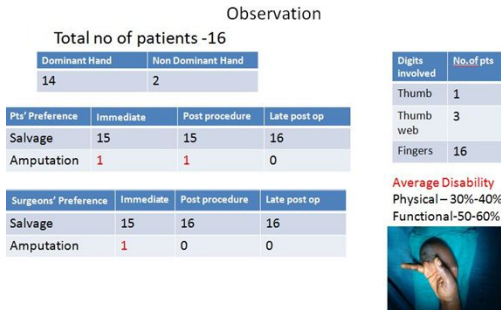
- Early debridement
- Skeletal stabilization
- Soft tissue cover – Flaps/Grafts
- Staged reconstruction
- Rehabilitation
- Average hospital stay 27 days (range 13 to 47 days)

**Figure 3 Early Debridement and Primary Closure preserving Thumb alone****Figure 4 SSG to preserve the remnants**

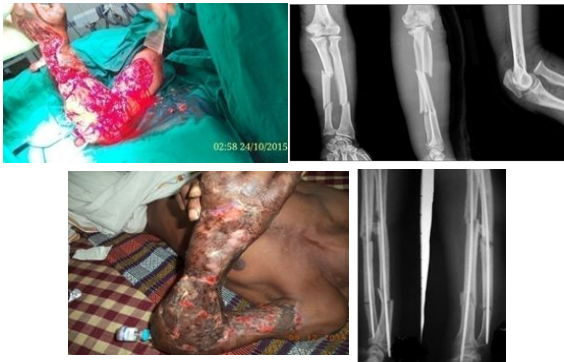**Figure 5 Groin flap to preserve the remnants**



**Figure 6 Statistical Analysis of Patients' and Surgeon's perspective**



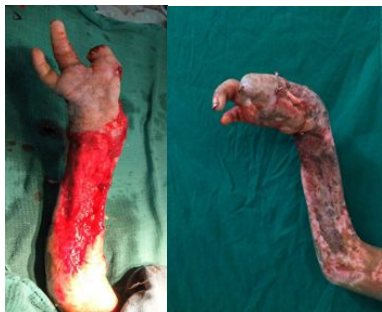**Figure 7 Partial Multiple level amputation of left upper limb preserved by skeletal stabilization & SSG**



**Discussion & Analysis:**

Major hand injuries are a rarity in the western developed world due to the improved and advanced safety measures followed there. Yet in developing countries due to the rapid growth of the industrial sector large numbers of young population get into the work either skilled or unskilled. Due to migrant labourers and low educational status, language is a barrier to understanding of the nature of work and the disastrous complications that can result. This in itself is self explanatory for the nature and amount of injuries to these patients.

**Figure 8 Extremely mangled forearm and hand salvaged by Debridement & SSG**



The hand has basically three functional units viz. Radial post,Ulnar post and thumb web. In any case of a major injury to the hand the ultimate goal is to achieve the functional hand as described above. This can be done either by preservation of the remnants of the injury or a staged reconstruction. There is always a dilemma for the surgeon in a

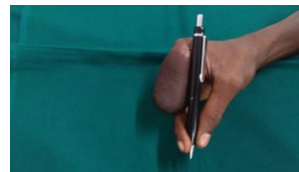
severe mutilating injury what and how much to preserve during the debridement which will have an implication in future reconstruction which includes multiple procedures. This series of procedures also affect the patient physically, mentally, financially and socially. Certain times both the surgeon and/or the patient may come to a conclusion of preserving the remnants or amputation. Various of the above factors are discussed with the patients and attenders during the treatment plan and they are counselled accordingly. We strongly believe in preserving the remnants of the hand in order to have the sensate and functioning and socially acceptable hand. The above analysis takes through to the conclusion of preserving the remnants.

**CONCLUSION:**

The average hospital stay was 27 days (range 13 to 47 days) with loss of work days, income and significant psychosocial trauma(2,3). At the time of discharge all patients had a stable soft tissue cover with flaps/grafts yet to undergo further reconstruction for a functioning hand. Though by giving a good soft tissue cover the functional outcome is not guaranteed. Majority of the patients preferred preserving the remnants. This study revealed that though immediate post operative hand, donor site morbidity bothered the patient, for the surgeon it gives time to plan further options before a radical procedure and on long term basis psychological satisfaction is satisfactory for both the Surgeon and the Patient.(4)

**Remnants give more functional and psychological support than an amputation.**

**Figure 9 Preserving the remnants of the hand Enhances the Use of the available digits**



**References**

1. Gregory RT, Gould RJ, Peclet M, et al. The mangled extremity syndrome (M.E.S.): a severity grading system for multisystem injury of the extremity. J Trauma. 1985;25:1147-1150
2. Didierjean A. Psychological aspects. In: Foucher G, editor. Reconstructive Surgery in Hand Mutilation. London: Martin Dunitz; 1997. p. 151e4.
3. Gustafsson M, Amilon A, Ahlstrom G. Trauma-related distress and mood disorders in the early stage of an acute traumatic hand injury. J Hand Surg 2003;28B:332e8.
4. Tintle SM, Baechler MF, Nanos GP 3rd, Forsberg JA, Potter BK. Traumatic and trauma-related amputations: part II: upper extremity and future directions. J Bone Joint Surg Am. 2010;92:2934-2945.