



“SURGICAL MANAGEMENT OF CLOSED BIMALLEOLAR ANKLE FRACTURES BY ORIF WITH FIBULAR PLATING AND TBW/SCREW FIXATION OF MEDIAL MALLEOLUS-OUR EXPERIENCE”

Dr. N. Sathish Kumar*

MBBS,D. Ortho,(DNB)(Ortho) *Corresponding Author

Dr. Satveer Singh

MBBS, (DNB) (Ortho) Dept of Orthopaedics, JLNH & RC, Sector-9 Bhilai, Chhattisgarh - 490009

Dr. Jayesh Kumar Dave

MS(Ortho) Joint Director,(M&HS) Unit 1 incharge Dept. of Orthopaedics, JLNH & RC, Sector-9, Bhilai, Chhattisgarh-490009

ABSTRACT

Background: Bimalleolar ankle fractures are common fractures occurring in all age groups. Appropriate management is necessary for optimal function and to prevent complications.

Objectives: To assess the role of ORIF of closed Bimalleolar fractures in adults with fibular plating and TBW/Screw fixation of medial malleolus.

Material and methods: This was a Prospective, Observational Study done at JLN & RC, Bhilai, Chhattisgarh on 34 patients. Patients evaluated with Olerud and Molander Score (OMAS) and radiographically.

Results: In our series of 34 patients, 13 patients (38.24%) had excellent results as per Olerud and Molander Scoring system, 18 (52.94%) had good results. 3 patients (8.82%) had fair results. We had a favourable outcome of 91.18%.

Conclusion: Our Study recommends ORIF of displaced Closed Bimalleolar fractures, we found TBW/Screw fixation for medial malleolus and Lag Screw with posterior Neutralization plate for lateral Malleolus fractures.

KEYWORDS : Bimalleolar ankle fracture, cannulated cancellous screw, malleolar screw, tension band wire

INTRODUCTION

Ankle fractures are one of the most common lower limb fractures.¹ The annual incidence of ankle fracture is between 107 and 184 per 100,000 persons.² They account for 9% of all fractures,³ one fourth constitutes bimalleolar fractures.⁴ The most common causes of ankle fractures are twisting injuries and falls, followed by sports injuries. However, in the Indian scenario, Road Traffic Accidents are the most common mode of injury⁵.

Cast immobilisation leads to muscle atrophy, cartilage degeneration and a stiff, painful and swollen joint.⁶ Hence, Surgical fixation is the logical choice.

Failure to adequately identify and treat injuries to the syndesmosis may result in continued ankle instability and poor patient outcomes.

AIMS AND OBJECTIVES

- To assess the role of open reduction and internal fixation of bimalleolar fractures fixed with fibular plating and Tension band wire/Screw fixation of medial malleolus.
- To evaluate functional outcome of surgically managed bimalleolar fractures.
- To study the complications, if any.

Radiological Evaluation

We used Anteroposterior, Lateral and Mortise views for evaluation in this study. Tibiofibular overlap on an AP view indicates proper syndesmosis relationship. The space between the medial fibular wall and the tibial incisural surface, the tibiofibular clear space, should be less than 5 mm.

The anterior tibial tubercle should overlap the fibula by at least 6 mm or 42% of the fibular width.

The Shenton's line, drawn from the Wagstaffe tubercle of the fibula to the medial malleolus should pass through the tibial plafond. Incongruity of this line indicates fibular shortening.⁷

Medial clear space: normally is 4 mm, widening indicates fracture and or injury to the syndesmosis.

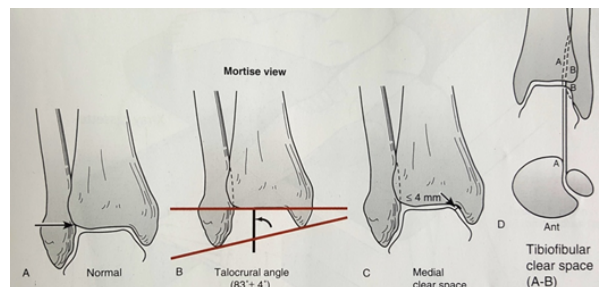


Figure 1: Talocrural angle and tibiofibular clear space

The talocrural angle normally is 4 - 11 degrees. The talocrural angle must be within 2-5 degrees of that on the unaffected side and an increase indicates fibular shortening.

Per-operative radiographic assessment

Anatomical reduction requires the maintenance of length, alignment and rotation of fibula and restoration of syndesmosis. The per operative images should critically analyse the length of fibula by-

- Tibiofibular line (radiographic line from distal fibular tubercle if drawn toward tibia should pass through tibial plafond on the mortise radiograph)

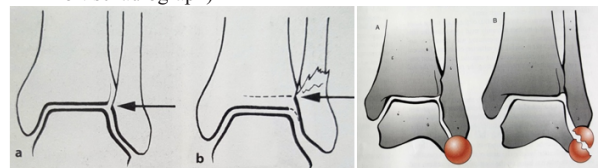


Figure 2: Tibiofibular line

circle sign

- Circle sign (on the mortise radiograph there is an unbroken circle formed between lateral recess of fibula and lateral process of the talus).⁸
- Tibiofibular clear space at level of syndesmosis on the anteroposterior radiograph. It is measured at 1 cm proximal to the ankle joint, there should be <6 mm between the medial border of the fibula and the lateral border of the tibial incisura. These radiological parameters can be equally utilized to assess the quality of reduction in non-operative management of the ankle fractures as well.⁹

There should be equal and parallel medial, superior and lateral clear space on the mortise radiograph. Circle sign and uniform clear space also indicate restoration of fibular rotation and syndesmotomic alignment.

Danis-Weber AO Classification

- A) Fibula fracture below syndesmosis (infrasyndesmotomic)
- B) Fibula fracture at the level of syndesmosis (trans-syndesmotomic)
- C) Fibula fracture above syndesmosis (suprasyndesmotomic)

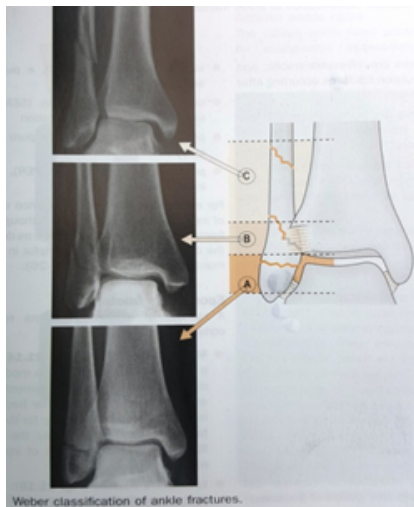


Figure 3

MATERIAL AND METHODS

Study site: J.L.N. Hospital and Research Centre, Bhilai, Chhattisgarh.

Study population: All bimalleolar fracture patients satisfying the inclusion criteria and willing to take part in the study were included.

Study Design: A PROSPECTIVE, OBSERVATIONAL STUDY

Number of Patients: 34

Patients satisfying the inclusion criteria and given informed consent for enrolment in research work were included in our study.

Study period 15.06.2016 to 14.06.2017

Inclusion Criteria

- 1) Patients with age above 18 years.
- 2) Patients having closed bimalleolar fractures
- 3) Patients who are fit for surgery and have given informed consent.

Exclusion criteria

- 1) Skeletally immature patients.
- 2) Patients with associated fractures around ankle joint.
- 3) Patients with undisplaced fractures which can be treated by closed methods.
- 4) Patients with late presentation, with nonunion, malunion and neurovascular injury.

METHODOLOGY

Immediate Management:

All the patients presenting to the Emergency Department were treated according to ATLS Protocol, subluxation or dislocation was reduced, splinting done and elevated, adequate analgesics given, procedure and prognosis explained to patient, written consent taken, Pre-anesthetic checkup done and after obtaining fitness for surgery, patients were posted for surgery, all patients underwent spinal anaesthesia.

Definitive Management¹⁰

Medial Malleolus- Malleolar Screw or Cannulated Cancellous Screw fixation

Lateral Malleolus- Lag Screw and Neutralization plate

OPERATIVE STEPS:

1. Lateral malleolus: Open reduction with lag screw and neutralization plate applied after bringing fibula out to length and stabilized. Incompetence of the syndesmotomic ligaments may be clear from preoperative radiographs, Hook test done to assess syndesmotomic integrity, A direct lateral pull on the fibula with a hook is performed under fluoroscopic control, if >3 or 4 mm lateral displacement seen, diastasis is addressed by stabilizing the fibula anatomically within the incisura with screw to allow ligament healing. If the syndesmotomic ligaments are intact, this will complete the stabilization of the lateral buttress.
2. Medial malleolus: The medial side should be exposed, cleared of any soft tissue trapped in fracture site and if the fragment is large and transverse fracture line, malleolar screw/cannulated cancellous screw is fixed, if the fracture line is vertical, a transverse screw is fixed perpendicular to fracture line. If the medial malleolar fragment is small, Tension band wiring is done. Medial deltoid ligament is sought for and repaired if torn.

OBSERVATIONS AND RESULTS

1) Age Incidence (Table 1)

Age group	No. of patients	Percentage (%)
18-30	5	14.7
31-50	12	35.29
51-70	14	41.18
>70	3	8.83
Total	34	100

2) Various modalities of Surgical fixation (Table 2)

Fracture Site		No of patients	Percentage (%)
Medial malleolar fixation	Malleolar screw	6	17.64
	Cannulated cancellous screw	9	26.48
	Tension Band Wire	19	55.88
Lateral malleolar fixation	Fibular Plate	34	100
Syndesmosis fixation	Cortical screw	3	8.82

3) Outcome of various modalities of fixation (Table 3)

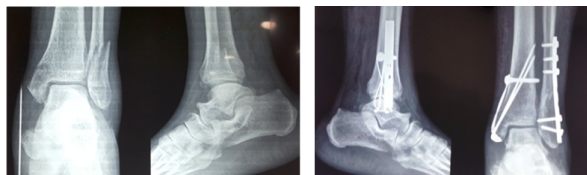	Excellent	Good	Fair	P value
Malleolar screw	3(23.08%)	2(11.11%)	1(33.33%)	0.66 NS
Cannulated cancellous screw	2(15.38%)	6(33.33%)	1(33.33%)	
Tension band wire	8(61.54%)	10(55.56%)	1(33.33%)	
Total	13(100%)	18(100%)	3(100%)	

4) Final outcome evaluation based on Olerud and Molander Score (Table 4)

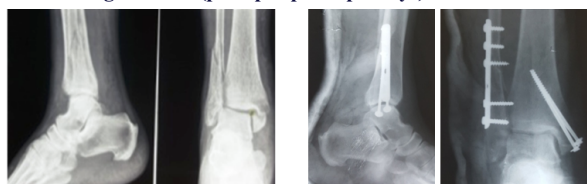
Outcome	Percentage (%)
Excellent	38.24
Good	52.94
Fair	8.82
Poor	0
Total	100

CLINICAL PHOTOGRAPHS

Case-1:- Figure 4 (pre-op & post-op x-rays)



Case-2:- Figure 5 (pre-op & post-op x-rays)



DISCUSSION

This study was an institution based prospective, observational study, conducted at J.L.N. Hospital and Research Centre, Bhilai,

Chhattisgarh.

In this study, there were 24 male and 10 females with an average age of 50.7 years with age range from 19-82 years. 19 patients had right sided involvement. In 23 patients, fall and twisting injuries was the mode of injuries. All patients underwent Open Reduction and Internal fixation with fibular plating for lateral malleolar fracture. 19 underwent Tension Band wiring and 15 patients underwent Screw fixation for Medial Malleolus.

Our findings are similar to Ramana et al¹¹ series of 48 patients, with maximum patients being between 40-65 years. In older patients, due to osteoporosis, minor trauma or twisting injury causes the fracture.

Tim Schepers et al¹² suggest that every effort should be made to operate on closed ankle fractures as soon as reasonably possible.

Among the 6 patients who underwent Malleolar screw fixation, 3 (23.08%) patients had excellent and 2 (11.11%) patients had good score, among the 9 patients who had cannulated screw fixation, 2 (15.38%) had excellent and 6 (33.33%) had good score and among the 19 patients who had TBW fixation, 8 (61.54%) had excellent and 10 (55.56%) had good score. We had highest number of favourable outcome with TBW fixation.

Most Indian authors^{4,5,11} prefer TBW, for it is biomechanically superior^{13,14} with wider indications and less hardware prominence compared to unicortical screw fixation and also it can be used in small, comminuted and osteoporotic fractures. Malleolar screw can cause or aggravate comminution in osteoporotic bone, hence, In our study, majority of the patients were treated with TBW fixation and they gave better results compared to screw fixation.

CONCLUSION

Our study recommends Open Reduction and Internal fixation of Bimalleolar Ankle fractures. We found that TBW/Screw fixation are good options for medial malleolar fractures, We found TBW to be a better option. For Lateral Malleolar fracture, Lag screw with posterior neutralization plate seems to be the best mode of intervention and the plate needs to be augmented with K- wires in osteoporotic patients.

RECOMMENDATIONS

Open reduction and internal fixation of unstable fractures is superior¹⁴ to closed methods.

- Handling of soft tissues¹⁵ is the single most important aspect because soft tissue cover is less in ankle and also precarious blood supply.
- Tension band wiring is better for medial malleolus fixation^{4,5,16} and lag screw with neutralization plate is a suitable option for lateral malleolar fractures. Augmentation of Fibular plate with k-wire in osteoporotic patients is recommended.
- Syndesmotic ligamentous injuries have to be sought out and addressed in order to prevent ankle instability.
- The timing of surgery is important, it is best to operate within 2 days¹³ or wait for a minimum of 7-10 days for the swelling to subside (wrinkle sign) in order to prevent wound complications.¹⁴

REFERENCES

1. Lash, N., Horne, G., Fielden, J. and Devane, P. (2002) Ankle Fractures: Functional and Lifestyle Outcomes at 2 Years. *ANZ Journal of Surgery*, 72, 724-730.
2. Singh, R., Kamal, T., Roulohamin, N., Maoharan, G., Ahmed, B. and Theobald, P. (2014) Ankle Fractures: A Literature Review of Current Treatment Methods. *Open Journal of Orthopedics*, 4, 292-303.
3. Court-Brown, C.M. and Caesar, B. (2006) Epidemiology of Adult Fractures: A Review. *Injury*, 37, 691-697. <http://dx.doi.org/10.1016/j.injury.2006.04.130>.
4. Badgire K, Sharma G, Naik L. Modified tension band wiring in medial malleolus fractures- a prospective study. *International Journal of Research and Review*. 2016; 3(11):103-108.
5. Dhillon MS, Ebenezar J, John R. Foot and Ankle Surgery. *The Indian Scenario in 2016*. *J Foot Ankle Surg (Asia-Pacific)* 2017, 4(1): 40-44.
6. Makwana, N.K., Bhowal, B., Harper, W.M., et al. (2001) Conservative versus Operative Treatment for Displaced Ankle Fractures in Patients over 55 Years of Age. *Journal of Bone and Joint Surgery*, 83, 525-529. <http://dx.doi.org/10.1302/0301-620X.83B4.11522>
7. Coughlin, M.J. and Saltzman, C.L. (2006) Chapter 3—Imaging of the Foot and Ankle. In: Coughlin, M.J., Mann, R.A. and Saltzman, C.L., Eds., *Surgery of the Foot and Ankle*, 8th Edition, Elsevier Mosby, 68-96.
8. Herscovici, D., JR., Anglen, J.O., Archdeacon, M., Cannada, L., Scaduto, J.M.: Aovnidation complications in the treatment of pronation-external rotation ankle fractures, syndesmotic injuries, and talar neck fractures. *J. Bone Jt Surg.*, 90-A: 898-908, 2008.
9. Mehta SS, Rees K, Cutler L, Mangwani J (2014) Understanding risks and complications in the management of ankle fractures. *Indian J Orthop* 48:445-452.
10. Anna Ekman, Lena Brauer., Malleolar fractures., *AOTRAUMAORP*, 2013 august.

11. S.S.V. Ramana, M. P. R. Vittal., A Study on Internal Fixation of Bimalleolar Ankle Fractures., *IOSR Journal of Dental and Medical Sciences (IOSR-JDMS)* e-ISSN: 2279-0853, p-ISSN: 2279-0861. Volume 14, Issue 10 Ver. VI (Oct. 2015), PP01-04.
12. Tim Schepers & Mark R. De Vries & Esther M. M. Van Lieshout & Maarten Van der Elst., The timing of ankle fracture surgery and the effect on infectious complications: A case series and systematic review of the literature., *International Orthopaedics (SICOT)* (2013) 37:489-494., DOI 10.1007/s00264-012-1753-933.
13. Ostrum, R. F., & Avery, M. C. (2016). Open reduction internal fixation of a bimalleolar ankle fracture with syndesmotic injury. *Journal of Orthopaedic Trauma*, 30, S43-S44.
14. Fowler, T.T., Pugh, K.J., Litsky, A.S., Taylor, B.C., French, B.G.: Medial malleolar fractures: a biomechanical study of fixation techniques. *Orthopedics*, 34: 349-355, 2011.
15. Zaghoul A, Haddad B, Barksfield R, Davis B: Early complications of surgery in operative treatment of ankle fractures in those over 60: A review of 186 cases. *Injury* 2014; 45: 780-3.
16. Michael, P. and Clare, M.D. (2008) A Rational Approach to Ankle Fractures. *Foot and Ankle Clinics*, 13, 593-610. <http://dx.doi.org/10.1016/j.fcl.2008.09.003>.