



## VARIATIONS OF THORACIC DUCT IN ITS COURSE IN SOUTH INDIAN POPULATION

**Bernard Ritchie**

**K. Praveena  
Kumari**

**ABSTRACT** Thoracic duct is the largest lymphatic channel draining the lymph and chyle from whole of the body below the diaphragm and left side of the body above the diaphragm. In 1647 Jean Pecquet (1622-1674) discovered the thoracic duct while working on animal dissection. He was an anatomist of Paris at that time. Pecquet reported his findings in "Experiment nova anatomica" in 1651. The year after that Johannes Van Hoorne, a Dutch professor, he himself independently discovered the thoracic duct and observed in human body. Thoracic duct arises as a dilatation known as cisterna chyli. The cisterna chyli lies at the level of L<sub>1</sub>-L<sub>2</sub> deep to the right crus of the diaphragm. It passes through the aortic opening to the right of the aorta. It ascends in the posterior mediastinum between the vertebral column and oesophagus, with the descending thoracic aorta on left side and azygos vein on the right side. At the level of body of the 5<sup>th</sup> thoracic vertebrae, the duct gradually inclines to the left and enters the superior mediastinum. In the superior mediastinum the duct is crossed anteriorly by arch of aorta and then runs posterior to the initial segment of left subclavian artery. Then it ascends along the left border of oesophagus up to the transverse process of 7<sup>th</sup> cervical vertebrae. At the level of C<sub>7</sub> it leaves the oesophagus and arches laterally behind the carotid sheath in front of the apex of pleura and then downwards across the front of the subclavian artery to end by opening into commencing of brachiocephalic vein (junction between left internal jugular vein and left subclavian vein).

When the duct is blocked or damaged a large amount of lymph can quickly accumulate in the pleural cavity, this situation is called Chylothorax. Chronic inflammatory conditions like tuberculosis of lung, Sarcoidosis and other granulomatous diseases involving the posterior mediastinal lymph nodes may cause compression or obstruction of the thoracic duct. The conditions Chylothorax, Chyluria, thoracic duct cyst, cervical thoracic duct fistulas, Chylous ascites which are sometimes fatal. Hence variations of the thoracic duct are of extreme importance to a thoracic surgeon.

With the recent advances by radio imaging techniques like Helical Multi detector-Row computed Tomography, Computerized Tomography scanning (C.T), Ultrasonography, Lymphoscintigraphy, Lymphangiography, Near-Infrared fluorescence imaging, MRI (magnetic resonance imaging), and also catheterization of thoracic duct are being successfully under taken to demonstrate the course of the thoracic duct.

### KEYWORDS :

#### INTRODUCTION

Thoracic duct is the largest lymphatic channel draining the lymph and chyle from whole of the body below the diaphragm and left side of the body above the diaphragm. In 1647 Jean Pecquet (1622-1674) discovered the thoracic duct while working on animal dissection. He was an anatomist of Paris at that time. Pecquet reported his findings in "Experiment nova anatomica" in 1651. The year after that Johannes Van Hoorne, a Dutch professor, he himself independently discovered the thoracic duct and observed in human body.

The lymphatic system is a drainage system which is accessory to venous system. The lymphatic vessels begin as porous blood end of capillaries in tissue spaces. Finally lymph in the lymphatic vessels drains into large veins in the root of the neck. Their course is interrupted by lymph nodes before draining into veins. The lymphatic system also helps the body against invasion by disease causing agents such as viruses, bacteria or fungi. Harmful foreign materials are filtered out by lymph nodes that lie along the network of lymphatic vessels.

Thoracic duct arises as a dilatation known as cisterna chyli. The cisterna chyli lies at the level of L<sub>1</sub>-L<sub>2</sub> deep to the right crus of the diaphragm. It passes through the aortic opening to the right of the aorta. It ascends in the posterior mediastinum between the vertebral column and oesophagus, with the descending thoracic aorta on left side and azygos vein on the right side. At the level of body of the 5<sup>th</sup> thoracic vertebrae, the duct gradually inclines to the left and enters the superior mediastinum. In the superior mediastinum the duct is crossed anteriorly by arch of aorta and then runs posterior to the initial segment of left subclavian artery. Then it ascends along the left border of oesophagus up to the transverse process of 7<sup>th</sup> cervical vertebrae. At the level of C<sub>7</sub> it leaves the oesophagus and arches laterally behind the carotid sheath in front of the apex of pleura and then downwards across the front of the subclavian artery to end by opening into commencing of brachiocephalic vein (junction between left internal jugular vein and left subclavian vein).

With the recent advances by radio imaging techniques like Helical Multi detector-Row computed Tomography, Computerized Tomography scanning (C.T), Ultrasonography, Lymphoscintigraphy, Lymphangiography, Near-Infrared fluorescence imaging, MRI (magnetic resonance imaging), and also catheterization of thoracic

duct are being successfully under taken to demonstrate the course of the thoracic duct.

#### AIMS AND OBJECTIVES

The aim of the present study is to explore the formation, course, tributaries, termination and its possible variations of the thoracic duct. Any operation in the posterior mediastinum carries the risk of damage to thoracic duct or its tributaries. The duct is partially vulnerable in the upper part of the chest in any procedure involving mobilization of the aortic arch, left subclavian artery or oesophagus.

Thoracic duct injury is a rare but serious complication following chest surgeries and major neck dissections. Clinically, it can present as cervical chylous fistula, chylothorax, chylopericardium, chyloma, chylous cyst. Without treatment, the mortality is up to 50% and thus, early aggressive therapy is indicated.

Chylous fistula- a leak of chyle from a lymph vessel to the skin surface, a complication of radial neck dissection when the thoracic duct is injured.

Chylothorax- the presence of lymphatic fluid in the thoracic cavity. The main cause of chylothorax is tumor infiltration of thoracic-mediastinal lymph node structures, traumas in the thoracic-mediastinal region.

Chylopericardium- the presence of effused chyle in the pericardium. This occurs because of lymphangio-dysplasia or after trauma.

Chyloma - collection of chyle at the level of mesentery, along the course of thoracic duct.

Chylous cyst (it is an ampulla shaped dilation at the beginning of the thoracic duct).

Hence, in the present study, special attention is given to the knowledge of formation, course, tributaries, termination and possible variations of the thoracic duct in detail.

#### MATERIALS AND METHODS

The study was carried on 90 adult cadavers. These cadavers were from department of Anatomy Dr. Pinnamaneni Siddhartha Institute of

Medical Sciences & Research Foundation, Chinnoutpalli. PES medical college, Kuppam, ASRAM Medical college Eluru.

The adult cadavers were injected with preservative fluids by body injectors, through femoral artery and then placed in a tank solution. The approximate age and sex were noted.

S.no	Age	Number of cadavers	Males	Females
1	Adults	90	80	10

Dissection of thoracic duct was performed according to the **Cunningham's manual of anatomy, volume -2 & 3** to expose the thoracic duct formation, course, tributaries and its termination.

**Procedure:**

1. In the neck the thoracic duct is traced in the posterior triangle and after exposing all the contents of the posterior triangle the large veins (left internal jugular vein and left subclavian vein). The termination of thoracic duct is traced and photographed.
2. The chest cavity was opened and lungs, heart are removed and the structures in the posterior mediastinum are identified and the thoracic duct was traced up to the neck.
3. The abdomen was opened, the intestines are removed. Structures in the posterior abdominal wall are identified and traced. All the lymphatic ducts are identified, the cisterna chyli, thoracic duct along with its tributaries till it disappears through the aortic opening are traced.
4. All the variations in the formation, course, tributaries and termination at different levels are traced and photographed.

**Materials:**

The following instruments are required for doing dissection and making measurement.

- Surgical knife
- Scissors
- Sharp & blunt forceps
- Compass box
- Bone cutter
- Twine thread and scale
- Digital camera

**REVIEW OF LITERATURE**

Kaur D, Jain M (2012) reported a case in the thoracic duct in the cervical portion of a male cadaver. The thoracic duct, while arching laterally above the clavicle, was coursing posterior to the vertebral vein but anterior to the vertebral artery; it normally passes anterior to both the vertebral vein and artery. After coursing posterior to the vertebral vein, the thoracic duct divided into two branches that drained separately, one at the angle between the internal jugular vein and subclavian vein, and the other into the subclavian vein.

Kiyonaga M, Mori H, et al., (2012) evaluated the normal anatomy of the thoracic duct and cisterna chyli obtained by axial and multiplanar reformation (MPR) images of 1mm slice thickness using multidetector row CT (MDCT). The axial and coronal images of thoracoabdominal images is obtained in 50 patients. The patient with malignant neoplasms, inflammation or vascular diseases and those with a history of thoracoabdominal surgery. The thoracic duct is divided into three anatomical sections: the upper, middle, lower. They evaluated the degree of visualization and the maximum size of the thoracic duct, and also evaluated the visualization, maximum size, configuration and location of cisterna chyli.

Nayak B Satheesha, et.al (2011) found a looped thoracic duct during routine dissection for undergraduate medical students, they found variations of azygos vein and thoracic duct in a male cadaver, aged approximately 65 years. The thoracic duct divide into two branches at the level of T5 vertebra and the two branches joined each other to form a loop with a diameter of 2.5cm. The course and relations of the thoracic duct thereafter were usual.

Pena E, Zuniga J (2009) found a variation of thoracic duct at the Department of Morphology, University del Valle, and Colombia, it considered of an aberrant termination or drainage of the thoracic lymph duct. Normally, this duct ascends in the thorax behind the esophagus, gradually diverges towards the left side of the neck and ends in the left jugulo-subclavian confluent, either in the internal jugular vein or in the subclavian vein. In the case of this cadaver, the

thoracic duct diverged towards the right side of the neck to end in the right internal jugular vein.

Arnoud T, Van Goor, Robert Kroger et, al (2007) reported percutaneous embolization of the thoracic duct through catheterization of the retroperitoneal lymph vessels in two patients in whom conservative management for cervical chylous fistula failed, underwent lymphangiography with opacification of the thoracic duct, followed by radioguided catheterization and embolization. Embolization was successful in both patients. In one patient the procedure repeated once to stop the chylous drainage.

V.R. ANU, R.Rajalakshmi et, al (2006) reported a case of duplication of thoracic duct with a rare lymphatico-venous communication was found. The thoracic duct duplicated at the level of T12 vertebra. Normally thoracic duct opens into the junction of left internal jugular vein. On the right side of the neck, the lymphatic duct conveys the lymph from head and neck, the upper extremity and the right side of the thorax to the right innominate vein. Here, the duplicated thoracic duct on th left side opened directly into the inferior vena cava.

**RESULTS**

The present work on **“DUPLICATION OF THORACIC DUCT IN CADAVERS IN SOUTH INDIAN POPULATION”** was done on 90 adult cadavers of unknown age groups. The observations are recorded according to the proforma given below.

**TOTAL NUMBER OF CADAVERS DISSECTED: TABLE NO. 1**

S.No	Sex	Total No. of bodies
1	Male	80
2	Female	10

**DUPLICATION OF THORACIC DUCT:**

In the present study the duplication of thoracic duct was seen at different vertebral levels. The thoracic duct divides into right and left trunks at the level of T<sub>7</sub>, and unites at the level of T<sub>6</sub>. Again it divides into right, left and middle trunks. The right and left trunks unites at the level of T<sub>4</sub>. The middle trunk gets fused with left trunk at the level of T<sub>3</sub>.

The thoracic duct divides into right and left trunks at the level of T<sub>6</sub>, and unites at the level of T<sub>5</sub>. It again divides into right and left trunks at the level of T<sub>3</sub> and unites at the level of T<sub>2</sub>.

The thoracic duct divides into right and left trunks at the level of T<sub>10</sub>, and unites at the level of T<sub>9</sub>.

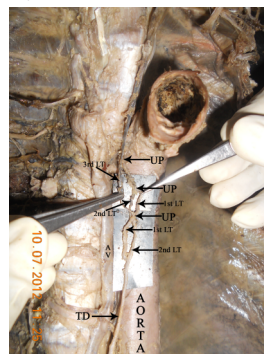


FIG. 1

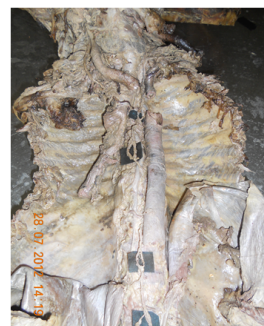

FIG. 2

**DISCUSSION**

Present work "ANATOMY OF HUMAN THORACIC DUCT" ("**Duplication of thoracic duct in cadavers of south Indian population**") was done on 90 adult cadavers of unknown age groups.

The following books were referred in order to discuss the preceding observations.

**COURSE OF THE THORACIC DUCT:**

According to **GRAY'S anatomy** 39<sup>th</sup> edition by **HENRY GRAY** the thoracic duct extends from the second lumbar vertebra to the base of the neck. Starting from the superior pole of the confluence near the lower border of the twelfth thoracic vertebra, it traverses the aortic aperture of the diaphragm, then ascends the posterior mediastinum, right of the midline, between the descending aorta (on its left) and azygos vein (on its right). At the level of fifth thoracic vertebral body, the duct gradually inclines to the left, enters the superior mediastinum and then ascends to the thoracic inlet along the left border of the oesophagus. In this part of its course the duct is first runs posterior to the initial segment of the subclavian artery, in close contact with the mediastinal pleura passing into the neck, it arches laterally at the level of the transverse process of seventh cervical vertebra. Finally, the duct descends anterior to the arched cervical first part of the left subclavian artery and by opening into the junction of the left subclavian vein and internal jugular vein.

According to **HOLLINSHEAD**, in the posterior mediastinum the thoracic duct lies on the anterior surface of the vertebral column behind the oesophagus and between the aorta and the azygos vein, and ordinarily in front of the right intercostals branches of the aorta. In the lower portion it typically lies somewhat to the right to the midline, but at about the level of the aortic arch crosses to the left to lie on the left side of front of the vertebral column, and then ascend along the medial side of the left subclavian artery to pass into neck, in front of the left vertebral artery and vein, and then curves downward in front of the subclavian artery to open into the left subclavian vein or the angle between this and the internal jugular vein.

According to **T.S. RANGANATHAN**, the thoracic duct starts from the upper end of the cisterna chyli opposite the lower border of the twelfth thoracic vertebra. Enters the thorax through the aortic opening of the diaphragm and ascends up through the posterior mediastinum and posterior part of the superior mediastinum and ends in the root of the neck by joining with internal jugular vein.

According to **DATA**, the thoracic duct begins from the upper end of the cisterna chyli at the lower border of T<sub>12</sub> and enters the thorax usually through the aortic opening of the diaphragm. It passes upwards in the posterior mediastinum behind the oesophagus. Opposite to T<sub>5</sub> the thoracic duct inclines to the left and then runs upwards in the superior mediastinum along the left edge of oesophagus. At the root of the neck, it arches laterally opposite the transverse process of C<sub>7</sub> and finally turns downwards to terminate in the angle formed by the junction of the left internal jugular vein and left subclavian vein.

According to **G.J. ROMANES**, the thoracic duct where it leaves the cisterna chyli to enter the thorax on the right of the aorta. In the posterior mediastinum the thoracic duct lies between the aorta and the azygos vein, at first posterior to the diaphragm and then to the oesophagus. At the arch of the aorta, the duct passes obliquely behind the oesophagus to reach the left side. The duct then ascends between the oesophagus and the left pleura to the root of the neck. Here it arches laterally and downwards to enter the junction of the internal jugular vein and subclavian veins.

According to **SNELL**, clinical anatomy by regions, the thoracic duct ascends through the aortic opening in the diaphragm, on the right side of the descending aorta. It gradually crosses the median plane behind the oesophagus and reaches the left border of the oesophagus at the level of the lower border of the body of fourth thoracic vertebra. It then runs upward along the left edge of the oesophagus to enter the root of the neck. Here, it bends laterally behind the carotid sheath and in front of the vertebral vessels. It turns downwards in front of the phrenic nerve and crosses the subclavian artery to enter the beginning of the left brachiocephalic vein.

According to **SAMAR MITRA**, the course of thoracic duct is of two parts. Thoracic part and cervical part. Thoracic part, after entering the thorax through the aortic opening of the diaphragm, it ascends in the

posterior mediastinum, in front of the vertebrae lying on the right of the descending thoracic aorta up to T5 vertebra. It then goes to the left behind the oesophagus and left root of the lung up to the lower border of T4 vertebra where it enters the superior mediastinum, it ascends along the left margin of the oesophagus up to the upper border of T1 vertebra. Cervical part, it enters neck through the thoracic inlet and ascends along the left margin of the oesophagus up to the level of transverse process of C7 vertebra, where it arches is 3cm above the sterna end of the clavicle. Finally bends in front of the medial margin of the scalenus anterior and 1<sup>st</sup> part of subclavian artery to end in the beginning of the left brachiocephalic vein.

According to **MOORE, DALLEY, AGUR**, the thoracic duct ascends upwards and then enter into thorax to enter the left venous angle.

According to **Neeta V Kulkarni**, thoracic duct course is divided into three parts 1) abdominal, 2) thoracic, 3) cervical.

Abdominal part- the thoracic duct begins at the continuation of cisterna chyli and enters the thorax through the aortic opening of the diaphragm.

Thoracic part- in the posterior mediastinum, the thoracic duct ascends to the right of the midline lying on the vertebral bodies. On reaching the level of the fifth thoracic vertebra it gradually inclines to the left and enters the superior mediastinum at the left side of the sterna angle.

The cervical part of thoracic duct arches laterally at the level of transverse process of the seventh cervical vertebra. Anteriorly the arch is related to the carotid sheath and its contents.

According to **FARUQI, KHAN**, thoracic duct ascends from the upper part of the cisterna chyli and enters the thorax through the aortic hiatus. It ascends to the right of midline till it reaches the level of the sterna angle. During this part of the course it lies anterior to the lower thoracic vertebral bodies, posterior to the oesophagus to the right of the descending thoracic aorta and to the left azygos vein. At the sterna angle it turns to the left and then ascends to the left of midline to reach the root of neck. At the level of 7<sup>th</sup> cervical vertebra it again turns to left to drains into venous blood at the junction of left internal jugular vein and left subclavian vein.

According to **D.J. du Plessis**, thoracic duct leaving the cisterna, the duct passes through the aortic orifice of the diaphragm, having the azygos vein on its left. It runs up to the posterior mediastinum, having the aorta on its left side reaching the left side of the 5<sup>th</sup> thoracic vertebra, having crossed behind the oesophagus. It now runs up along the left border of oesophagus, medial to the pleura and behind the left subclavian artery into the neck. In the neck the duct forms an arch which reaches as high as the 7<sup>th</sup> cervical vertebra. As the duct arches to the left it also crosses the scalenus anterior and phrenic nerve and the transverse cervical and supra scapular arteries.

In the present study, the thoracic duct was always passes through the aortic opening to the right of the aorta. It ascends in the posterior mediastinum between the vertebral column and oesophagus, with the descending thoracic aorta on left side and azygos vein on the right side. At the level of body of the 5<sup>th</sup> thoracic vertebrae, the duct gradually inclines to the left and enters the superior mediastinum. In the superior mediastinum the duct is crossed anteriorly by arch of aorta and then runs posterior to the initial segment of left subclavian artery. Then it ascends along the left border of oesophagus up to the transverse process of 7<sup>th</sup> cervical vertebrae. At the level of C<sub>7</sub>, it leaves the oesophagus and arches laterally behind the carotid sheath in front of the apex of pleura and then downwards across the front of the subclavian artery to end by opening into commencing of brachiocephalic vein (junction between left internal jugular vein and left subclavian vein).

The following books were referred in order to discuss the preceding observations.

- **CUNNINGHAM'S MANUAL OF PRACTICAL ANATOMY** by **G.J. ROMANES VOL.II, THORAX AND ABDOMEN, 15<sup>TH</sup> EDITION.**
- **GRAY'S ANATOMY 39<sup>TH</sup> EDITION, THE ANATOMICAL BASIS OF CLINICAL PRACTICE** EDITOR-IN-CHIEF **SUSAN STANDRING.**
- **ANATOMY FOR SURGEONS VOL.II, THORAX AND**

**ABDOMEN** by HENRY HOLLINSHEAD, III PRINTING.

- **GRANT'S METHOD OF ANATOMY, 11<sup>TH</sup> EDITION** by JOHN V. BASMAJIAN AND CHARLES E. SLONECKER.
- **CLINICALLY ORIENTED ANATOMY** by KEITH L. MOORE, ARTHUR F. DALLEY, 4<sup>TH</sup> EDITION.
- **LAST'S ANATOMY REGIONAL AND APPLIED, 10<sup>TH</sup> EDITION** by CHUMMYS. SINNATAMBY.
- **CLINICAL ANATOMY BY REGIONS** by RICHARD S. SNELL, 8<sup>TH</sup> EDITION.
- **ANATOMY VOL.I** by SAMAR MITRA.
- **MANUAL OF PRACTICAL ANATOMY** by NAFIS AHMAD FARUQI, AIJAZ AHMED KHAN.
- **LEE Mc GREGOR'S Synopsis of SURGICAL ANATOMY** by G.A.G. DECKER, DJ du PLESSIS.
- **A TEXT BOOK OF HUMAN ANATOMY** by T.S RANGANATHAN.
- **ESSENTIALS OF HUMAN ANATOMY VOL.I** by DATTA.
- **CLINICAL ANATOMY FOR STUDENTS PROBLEM SOLVING APPROACH** by NEETA V KULKARNI.

### SUMMARY AND CONCLUSION

The materials of present work consist of **90** human cadavers were dissected for the present work.

The anatomy of thoracic duct in human beings has been studied with particular reference to

- Duplication of thoracic duct

Out of **90** cadavers dissected the following variations are observed. Cisterna chyli was absent in two male cadavers.

Three cadavers showed duplication of thoracic duct at different vertebral levels.

Out of **90** cadavers the length was varying from 40 to 44 cm in both male and female cadavers.

### DUPLICATION OF THORACIC DUCT:

In the present study the duplication of thoracic duct was seen at different vertebral levels in 75 cadavers out of 90 cadavers.

The thoracic duct divides into right and left trunks at the level of **T<sub>7</sub>** and unites at the level of **T<sub>6</sub>**. Again it divides into right, left and middle trunks. The right and left trunks unites at the level of **T<sub>6</sub>**. The middle trunk gets fused with left trunk at the level of **T<sub>5</sub>** (FIG.1)

The thoracic duct divides into right and left trunks at the level of **T<sub>6</sub>** and unites at the level of **T<sub>5</sub>**. It again divides into right and left trunks at the level of **T<sub>3</sub>** and unites at the level of **T<sub>2</sub>**. (FIG. 2)

The thoracic duct divides into right and left trunks at the level of **T<sub>10</sub>** and unites at the level of **T<sub>9</sub>**. (FIG. 2)

### REFERENCES:

1. Anu VR, Rajalakshmi R, Latha VP, Mangala K. A rare lymphatico-venous communication associated with duplication of thoracic duct. *Int. J. Morphol.* 2006; 24 (2):155-158.
2. Langford RJ, Daudia AT, Malins TJ. A morphological study of the thoracic duct at the jugulo-subclavian junction. *J Craniomaxillofac Surg.* 1999; 27(2):100-104.
3. Zorzetto NL, Ripari W, De Freitas V, Seullner G. Anatomical observations on the ending of the human thoracic duct. *J Morphol* 1977; 153(3):363-369.
4. Kaur D, Jain M, Dhall U, Singh K. An unusual course of the thoracic duct in relation to the vertebral vessels. *Singapore Med J* 2012; 53(1):1-2.
5. Pena E, Zuniga J. An anatomical variation: the aberrant termination of the thoracic duct. *Biomedica.* 2009; 29(2):204-208.
6. Kinnaert P. Anatomical variations of the cervical portion of thoracic duct in man. *J. Anat.* 1973; 115(1): 45-52.
7. Davis HK. Statistical study of thoracic duct in man. *American journal of Anatomy.* 1915; 17: 211-244.
8. Greenfield J. & Gottlieb M. I. Variations in the terminal portion of the human thoracic duct. *Archives of Surgery.* 1956; 73: 955-959.
9. Kausel HW, Reeve TS, Stein AA, Alley RD. & Stranahan A. Anatomic and pathologic studies of the thoracic duct. *Journal of Thoracic Surgery.* 1957; 34: 631-642.
10. Parsons FG. & Sargent PWG. On the termination of the thoracic duct. *Lancet.* 1909; 1: 1173-1174.
11. Akcali O, Kiray A, Ergur I, Tetik S, Alici E. Thoracic duct variations may complicate the anterior spine procedures. *Eur Spine J.* 2006; 15: 1347-1351.
12. Chen H, Shoumura S, Emura S. Bilateral thoracic ducts with coexistent persistent left superior vena cava. *Clin Anat.* 2006; 19:350-353.
13. Loukas M, Wartmann CT, Louis RG Jr, Tubbs RS, Salter EG, Gupta AA, Curry B. Cisterna chyli: A detailed anatomic investigation. *Clin Anat.* 2007; 20:683-688.