



INCIDENCE OF JEJUNOGASTRIC INTUSSUSCEPTION FOLLOWING GASTRIC SURGERY IN OUR HOSPITAL

Prof Dr. T. Karunaharan*

M.S.,fics,fiages Professor, Department Of General Surgery, Kapv Govt. Medical College, Tiruchirapalli *Corresponding Author

DR.V. Sujatha

M.S Assistant Professor, Department Of General Surgery, Kapv Govt. Medical College, Tiruchirapalli

Dr. D. Uma

M.s Assistant Professor, Department Of General Surgery, Kapv Govt. Medical College, Tiruchirapalli

ABSTRACT

INTRODUCTION: Jejunogastric intussusception as a complication following gastrectomy occurs at an incidence of 0.1%. It follows several types of gastric surgeries like Billroth 2 and gastro jejunostomy. The mortality of the patient usually confirms to the 10% range but a high mortality of 50% has been reported in cases of delayed diagnosis paired with late intervention. In order to bypass the morbidity of the condition timely surgical intervention is the rule of the day. Though the history of gastric surgery may point towards the diagnosis, preoperative anticipation or the same has proven to be difficult in most of the cases

AIMS AND OBJECTIVES: To study the incidence of jejuno gastric intussusception following gastric surgery in KAPV medical college Tiruchirappalli during 10 years period from 2006 to 2016. The need for early intervention to prevent mortality and investigations needed to diagnose intussusception.

METHODS AND MATERIALS: 50 patients who underwent gastrojejunostomy in KAPV medical college Tiruchirappalli during the period 2006 to 2016 were taken up for study. . Patient demographics, clinical presentation, diagnosis, investigations, operative notes, management and histopathology reports were reviewed and data was collected from case records from medical records department.

RESULTS AND OBSERVATIONS: There were 5 cases of JGI. All were males. The mean age at presentation was 54.69 years (range 46-62). All patients presented with hematemesis or coffee ground vomiting. In addition, 3 patients had pain abdomen and 2 patients had malena. . All patients underwent surgical management. Most common type was Type II (efferent loop) seen in 3 patients. Type III (combined type) was seen in 1 patient. One patient had Type I (afferent loop).

CONCLUSION: JGI is a rare complication after gastrojejunostomy. Upper gastrointestinal endoscopy is diagnostic. Ultrasound and computed tomography of abdomen can of additional help. This complication can occur years after surgery. High index of suspicion is required for diagnosis. Prompt surgical intervention, still remains the main stay of treatment

KEYWORDS : intussusception,gastrojejunostomy,laparotomy,endoscopy

INTRODUCTION

Intussusception represents 90% of patients in children and adult intussusception occur only 5% of all intussusceptions . In contrast to intussusceptions in children, a demonstrable etiology is found in 70% to 90% of cases in the adult population . Among them, jejuno gastric intussusception (JGI) is a rare complication of all types of gastric resection and occurs in less than 0.1% of gastric resection . Additionally, JGI is potentially lethal complication of gastrectomy or gastrojejunostomy. The mortality rate of this condition is as high as 50% if surgery is delayed for more than 48 hours . The usual kaleidoscope of presentation involves upper gastrointestinal symptoms like epigastric pain, vomiting and haematemesis. A previous history of gastric surgery narrows down the suspicion to jejuno gastric intussusception in the early stages of the presentation itself. Such a diagnosis ushers in an emergency laparotomy as immediate surgical intervention is the corner stone of the management of jejuno gastric intussusception. In lieu with the intraoperative findings, reducing or resecting along with revision of previously performed anastomosis becomes the modus operandi of the surgeon. Jejunogastric intussusception as a complication following gastrectomy occurs at an incidence of 0.1%. It follows several types of gastric surgeries like billroth 2 and gastro jejunostomy. The mortality of the patient usually confirms to the 10% range but a high mortality of 50% has been reported in cases of delayed diagnosis paired with late intervention. In order to bypass the morbidity of the condition timely surgical intervention is the rule of the day. Though the history of gastric surgery may point towards the diagnosis, preoperative anticipation or the same has proven to be difficult in most of the cases.

AIMS AND OBJECTIVES

1. To study the incidence of jejuno gastric intussusception following gastric surgery in KAPV medical college Tiruchirappalli during 10 years period from 2006 to 2016
2. the need for early intervention to prevent mortality
3. Investigations needed to diagnose intussusception

MATERIALS AND METHODS

50 patients who underwent gastrojejunostomy in KAPV medical college Tiruchirappalli during the period 2006 to 2016 were taken up for study. . Patient demographics, clinical presentation, diagnosis, investigations, operative notes, management and histopathology reports were reviewed and data was collected from case records from medical records department. Jejuno gastric intussusception was defined as invagination of afferent or efferent or both loops of jejunum through the gastrojejunostomy stoma.

INCLUSION CRITERIA

1. patients who underwent gastrojejunostomy
2. details of the patient available
3. patients willing for regular followup

EXCLUSION CRITERIA

1. un co-operative patients

OBSERVATIONS AND RESULTS

There were 5 cases of JGI. All were males. The mean age at presentation was 54.69 years (range 46-62). All patients presented with hematemesis or coffee ground vomiting. In addition, 3 patients had pain abdomen and 2 patients had malena. On abdominal examination, two patients had diffuse abdominal tenderness and palpable lump was present in 1 case. The time duration from gastrojejunostomy was 5 to 25 years. Upper gastrointestinal endoscopy was diagnostic in 4 cases. All patients underwent surgical management. Most common type was Type II (efferent loop) seen in 3 patients. Type III (combined type) was seen in 1 patient. One patient had Type I (afferent loop).

In 2 patients, a gastrostomy was done to facilitate the reduction of intussusception followed by fixation of the jejunal loops. In 2 patients, the gastrojejunostomy was taken down along with resection of the gangrenous jejunum and a Roux- en- Y reconstruction was done. In 1 patient, distal gastrectomy was required as the intussusception could not be reduced and a Roux- en- Y reconstruction was done for maintaining intestinal continuity. Two patients had postoperative

wound infection. On median follow-up of 6 years, there were no recurrences. There was no mortality.

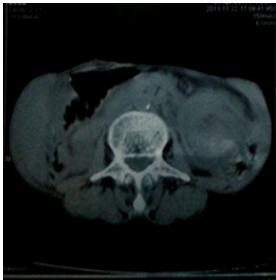Table 1: Type of jejuno gastric intussusception

Type of jejuno gastric intussusception	Number of patients (N=5)
Type I (afferent loop)	1
Type II (efferent loop)	3
Type III (combined type)	1

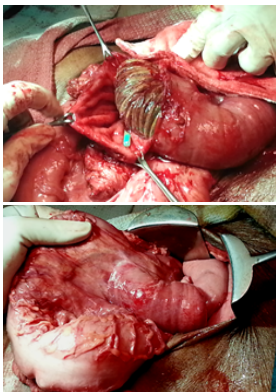
Table 2: Surgical treatment

	Number of patients (N=5)
Reduction after Gastrostomy and fixation of jejunal loops	2
Jejunal resection with Roux- en- Y reconstruction	2
Distal gastrectomy with Roux- en- Y reconstruction	1

A computed tomography showed a distended stomach containing a nonhomogeneous mass (Figure 1)



At laparotomy, an ischemic efferent loop was found to be intussuscepted in a retrograde manner into the gastric lumen (Figures 2 and 3).



Following reduction of this jejunal segment, resection with Roux-en-Y anastomosis was performed due to ongoing necrosis

DISCUSSION

In this article, we report our experience of retrograde jejuno gastric intussusception (JGI) after gastrojejunostomy over 10 years

Bozzi reported the first case of JGI in a patient with gastrojejunostomy.¹ Literature review showed that just over 200 cases have been reported, most of them being case reports and small series.²⁻⁵ The reported incidence is less than 0.1% to 0.15%.^{7,8} Retrograde intussusception was also reported in patients after Billroth-I reconstruction, Billroth-II reconstruction, previously placed gastrostomy tubes, pancreaticojejunostomy and total gastrectomy with Roux-en-y- anastomosis.^{2,4,9-11} Over a period of 72 years, only 16 cases were reported at Mayo clinic.¹²

Shackman described three anatomic types of JGI, according to the invaginated loop.^{6,13} Type I is afferent loop invagination or antegrade intussusception. Type II is efferent loop invagination or retrograde or ascending intussusception and type III is intussusception of both loops or combined intussusceptions. Few authors describe Type IV, which consists of over intussusception through a braun side-to-side jejunojejunal anastomosis.^{3,5}

The etiopathogenesis and mechanism of JGI are unclear and poorly understood.^{2,3,14,15} The major theories suggested are functional and

mechanical. Robertson DS and Weder C suggested the functional theory that is most widely accepted. The functional theory states that disordered motility with functional hyperperistalsis triggered by spasm or hyperacidity causes JGI.^{14,16} Other factors are adhesions, long mesentery, gastric derangements, sudden increase in abdominal pressure and derangements in the stomal function and retrograde peristalsis 2,14,15,17,18

In reported literature, the interval between JGI after gastric operation varied from 5 days to 55 years.^{8,14} In our study, the duration was 5 to 25 years. Clinically JGI can present in acute or chronic form. In the acute form, patients present with colicky pain in epigastrum, associated with nausea and vomiting. Severe haemetemesis can result from secondary ulceration and due to compromised jejunal vascular supply.^{3,19} Features of gastric outlet obstruction or high intestinal obstruction can be present. Epigastric tenderness and a palpable abdominal mass and signs of high intestinal obstruction are additional findings on examination.^{2,20} In our series, all patients presented with haemetemesis or coffee-ground vomiting. Epigastric pain was present in 3/5 patients and a palpable lump in 1/5 patients. High index of suspicion is required for diagnosis in a patient with previous gastric surgery as the clinical picture can be non-specific. In the chronic form, spontaneous reduction occurs with milder and transient symptoms.¹⁴ JGI can be diagnosed by imaging. Early diagnosis and the acute form is of paramount importance.³ Plain radiograph may reveal gastric fluid level with a filling defect.¹⁵ A homogenous soft tissue density at the left upper quadrant may represent small bowel in the stomach.^{4,21} A water soluble upper GI contrast study or barium study will reveal "coiled spring" appearance and a central defect in the stomach.^{4,15} Upper gastrointestinal endoscopy is diagnostic and therapeutic in selected cases.¹⁵ It is the diagnostic procedure for patient with haemetemesis.³ UGI scopy will visualise the the intussuscepted jejunal loop in stomach, however viability cannot be assessed due to limited visibility.²² It can be mistaken as an immobile clot or a bezoar or tumour.^{3,13} Provocation of JGI during endoscopy by the use of jet of water directed towards the anastomotic stoma may be diagnostic of the chronic form.² Endoscopic reduction of JGI is contraindicated when peritoneal signs are suspected. Endoscopic reduction is associated with recurrence.²⁴ Ultrasound findings reveal a mass with echogenic center surrounded by concentric echogenic rings with a peripheral rim of hypoechogenicity. On transverse images, this rim has been described as doughnut sign and longitudinal images as pseudo kidney sign.¹⁸ Ultrasound abdomen cannot detect the dilation and obstruction of the intestine in the presence of profuse intestinal gas. Abdominal CT is the most useful procedure for identifying JGI when profuse abdominal gas prevents US from visualizing invagination.²⁵ CT findings of intussusception include a soft tissue mass with a "sausage" or target appearance.¹⁸ Additionally, a crescent-shaped, eccentric low-attenuation component representing the entrapped mesenteric fat is typically present.

Most reported cases of JGI were diagnosed at surgery. In all types of acute JGI immediate surgical treatment is necessary. Surgical options include manual reduction, resection of gangrenous bowel, anastomosis revision and take down of anastomosis and conversion to Roux-en-Y reconstruction depending on intra-operative findings.^{14,19} Reduction by gentle traction with or without opening the stomach should always be attempted. When there is strangulation with gangrenous bowel resection will be mandatory.^{6,15,25,26} Laparoscopic examination with reduction of of the intussusception via a minilaparotomy wound.²⁴

To prevent recurrence few authors suggested fixation of jejunum to the adjacent tissue, mesocolon, colon, stomach or falciform ligament.^{14,24,27} The role of fixation has been debated as the chance of recurrence is rare.^{6,12} Bettman found only two recurrences among all the reported cases.²⁸ High mortality (10 to 50%) associated with this condition is due to poor preoperative condition of the patient, delay in diagnosis and surgical exploration.^{6,29}

CONCLUSION

JGI is a rare complication after gastrojejunostomy. Upper gastrointestinal endoscopy is diagnostic. Ultrasound and computed tomography of abdomen can of additional help. This complication can occur years after surgery. High index of suspicion is required for diagnosis. Prompt surgical intervention, still remains the main stay of treatment.

REFERENCE

1. Bozzi E. Annotation. Bull Acad Med. 1914;122:3-4.
2. Archimandritis AJ, Hatzopoulos N, Hatzinikolaou P, Sougioultzis S, Kourtasas D, Papastratis G, et al. Jejunogastric intussusception presented with hematemesis: a case presentation and review of the literature. BMC Gastroenterol. 2001;1:1.
3. Lee SH, Kwon IG, Ryu SW, Sohn SS. Jejunogastric intussusception: a rare complication of gastric cancer surgery. Int J Clin Exp Med. 2014;7:4498-502.
4. Su MY, Lien JM, Lee CS, Lin DY, Tsai MH. Acute jejunogastric intussusception: report of five cases. Chang Gung Med J. 2001;24:50-6.
5. Gopal R, Elamurugan TP, Hage S, Muthukumarassamy R, Kate V. Retrograde jejunogastric intussusception following Braun's jejunojejunostomy. World J Clin Cases. 2014;2:24-6.
6. Salem MH, Coffman SE, Postlethwait RW. Retrograde intussusception at the gastrojejunal stoma. Ann Surg. 1959;150:864-71.
7. Conklin EF, Markowitz AM. Intussusception, a complication of gastric surgery. Surgery. 1965;57:480-8.
8. Marx WJ. Reduction of jejunogastric intussusception during upper gastrointestinal examination. AJR Am J Roentgenol. 1978;131:334-6.
9. Shiffman MA, Rappaport I. Intussusception following gastric resection. Report of five cases. Report of five cases and literature review. Am Surg. 1966;32:715-24.
10. Whipple OC, Stringer EF, Senkowski CK, Hartley M. Retrograde intussusception of the efferent limb after a pancreaticojejunostomy. Am Surg. 2003;69:353-5.
11. Pelosof L, Ringold DA, Kuo E, Bhalla S, Whinney R, Zuckerman GR. Retrograde jejunogastric intussusception caused by a migrated gastrostomy tube. Endoscopy. 2007;39(Suppl 1):E262-3.
12. Waits JO, Beart RW, Charboneau JW. Jejunogastric intussusception. Arch Surg. 1980;115:1449-52.
13. Shackman R. Jejunogastric intussusception. Br J Surg. 1940;27:475-80.
14. Tokue H, Tsushima Y, Arai Y, Endo K. Jejunogastric intussusception: life-threatening complication occurring 55 years after gastrojejunostomy. Intern Med. 2009;48:1657-60.
15. Sharma OP, Gaharwar S. Imaging depiction of retrograde jejunogastric intussusception. Indian J Surg 2013;75(Suppl 1):269-71.
16. Robertson DS, Weder CH. Acute jejunogastric intussusception. Can J Surg. 1968;11:210-4.
17. Bundrick TJ, Turner MA. Retrograde jejunogastric intussusception. Rev Interam Radiol. 1981;6:21-4.
18. Hammond N, Miller FH, Dynes M. Intussusception into the enteroanastomosis after Billroth II gastrectomy and Roux-en-Y jejunostomy: sonographic and CT findings. AJR Am J Roentgenol. 2001;177:624-6.
19. Sahoo MR, Bhaskar V, Mohapatra V. Retrograde jejunogastric intussusception with jejunojejunal intussusception (double telescoping). BMJ Case Rep. 2013;2013:bcr2013008850.
20. Hsu K-F, Chang W-K, Chen C-J. A palpable abdominal mass presenting as acute abdomen. Gastroenterology. 2011;141:e11-2.
21. Samarasam I, Chandran S, Shankar U, George B, Chacko A, Mathew G. Jejunogastric intussusception: an unusual cause of hematemesis. Can J Gastroenterol. 2005;19:735-6.
22. Misra SP, Dwivedi M. Jejunogastric intussusception-a rare cause of recurrent upper gastrointestinal bleeding: case report and review of literature. Trop Gastroenterol. 2007;28:188-90.
23. Rather SA, Dar TI, Wani RA, Khan A. Jejunogastric intussusception presenting as tumor bleed. J Emerg Trauma Shock, 2010;3:406-8.
24. Loi CM, Huang SY, Chen YD, Chen SD, Wu JM, Chen KH. Retrograde jejunogastric intussusception: a case report and review of the literature. Asian J Surg. 2014;pii:S1015-9584(14)00050-5.
25. Hashimoto Y, Akagi S, Sakashita Y, Takamura M, Iwako H, Watadani Y, et al. Usefulness of computed tomography as a preoperative diagnostic modality in a case with acute jejunogastric intussusception. J Gastrointest Surg. 2007;11:1078-80.
26. Kim KH, Jang MK, Kim HS, Lee JH, Lee JY, Park JY, et al. Intussusception after gastric surgery. Endoscopy. 2005;37:1237-43.
27. López-Mut JV, Cubells M, Campos S, Miranda V, Rivera P. Jejunogastric intussusception: a rare complication of gastric surgery. Abdom Imaging. 1998;23:558-9.
28. Betman RB, Baldwin RS. Retrograde intussusception of jejunum: Complication of gastrectomy. J Am Med Assoc. 1933;100:1228.
29. Walstad PM, Ritter JA, Arroz V. Delayed jejunogastric intussusception after gastric surgery: an ever-present threat. Am Surg. 1972;38:172-5.