



HISTOPATHOLOGICAL STUDY OF SALIVARY GLAND NEOPLASMS IN A TERTIARY CARE HOSPITAL IN NORTH TELANGANA

Dr S Srikanth

Associate Professor, Department of Pathology, Prathima Institute of Medical Sciences, Nagunur, Karimnagar, Telangana, India.

ABSTRACT

Introduction: Salivary gland neoplasms are common day to day problem encountered in all age groups irrespective of sex distribution. Apart from neoplastic lesions many inflammatory lesions are also noted in salivary glands.

Materials & Methods: The present study is a retrospective and prospective study done in department of Pathology for a period of two years from January 2015 to December 2017. Clinical history, radiological findings and all other details were considered before diagnosing.

Results: In this study, most cases occurred at 31-40 years of age. Incidence of benign tumors was 72% while that of malignant tumors were 28% overall. Benign tumors of parotid gland were 63.3% and malignant tumors of parotid gland were 36.7%.

Conclusion: Parotid gland was the most common site of origin of both benign and malignant tumors. Pleomorphic adenoma was the most common benign salivary gland tumor and adenoid cystic carcinoma was the most frequent malignant neoplasm. Both benign and malignant tumors were more common in females and the common age group affected was from 31-40 years.

KEYWORDS : Salivary gland, parotid, pleomorphic adenoma.

INTRODUCTION

Salivary gland tumors (SGTs) are a heterogeneous group of neoplasms in the head and neck area. The tumors have complex morphologic appearance and different clinical behavior, which make their diagnosis difficult^{1,2}. These tumors are rare lesions; represent less than 1% of all tumors and 3-6% of all head and neck neoplasms^{3,4}. The annual incidence of salivary gland cancers ranges from 0.5 to 2 per 100,000 in different parts of the world. The major as well as minor salivary glands can give rise to a variety of benign and malignant tumours. The major glands particularly the parotid glands are the most common sites. Majority of parotid gland tumours are benign, while in the other major and minor salivary glands 35-50% of the tumours are malignant. Most of the salivary gland tumours originate from the ductal lining epithelium and the underlying myoepithelial cells; a few arise from acini. Recurrent tumours of the parotid glands, due to their location, are often associated with facial palsy and obvious scarring following surgical treatment.

MATERIALS & METHODS

This is a two years retrospective and prospective study of all SGT biopsies received at our referral teaching hospital. Biodata (age, sex and site) were obtained from laboratory records derived from information provided on histopathology request forms. All specimens were fixed in 10% formalin, then processed into paraffin-embedded sections and stained with hematoxylin and eosin. Special stains (e.g., for mucin) were occasionally employed. All the slides were reviewed by the authors and classified according to the World Health Organization histological typing of tumors (2005).

RESULTS

A total of 40 salivary gland neoplasms were studied during the study period. Out of the 40 specimens, 28 were benign lesions and 12 were malignant lesions. Out of the benign lesions pleomorphic adenoma constituted highest number of cases (20), followed by Warthins, basal cell adenoma, oncocytoma and myoepithelioma. Among malignant lesions Adenoid cystic carcinoma constituted highest number of cases (07), followed by mucoepidermoid carcinoma and epithelial – myoepithelial carcinoma [Table 1]. Age group between 31-40 constituted highest number of cases [Table 2] and females are more affected than males.

Table 1: Showing different tumours in our study

Sl no	Neoplasm	No. of cases
1	Pleomorphic adenoma	20
2	Warthins tumour	03
3	Basal cell adenoma	02
4	Oncocytoma	02
5	Myoepithelioma	01

6	Adenoid cystic carcinoma	07
7	Mucoepidermoid carcinoma	03
8	Epithelial myoepithelial carcinoma	02
Total		40

Table 2: Showing different age groups

Sl no	Age group	No. of cases
1	1-10	02
2	11-20	07
3	21-30	06
4	31-40	18
5	41-50	07
Total		40

DISCUSSION

Salivary glands are divided into major and minor salivary glands. Salivary glands tumors are relatively uncommon, they can be presented as inflammatory lesions, developmental defects and neoplasms but their clinical presentation, morphologic differentiation and relatively unpredictable prognosis tend to attract much of medical interest. Neoplasm of salivary gland may occur at any age. In this study highest number of patients was in the 4th to 5th decade which was 19 patients (28%) and comparable with the findings of Dr. Shazia et al⁵. High male to female ratio has been reported in several other studies^{6,7,8}.

Salivary gland tumors (SGTs) are rare and their annual incidence is <1/100,000 inhabitants, without noticeable geographical gap, and they represent <5% of head and neck tumors. These tumors show a striking range of morphological diversity between different tumor types and sometimes within an individual tumor mass. In addition, hybrid tumors, dedifferentiation and the propensity for some benign tumors to progress to malignancy can confound histopathological interpretation. In India, overall incidence of SGTs can be ascertained from the cancer registry established by Indian Council of Medical Research.[3] However, the geographic area and population covered by these registries are small and perhaps unrepresentative of the Indian population. In addition, there is a limited published literature on SGTs in Indian population.[4]

In this 3-year study, SGTs were found in patients between the ages of 18 and 68 years (mean: 43 years) with slight overall female predominance, male to female ratio of 1:1.8, this finding is similar with the other reports.[7,8]

PA was the most common SGTs, which consists of 60.71% of all tumors and 86.04% of benign SGTs. All epidemiological studies on the SGTs have shown a pronounced predominance of 42%–80% PA.[1,6,7] Histopathological feature shows both epithelial and

mesenchymal differentiation. Epithelial component includes the well-formed ductal structures formed of inner epithelial and outer myoepithelial cells with associated features of spindle, squamous, basaloid, cuboidal, oncocytoid, mucous, sebaceous, round, plasmacytoid, polygonal or clear cells. Squamous differentiation with keratin pearls (positive CK19) was noted in four cases, and in one of the tumors, there was predominant adipose tissue. Cytologic features of epithelial cells were bland, and the mesenchymal component consisted myxoid, hyaline, cartilaginous or osseous differentiation.

The second most common benign tumor of salivary gland was Warthin's tumor (5.07%), which was found only in the males and occurred exclusively in the parotid gland. Smoking habits are the main etiological factor for Warthin's tumor mainly affecting the elderly patients and rarely occurs in <30 years of age, with a peak incidence in the sixth decade of life.[5] The differences in results could be affected by racial, behavioral, geographical and unknown environmental factors. Microscopically, epithelial tall columnar (IHC-somatostatin) with basaloidonococytic cells lining cysts form prominent papillae, the cystic spaces are filled with lymphoid stroma and few show lymphoid follicles.

Adenoid cystic carcinoma (14.94%) was the most common malignant SGT, followed by the mucoepidermoid carcinoma (5.08%). Sando and Subhashraj *et al.*[1] also found adenoid cystic carcinoma the same occurrence 25% and 6.6%, respectively.[1,6] However, Kalburge *et al.* and Ochicha *et al.* found the mucoepidermoid carcinoma as the most frequent malignant tumor (58.53% and 5.12%) ahead of adenoid cystic carcinoma (33.33% and 1.28%).[7,13] Classically, the histopathologic features of adenoid cystic carcinoma include cribriform (50%), tubular (20%-30%) and solid patterns (10%-15%) with most tumors having mixtures of cytoarchitectural patterns. Stroma is eosinophilic, hyalinized or collagenous. The diagnostic feature of this malignancy includes the propensity for perineural invasion, found in >50% of cases in the present study.

Mucoepidermoid carcinoma on microscopy is composed of varying proportions of mucous, epidermoid and intermediate-type cells with cystic or papillary mucin-filled cystic lumens, often have pools of extravasated mucin in surrounding tissue which are strongly positive for mucicarmine stain

CONCLUSION

From this study we want to conclude that parotid gland was the most common site of origin of both benign and malignant tumours. Pleomorphic adenoma was the most common benign salivary gland tumour followed by Warthin's tumor and mucoepidermoid carcinoma was the most frequent malignant neoplasm followed by adenoid cystic carcinoma. Here we present common tumors with their histopathological images which are important in the final diagnosis. This information could help physician, surgeons and pathologists for more accurate diagnosis, management and early treatment reducing the occurrence of complications in any higher centre. The present study was a single institutional experience where analysis of 59 SGTs was carried out. The findings of age, sex, site distribution and pathologic features encountered in our study were in agreement with those studies reported from India and other parts of the world. Although the number of SGTs discussed in this study is small, the findings should contribute in better understanding of the disease. Only a few SGTs based on significantly large number of cases are published from India as very little information is available on the tumors of the head and neck over the last two-three decades and hence prospective studies need to be carried out on bigger samples to better discriminate the influencing factors.

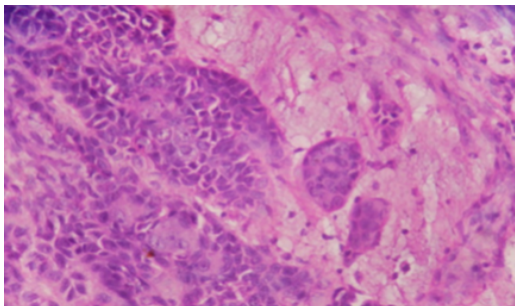


Figure 1: Section showing features of pleomorphic adenoma both epithelial and mesenchymal component [H&E, x40]

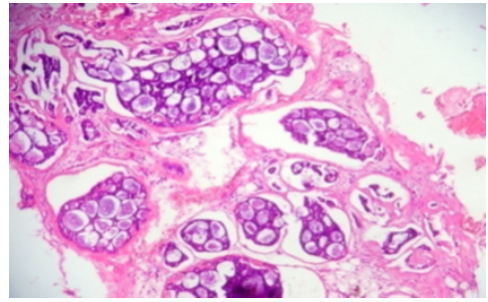


Figure 2: Section showing features of adenoid cystic carcinoma [H&E, X40]

REFERENCES

1. Ansari M. Salivary gland tumors in an Iranian population: a retrospective study of 130 cases. *J Oral Maxillofac Surg.* 2007; 65:2187-94.
2. Jones AV, Craig GT, Speight PM, et al. The range and demographics of salivary gland tumors diagnosed in a UK population. *Oral Oncol* 2008;44, 407-17.
3. Ethumandan M, Davies B, Pratt CA, Puxeddu R, Brennan PA. Primary epithelial submandibular salivary gland tumors- Review of management in a district general hospital setting. *Oral Oncol* 2009;45:173-6.
4. Pons-Vicente O, Almendros-Marqués N, Berini-Aytsés L, Gay Escoda C. Minor salivary gland tumors: A clinicopathological study of 18 cases. *Med Oral Pathol Oral Cir Bucal* 2008;13:E582-8.
5. Histopathological Spectrum of Salivary Gland Tumors: A 10 Year Experience Dr. Shazia Bashir, et al. *Scholars Journal of Applied Medical Sciences* 2013; 1(6):1070-1074.
6. Bradley PJ, McGurk M. Incidence of salivary gland neoplasms in a defined UK population. *Br J Oral Maxillofac Surg.* 2013;51:399-403.
7. Waldron CA, el-Mofty SK, Gnepp DR. Tumors of the intraoral minor salivary glands: A demographic and histologic study of 426 cases. *Oral Surg Oral Med Oral Pathol.* 1988;66:323-33.
8. Neville BW, Damm DD, Weir JC, Fantasia JE. Labial salivary gland tumors. *Cancer.* 1988;61:2113-6.