



LATERAL INTERNAL SPHINCTEROTOMY VERSUS 2% DILTIAZEM GEL LOCAL APPLICATION : A COMPARATIVE STUDY IN TREATMENT OF CHRONIC FISSURE IN ANO

**Yogesh Kumar
Yashaswi**

Senior Resident, Department Of General Surgery, Igims, Patna.

**Pawan Kumar
Jha***

Additional Professor, Department Of General Surgery, Igims, Patna *Corresponding Author

ABSTRACT

Introduction : Anal fissures are commonly encountered in routine clinical practice. Anal fissure has traditionally been treated surgically. Developments in the pharmacological understanding of the internal anal sphincter have resulted in more conservative approaches towards treatment. In this study, we aim to compare symptomatic relief, healing and side effects of topical 2% Diltiazem Gel and Lateral internal sphincterotomy (LIS) in the treatment of chronic fissure in ano.

Material and Methods : In this prospective trial, 40 surgical out patients and/or admitted patients with chronic fissure in ano were randomly divided into Group 1 (Diltiazem Gel) and Group 2 (Lateral Internal Sphincterotomy) with 20 patients in each Group. Patients were followed up at weekly intervals for 6 consecutive weeks and biweekly for subsequent 3 months.

Results : Fissure was completely healed in 90% of patients in Group 1 and 100% in Group 2. The mean duration required for healing of fissure was 5.04 weeks in Group 1 and 3.60 weeks in Group 2. 80% patients were free from pain in Group 1 whereas 85% patients were free from pain in Group 2. No patient had any side effects in either group.

Conclusion : Topical Diltiazem should be considered as first line of treatment in chronic fissure in ano. Lateral internal sphincterotomy should be reserved for patients with relapse and therapeutic failure to prior pharmacological treatment.

KEYWORDS : Anal Fissure , Chemical Sphincterotomy, Lateral Internal Sphincterotomy, Diltiazem .

INTRODUCTION

Anal fissures are considered one of the commonest causes of severe anal pain. An anal fissure is a longitudinal tear or ulcer in the distal anal canal. It is usually located in the posterior or anterior midline and extends from the level of dentate line to the anal verge. Acute fissure is one which presents within 3-6 weeks of symptom onset. It has the appearance of a clean longitudinal tear in the anoderm with little surrounding inflammation. Acute fissure usually heals spontaneously within 6 weeks. A chronic fissure, with more than 6 weeks of symptoms, is usually deeper and generally has exposed internal sphincter fibers at its base. It is frequently associated with a hypertrophic anal papilla at its upper aspect and sentinel pile at its distal aspect. Based on etiology it is classified as primary (idiopathic) or secondary. Secondary fissures are those that occur due to some other pathology such as Crohn's disease, anal tuberculosis, AIDS. Patients usually present with pain during defecation and passage of bright red blood per anus. The precise etiology of anal fissure is unknown. Fissure is most commonly attributed to trauma from the passage of a large hard stool, but it is also seen after acute episodes of diarrhea. Painful fissures are generally associated with involuntary spasm of the internal sphincter with high resting pressure in the anal canal. So it seems that chronic over activity of the internal sphincter may be the cause. Reduction of anal sphincter spasm results in improved blood supply and healing of fissure. Surgical techniques like manual anal dilatation or lateral internal sphincterotomy, effectively heal most fissures within a few weeks^{1,2}, but may result in permanently impaired anal continence. This has led to the research for alternative non-surgical treatment, and various pharmacological agents such as nitrates (glyceryl trinitrate, isosorbide dinitrate), calcium channel blockers (nifedepine, diltiazem) have been shown to lower resting anal canal pressure and heal fissures without threatening anal continence³. The present study compares the effectiveness and side effects of 2% Diltiazem Gel local application and Lateral internal Sphincterotomy in the treatment of chronic fissure in ano.

MATERIAL AND METHODS

This prospective, comparative study was undertaken at Indira Gandhi Institute of Medical Sciences, Patna from December 2016 to November 2017. Forty (40) patients with symptoms of fissure in ano for more than 6 weeks were labeled as having chronic fissure in ano and were enrolled in this study. Inclusion criteria included patients between 20 to 60 years of age of both sexes. Exclusion criteria included children and mentally handicapped patients, recurrent fissures, fissures with hemorrhoids and fistula, fissures associated with malignancies, fissures secondary to specific diseases like Tuberculosis, Crohn's disease etc., and pregnant women. Patients in Group 1 were advised to

apply 1.5 to 2 cms length of gel twice daily at least 1.5 cm into the anus for 6 consecutive weeks. Patients were instructed to wash hands before and after use of gel.

Patients in Group 2 underwent left lateral internal sphincterotomy under spinal anaesthesia. Cases from both Groups were asked to take mild laxatives like cremaffin (milk of magnesia , liquid paraffin) three teaspoons at bedtime, high fiber diet and to use warm sitz baths. Cases were reviewed in OPD weekly for 6 consecutive weeks and biweekly for subsequent 3 months. At each visit questions were asked regarding pain relief, leakage of flatus/faeces or any side effects. Healing was assessed visually and defined as complete disappearance of fissure. Pain was assessed using a pain score chart graded from 0 (almost pain free) to IV (severe pain). The data was collected and analyzed; p-values were calculated using Chi Square test.

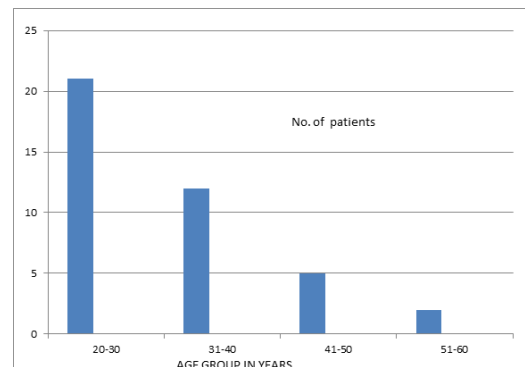


Fig 1 : Age incidence

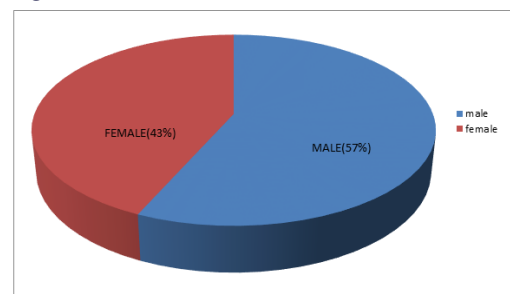


Fig 2 : Sex incidence

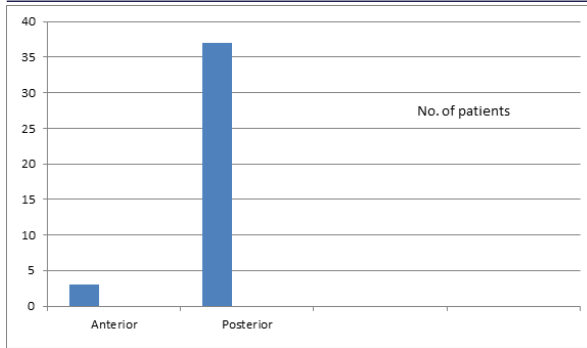


Fig 3 : Site of fissure

Table 1 : Healing at 4 weeks

HEALING	NO. OF PATIENTS	PERCENTAGE
Diltiazem	18	90%
Surgery	20	100%

Table 2 : Pain relief at 3 months

PAIN FREE	NO. OF PATIENTS	PERCENTAGE
Diltiazem	16	80%
Surgery	17	85%

RESULTS

In our study, most of the cases belonged to age group 20-30 years (Fig:1) with slight male preponderance (Fig:2). Majority of the fissures were posterior in location (Fig:3) with sentinel pile present in 46.6% of cases. Cases were followed up weekly for 6 consecutive weeks and biweekly for subsequent 3 months. 90% of patients in Group 1 and 100% of patients in Group 2 had completely healed fissures at the end of 4 weeks (Table:1). 80% of patients in Group 1 who were completely healed with Diltiazem gel application and 85% of patients in Group 2 with LIS were free from pain at the end of 3 months (Table:2). Two patients in Group 1, whose fissure did not heal after 6 weeks of Diltiazem application and remained symptomatic, subsequently underwent lateral internal sphincterotomy and fissure healed in 4 weeks after surgery. The mean duration of healing was comparatively longer in Group 1 (5.04 weeks) than Group 2 (3.60 weeks). No complications were reported in either Group. Comparison between Group 1 and Group 2 did not show any difference in pain relief ($p=0.5261$) or fissure healing ($p=0.0679$).

DISCUSSION

Anal fissure is a very common problem across the world. It causes considerable morbidity and adversely affects the quality of life. Anal fissure is usually encountered in young or middle aged adults^{4,5} and is equally common in both sexes⁶. It is commonly found in the posterior position, although anterior fissure is comparatively common in females⁶.

Therapy focuses on breaking the cycle of pain, spasm, and ischemia thought to be responsible for the development of fissure in ano.

Operative management includes anal dilatation and lateral internal sphincterotomy. Lateral internal sphincterotomy (LIS) is perhaps the operation of choice to perform in patients with chronic anal fissure needing surgical treatment. Postoperative management is simple and rate of healing is faster. However complication such as permanent anal incontinence is associated with the surgery.

Chemical sphincterotomy is now the first line of treatment in many centers⁷⁻¹⁰. Calcium channel blockers like nifedipine and diltiazem have been shown to lower resting anal pressure¹⁰, promote fissure healing and are associated with good healing rate^{7,11,12}. They are associated with side effects such as headache and perianal dermatitis⁷. Healing rates of chronic anal fissure in various studies ranged from 47% - 80%^{3,10,11,13}, while that seen in our study is 90%. Side effects due to diltiazem ranged from 0%- 10%^{3,10,13} in various studies while no patient developed side effect in our study. In contrast to surgery, chemical sphincterotomy with diltiazem is reversible and therefore unlikely to have adverse effects on continence. Patients who are hypertensive, diabetic and medically unfit for surgery can be recommended treatment with Diltiazem. Though fissure healing rate is comparatively slower with Diltiazem, the trauma caused by surgery

can be avoided and hospital stay is not required. Treatment works out to be very cost effective.

CONCLUSION

Chemical Sphincterotomy with Topical 2% Diltiazem Gel application should be advocated as the first option of treatment for chronic anal fissure. Lateral internal Sphincterotomy (LIS) should be offered to patients with relapse and therapeutic failure of prior pharmacological treatment.

REFERENCES

- [1] Scouten WR et al. Ischemic nature of anal fissure. *British Journal of Surgery*. 1996; 83: 63-65.
- [2] Adriano Tocchi, Gianluca Mazzoni, Michelangelo Miccini, Diletta Cassini, Elia Bettelli, Stefania Brozzetti. Total lateral sphincterotomy for anal fissure. *International Journal of Colorectal Disease*. 2004; 19(3): 245-49.
- [3] Jonas Marion, Scholefield JH, Anal fissure and chemical sphincterotomy. Taylor I, Johnson CD. *Recent advances in Surgery*. Churchill Livingstone, 24th Edition, 2001, 115.
- [4] John Goligher, Anal Fissure, John Goligher, *Surgery of the Anus, Rectum & Colon*. AITBS, 5th Edition, 1992, 150.
- [5] Udawadia T.E., The prophylaxis of fissure in ano. *Indian Journal of Surgery*. 1978; 40(11): 560.
- [6] Boulos PB, Araujo JGC, Adequate internal sphincterotomy for chronic anal fissure: subcutaneous or open technique? *British Journal of Surgery*. 1984; 71 (5): 360-62.
- [7] J. S. Knight, M. Birks, R. Farouk, Topical Diltiazem ointment in the treatment of chronic anal fissure. *British Journal of Surgery*. 2001; 88 (4): 553-56.
- [8] R. Bhardwaj, M. C. Parker, Modern perspectives in the treatment of chronic anal fissures. *Annals of the Royal College of Surgeons of England*. 2007; 89 (5): 472- 78.
- [9] Z Haq, M Rahman, RA Chowdhury, MA Baten, M Khatun, Chemical sphincterotomy – first line of treatment for chronic anal fissure. *Mymensingh Medical Journal*. 2005; 14(1): 88-90.
- [10] E Carapeti, M Kamm, B Evans, R Phillips, Topical Diltiazem and Bethanechol decrease anal sphincter pressure and heal anal fissures without side effects. *Diseases of the Colon and Rectum*. 1999; 43 (10): 1359-62.
- [11] UK Srivastava, BK Jain, Praveen Kumar, Yusuf Saifee. A comparison of the effects of Diltiazem and Glyceryl trinitrate ointment in the treatment of chronic anal fissure: a randomized clinical trial. *Surgery Today*. 2007; 37(6): 482-85.
- [12] GF Nash, K Kapoor, K Saeb-Parsy, T Kunanadam, PM Dawson, The long term results of Diltiazem treatment for anal fissure. *International Journal of Clinical Practice*. 2006; 60(11): 1411-13.
- [13] R Dasgupta, I Franklin, J Pitt, PM Dawson, Successful treatment of chronic anal fissure with Diltiazem gel. *Colorectal Disease*. 4:20-22.