



Radiodiagnosis

A TYPICAL CASE OF COMPLETE SECOND BRANCHIAL CLEFT FISTULA

Dr. Ashutosh Patel	Third Year Resident Doctor Department Of Radiodiagnosis, C.u. Shah Medical College & Hospital, Surendranagar, Gujarat, India.
Dr. Harshad Shah*	Professor & Guide Department Of Radiodiagnosis, C.u. Shah Medical College & Hospital, Surendranagar, Gujarat, India. *Corresponding Author
Dr. Nirmala Chudasama	Professor & Head Of Department, Department Of Radiodiagnosis, C.u. Shah Medical College & Hospital, Surendranagar, Gujarat, India.

ABSTRACT **INTRODUCTION** – Second **branchial cleft fistulae** are congenital anomalies of embryonic development of branchial apparatus with the external cutaneous ostium in the lateral neck connecting to the tonsillar fossa. Second branchial cleft fistulae are rare and comprise only 2% of all branchial anomalies. They commonly present in the first and second decade of life. There is a slight with male predilection (M: F 3: 2).
AIMS & OBJECTIVES - Second branchial cleft fistula is very rare entity of Developmental anomalies arising from the branchial apparatus & our aim is to diagnose it with the help of conventional & computerized tomographic techniques.
MATERIALS & METHODS – A rare case study of **complete Second branchial cleft fistula** with use of conventional (Fistulography) x ray & computed tomography of involved part.
RESULTS – By using above methods & materials we diagnosed complete path & opening of **Complete second branchial cleft fistula**.
CONCLUSIONS – Conventional radiology (fistulography) using x-rays & computed tomography of the lesion is useful in diagnosis of complete second branchial cleft fistula.

KEYWORDS : Second Branchial Cleft Fistula, Fistulography.

INTRODUCTION -

Second branchial cleft fistulae are congenital anomalies of embryonic development of branchial apparatus with the external cutaneous ostium in the lateral neck connecting to the tonsillar fossa. Second branchial cleft fistulae are rare and comprise only 2% of all branchial anomalies. They commonly present in the first and second decade of life. There is a slight with male predilection (M: F 3: 2). Developmental anomalies arising from the branchial apparatus includes cysts, external sinuses, internal sinuses, and complete fistulas.

CASE REPORT:

A 15-year-old male presented with complains of intermittent discharge from small external cutaneous ostium in the lateral neck situated just anterior to sternocleidomastoid. No history of trauma or surgery and unremarkable family history. Then the patient has undergone fistulography & contrast injected computed tomography (contrast injected through external opening situated just anterior to sternocleidomastoid).

Fistulography (opacifying the fistula with contrast media) delineates a smooth tract extending from the external cutaneous opening at the lateral neck passing supero-medially between the ECA and ICA to the tonsillar fossa.

CT with ct reformatted images reveals a smoothly marginated tract of variable width following the anatomic path described above.

DISCUSSION:

Developmental anomalies arising from the branchial apparatus includes cysts, external sinuses, internal sinuses, and complete fistulas. Cysts may exist independently or anywhere along the course of a sinus or fistula. In this case, it was clear that the patient had a complete fistula because he was able to taste the contrast material introduced during the fistulogram.

Course of second branchial cleft fistula: In the normal course a persistent fistula of the second branchial cleft and pouch passes from the external opening in the mid or lower third of neck in the line of the anterior border of the sternocleidomastoid muscle, deep to platysma along the carotid sheath. The tract then passes medially deep between the internal and external carotid arteries, as in our case, after crossing over the glossopharyngeal and hypoglossal nerves. Finally, it opens internally in the tonsillar fossa.

These fistulae typically present with intermittent or continuous mucous discharges from the cutaneous opening at the lateral neck, and may suffer from recurrent attacks of inflammation, particularly after a preceding upper respiratory tract infection. Uncommonly the lining of the fistula can undergo malignant degeneration into squamous cell carcinoma.

Differentials point of view: Branchial cleft fistula should be differentiated from thyroglossal fistula which arise from epithelial trapped during the embryonic descent of the thyroid gland as is located in the midline between base of the tongue and the thyroid. The external orifice of the thyroglossal fistula moves on tongue protrusion

Diagnosis is best demonstrated utilizing CT fistulography & 3D reformatted images.

TREATMENT:

If the fistula is asymptomatic, surgery is usually not indicated. If it is symptomatic than surgery is done to avoid the recurrent infections. Sclerosing solutions have been used for obliteration of fistulas to avoid scar formation. However, these solutions are rarely used now because of the danger of marked inflammatory reaction and necrosis with perforation into the pharynx. Total surgical excision using a hockey stick or stapler technique with two separate transverse incisions is recommended for a definite cure. Surgery is often facilitated by the preoperative injection of the tract with methylene blue or paraffin, or by the insertion of a thin catheter.

CONCLUSIONS –

Conventional radiology (fistulography) using x-rays & computed tomography of the lesion is useful in diagnosis of complete second branchial cleft fistula.

FIGURE AND LEGENDS:

Fig 1: Fistulogram (ap/lateral view) (figure: 1.1 & 1.2):

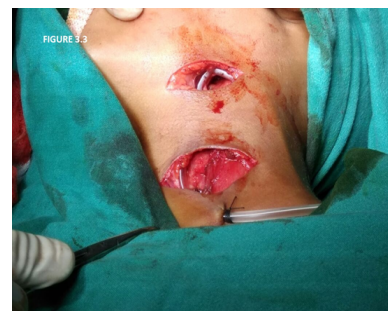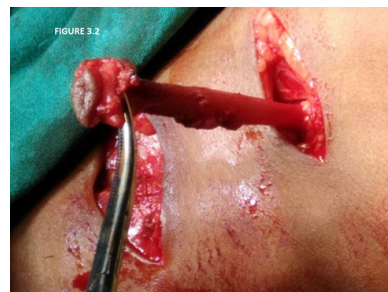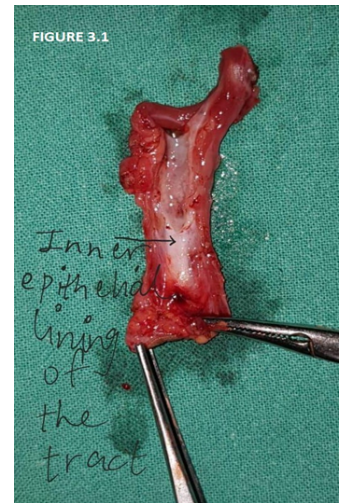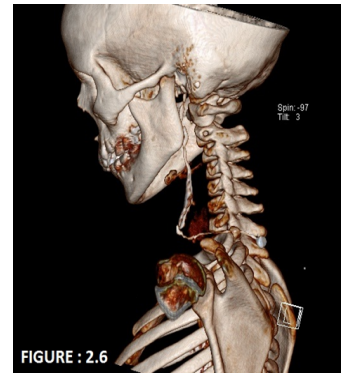
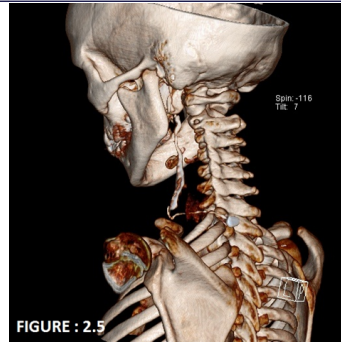
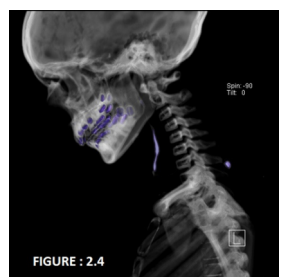
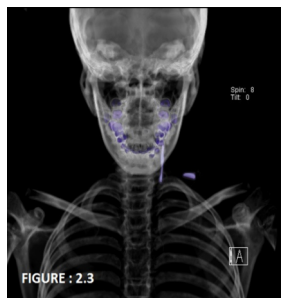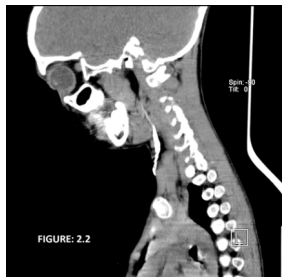
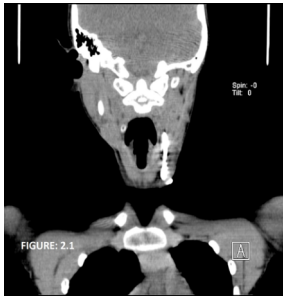
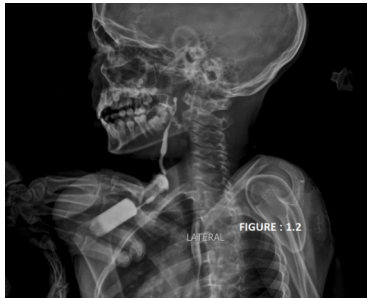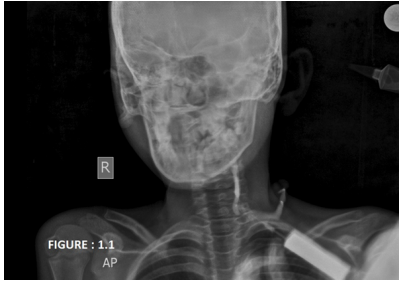Water soluble iodinated contrast media was injected into the external orifice via a plastic canula which delineates smooth tract measuring 7.5 cm extending cranially passing supero-medially upto the left tonsillar fossa in mouth.

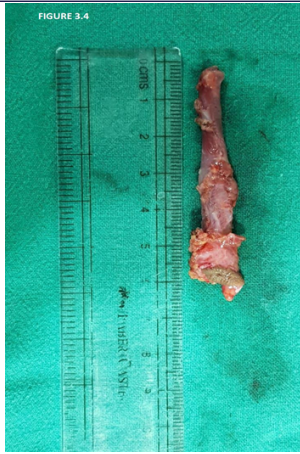Fig 2: Contrast coronal (figure: 2.1), sagittal (figure: 2.2) & reformatted 3D CT (figure: 2.3 to 2.6) image:

Sagittal, Coronal & reformatted 3D CT images show a linear smooth tract with the external orifice at the left lateral aspect of the neck just anterior to the sternocleido-mastoid muscle which is extending to the

left tonsillar fossa.

Fig 3: Post-operative image with epithelial lining of track (figure: 3.1), Surgical image (figure: 3.2), Opening of excised track (figure: 3.3) & post-operative image of track with length of track (figure: 3.4).





REFERENCES

1. Neal HB, Pemberton J. Lateral cervical (branchial) cysts and fistulas. *Surgery* 1945; 1 8: 267-286
2. Gold BM. Second branchial cleft cyst and fistula. *AJR Am J Roentgenol.* 1980; 134 (5): 1067-9. Doi:10.2214/ajr.134.5.1067 – pubmed citation
3. Fitz-Hugh GS, Camp RJ. Branchial cysts and fistulas: report of an unusual case. *South Med J* 1963; 56:232-240 1069
4. Proctor B. Lateral vestigial cysts and fistulas of the neck. *Laryngoscope* 1955; 65: 355-401
5. McPhail N, Mustard RA. Branchial cleft anomalies: a review of 87 cases treated at Toronto General Hospital. *Can Med Assoc J* 1966; 94:174-179
6. Albers GD. Branchial anomalies. *JAMA* 1 963; 1 83: 399-409
7. Agbezudor P. A rare muco-cutaneous branchial fistulogram using the McCallum technique. *Radiography* 1976; 42:221-224
8. Maran AGD, Buchanan DR. Branchial cysts, sinuses and fistulae. *Clin Otolaryngol* 1978; 3: 77-92
9. Deane SA, Telander AL. Surgery for thyroglossal duct and branchial cleft anomalies. *Am J Surg* 1 978; 1 36: 348- 353.