



## HEEL PAIN DUE TO SOLITARY CALCANEAL METASTASIS: RARE PRESENTATION OF LUNG CARCINOMA, A CASE REPORT.

<b>Saurabh Singh</b>	Professor , Department of Orthopedics, Institute of Medical Sciences , Banaras Hindu University, Varanasi , Uttar Pradesh , India – 221005
<b>Dr. Dinesh Iyer*</b>	Junior Resident , Department of Orthopedics, Institute of Medical Sciences , Banaras Hindu University, Varanasi , Uttar Pradesh , India – 221005 *Corresponding Author
<b>Dr. Alok Rai</b>	Senior Resident , Department of Orthopedics, Institute of Medical Sciences , Banaras Hindu University, Varanasi , Uttar Pradesh , India – 221005
<b>Dr. Rishabh Surana</b>	Junior Resident , Department of Orthopedics, Institute of Medical Sciences , Banaras Hindu University, Varanasi , Uttar Pradesh , India – 221005
<b>Dr. Divyansh Sharma</b>	Junior Resident , Department of Orthopedics, Institute of Medical Sciences , Banaras Hindu University, Varanasi , Uttar Pradesh , India – 221005
<b>Dr. Siddalingeshwara G I</b>	M.S. Resident , Department of Orthopedics, Institute of Medical Sciences , Banaras Hindu University, Varanasi , Uttar Pradesh , India – 221005

**ABSTRACT** Common presenting features of lung carcinoma are cough ,dyspnoea and haemoptysis. Features of local and distant metastasis are common but are not usually presenting feature. Metastasis to the skeletal system is common in lung carcinoma but metastasis to bones of hand and foot are rare. Non traumatic plantar heel pain is a common complain in out patient department which is usually not investigated radiologically leading to late diagnosis of calcaneal metastasis. We are presenting a rare case of lung carcinoma which presented with heel pain , as a first feature, due to calcaneal metastasis. This case has no common signs and symptoms of lung carcinoma till this time.

**KEYWORDS :** Lung carcinoma, metastasis, calcaneum.

### INTRODUCTION:

Metastasis to bone is common from lung, breast and prostate.<sup>1</sup>Metastatic disease of the skeleton occurs in at least 20% to 30% of patients with malignancy.<sup>2</sup> Usually one third patient of lung carcinoma develop skeletal metastasis.<sup>3,4,5</sup> Among skeleton system bones of axial skeleton are more commonly involved.<sup>6</sup>Metastasis to foot and hand are very rare.<sup>7,8</sup>Metastasis to calcaneum is even more rare, less than 0.1%of total bony metastasis.<sup>9</sup>We are presenting a case which came to us for a long standing heel pain , which was later diagnosed to be metastasis from lung carcinoma.

Case report: A 55 year female came to us with a heel pain from last six months for which she was taking medications from a hospital but pain was not getting relieved completely. She did not had any other complains at the time of presentation. She used to have pain more in morning time. Initially symptomatic treatment was given to her but it did not relieve her symptoms completely. Then she was investigated for arthropathy but it also did not help her. Later on radiological investigation was done and a lytic lesion was found in calcaneum.MRI of calcaneum showed lesion which was suspected to be malignant. Skeletal survey was done no lesion in any other bone was found. CT scan of chest showed a lesion in left lower lobe of lung. Biopsy showed metastatic lesion from carcinoma lung. So in this case presenting feature of lung carcinoma was heel pain due to metastasis in calcaneum. Patient was treated with chemotherapy , followed by curettage and bone grafting and local radiation.

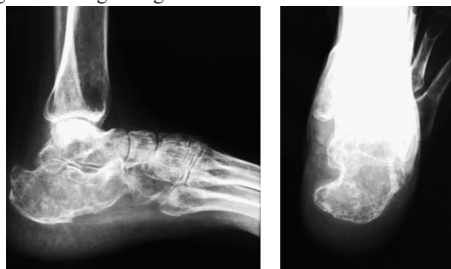

Figure 1(a)

Figure 1 (b)

Figure 1 (a) and (b) : Plain radiograph Lateral view and Harris view showing multiple lytic lesions over the left calcaneum .

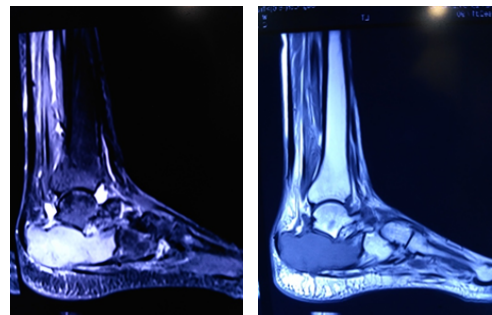


Figure 2(a)

Figure 2 (b)

Figure 2(a) and 2(b): T1-MRI and T2-MRI: Sagittal of the ankle. There is marrow-replacement with preservation of the cortex involving the calcaneus .

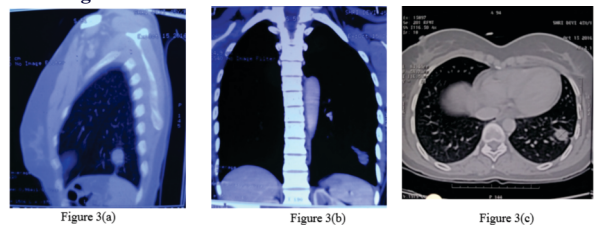


Figure 3(a)

Figure 3(b)

Figure 3(c)

Figure 3(a),(b)and(c) : Saggital ,Coronal and Axial section of CT thorax showing ill-defined mass in the left lower lobe of lung.

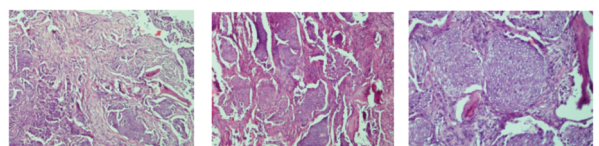


Figure 4(a)

Figure 4(b)

Figure 4(c)

Figure 4 (a),(b) and (c): Histopathology of calcaneus at 10x,10x and 20x showing malignant cells disrupting bony architecture.

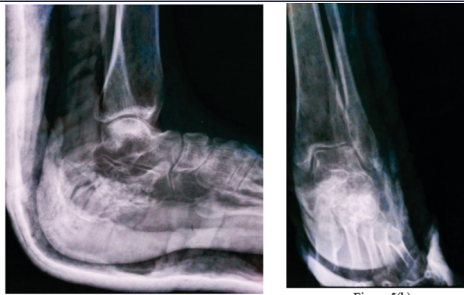


Figure 5(a)

Figure 5(b)

**Figure 5(a) and (b) : Plain radiology postoperative after curettage and bone grafting**

**DISCUSSION:**

Lung carcinoma is common malignancy with increasing incidence. Bone metastasis is very common in lung carcinoma, upto 30% cases.<sup>9</sup> Lung ,brain and liver are other common site for metastasis from lung primary.<sup>9</sup>Metastasis to foot occur in 0.03% cases of total cancer patients.<sup>10,11,12</sup>

Plantar heel pain is a common problem and clinical diagnosis related to it are plantar fasciitis, calcaneal spur , retrocalcaneal bursitis which usually do not need any investigation .Treating symptomatically leads to delay in radiological investigation which when done , showed lytic lesion .On review of literature very few cases of isolated calcaneal metastasis were found.

**CONCLUSION:**

This is a very rare case where presenting feature for lung carcinoma was heel pain due to solitary metastasis to calcaneum.

**Conflict of interest:** None

**REFERENCES:**

1. Woodhouse EC, Chuaqui RF, Liotta LA. General mechanisms of metastasis. *Cancer* 1997;80(Suppl):1529-37.
2. Johnston, AD: Pathology of metastatic tumors in bone. *Clin Orthop Relat Res.* 73:8 – 32, 1970. <http://dx.doi.org/10.1097/00003086-197011000-00003>
3. Coleman RE. Skeletal complications of malignancy. *Cancer* 1997; 80(Suppl):1588-94.
4. Kosteva J, Langer C. The changing landscape of the medical management of skeletal metastases in nonsmall cell lung cancer. *Curr Opin Oncol* 2008;20:155-61
5. Tsuya A, Kurata T, Tamura K, Fukuoka M. Skeletal metastases in non-small cell lung cancer: A retrospective study. *Lung Cancer* 2007;57:229-32.
6. Rosenthal DL. Radiologic diagnosis of bone metastases. *Cancer* 1997;80: 1595-607.
7. Healey, JH; Turnbull, AD; Miedema, B; Lane, JM: Acrometastases. A study of twenty-nine patients with osseous involvement of the hands and feet. *J Bone Joint Surg Am.* 68:743 – 746, 1986.
8. Libson, E; Bloom, RA; Husband, JE; Stoker, DJ: Metastatic tumours of bones of the hand and foot. A comparative review and report of 43 additional cases. *Skeletal Radiol.* 16:387 – 392, 1987
9. Tamura T, Kurishima K, Nakazawa K, Kagohashi K, Ishikawa H, Satoh H, Hizawa N. Specific organ metastases and survival in metastatic non-small-cell lung cancer. *Molecular and Clinical Oncology.* 2015;3:217–221.
10. Hattrup, SJ; Amadio, PC; Sim, FH; Lombardi, RM: Metastatic tumors of the foot and ankle. *Foot Ankle.* 8:243 – 247, 1988.
11. Wu, KK; Guise, ER: Metastatic tumors of the foot. *South Med J.* 71:807 – 808, 812, 1978.
12. Zindrick, MR; Young, MP; Daley, RJ; Light, TR: Metastatic tumors of the foot: case report and literature review. *Clin Orthop Relat Res.* 170:219 – 225, 1982