



ROLE OF MULTIPARAMETRIC MRI IN EVALUATION OF PROSTATIC CARCINOMA AND ITS CORRELATION WITH HISTOPATHOLOGY

Dr. Aishwarya Singh	Department of Radiology, IMS &SUM Hospital, Bhubaneswar, Siksha O' Anusandhan University.
Dr. Subhashree Das*	Department of Radiology, IMS &SUM Hospital, Bhubaneswar, Siksha O' Anusandhan University. *Corresponding Author
Dr. Satya Mohapatra	Department of Radiology, IMS &SUM Hospital, Bhubaneswar, Siksha O' Anusandhan University.
Dr. Niranjana Sahu	Department of Radiology, IMS &SUM Hospital, Bhubaneswar, Siksha O' Anusandhan University.

ABSTRACT Prostate cancer is most common malignancy in males in India. DRE and PSA are commonly used for clinical and biochemical evaluation of suspected patients. TRUS is the primary imaging modality for both benign and malignant disease. In view of limitations of PSA, DRE and TRUS, MRI is the evolving modality. PIRADS refers to structured reporting scheme for evaluating prostate cancer. It is based on T2W and Diffusion weighted sequences along with Dynamic contrast enhanced scan which offers additional value for localisation of lesion. This study was done at a tertiary care centre in eastern India with total study population of 50 patients. Patients with DRE suspicious, negative TRUS guided biopsy and elevated PSA were included in the study. Most of the patients with PIRADS 4 and 5 came out to be prostatic adenocarcinoma showing high Gleason score in TRUS guided biopsy.

KEYWORDS : PIRADS, Prostatic carcinoma, TRUS Biopsy, PSA, MpmMRI

INTRODUCTION :

Prostate carcinoma is the most common cause of malignancy in men. It is second most common cause of cancer-related deaths in men. Adenocarcinoma is the most common histological pattern. In India prostate cancer has an incidence rate of 3.9 per 100,000 men and is responsible for 9% of all cancer-related mortality [1, 2].

At present, "86% of newly diagnosed prostate cancers in India are localized within the gland and patients have a 5-year relative survival rate of 100%". The 5-year relative survival rate for all stages of prostate cancer is 98%, which denotes that prostate tumours have a slow growth rate and hence have prolonged survival, even in patients with metastases at diagnosis. Although mortality rates are much lower, still prostate cancer is one of the second most common cause.

The currently used screening tests are Digital rectal examination, serum PSA level, PCA-3 and free PSA when PSA is raised. Biopsy is considered as the gold standard. Serum PSA elevation may indicate the presence of prostatic disease (including prostate cancer, benign prostatic hypertrophy and prostatitis). Elevation of PSA above 4 ng/mL carries a 22% probability of prostate cancer, and a further increase above 10ng/mL raises the cancer risk to 63% [3, 4]. As PSA values rise with age, there is an agreed cut-off level for different age groups. Still this is not universally accepted, as men may be prostate cancer positive despite low levels of serum PSA. The use of an age-specific normal range for PSA values increases the positive predictive value of PSA testing. Due to the limitations of PSA there is a need for Biopsy in suspicious cases for early detection of malignancy. TRUS Biopsy is most common procedure used for prostate biopsy. In this procedure the gland is mainly divided into six or more zones of equal volume and one or more core is randomly collected from each zone known as "systematic random sextant" or "blind biopsy". As it is a blind biopsy, there is always a chance of false negatives in biopsy sample.

Various imaging modalities are in use for detection, risk stratification, recurrence and post therapy assessment such as TRUS, Mp USG, Mp MRI. Among these MRI not only helps in tumor detection, localisation, staging, extracapsular extension, restaging and follow up but also provides information about tumour aggressiveness which is often correlated well with Gleason score. Mp MRI uses DWI, ADC, DCE, MRS as adjuncts to MRI in further evaluation. Where DWI assesses the tumor volume, DWI/ADC often shows restricted diffusion in prostate cancer, Dynamic contrast enhancement (DCE) is more specific than T2 signal for equivocal or borderline cancers, MR spectroscopy shows increased choline to citrate or choline plus creatine to citrate ratios in prostate cancer.

The aim of this study is to correlate Mp MRI findings to histopathology findings and to find out if Mp MRI can serve in the detection of prostate cancer that requires treatment while avoiding biopsy, anticipation or staging before biopsy.

MATERIALS AND METHODS:

This is a cross sectional observational study in the Department of Radiodiagnosis, IMS and SUM Hospital from 2017-2019 with a sample size of 50 patients with clinically suspected prostate cancer attending the Department of Urology, IMS and SUM Hospital.

Inclusion Criteria

- Patients with elevated PSA (>4 ng/mL) and DRE suspicious of prostate cancer.
- Patients with normal PSA but DRE suspicious of prostate cancer.
- Previously negative TRUS biopsy patients with elevated PSA.

Exclusion Criteria

- Known patients of prostate cancer

Study Technique:

An informed consent was taken from patients with suspected prostate cancer based on elevated PSA and suspicious DRE and were made to undergo multiparametric MRI in 1.5T MR scanner. Suspicious lesions were evaluated using T2WI, DWI and DCE sequences and a final PIRADS score was attributed to the lesion. Thereafter, TRUS guided biopsy were taken for histopathological diagnosis and Gleasons scoring. Targeted biopsies were taken from suspicious sites when applicable.

PI-RADS SCORING TO DIAGNOSE CA PROSTATE (PIRADS)

T2WI for the peripheral zone (PZ)	
1	Uniform high signal intensity (SI)
2	Linear, wedge shaped, or geographic areas of lower SI, usually not well demarcated
3	Intermediate appearances not in categories 1/2 or 4/5
4	Discrete, homogeneous low signal focus/mass confined to the prostate
5	Discrete, homogeneous low signal intensity focus with extracapsular extension/invasive behaviour or mass effect on the capsule (bulging), or broad (>1.5 cm) contact with the surface
T2WI for the transition zone (TZ)	
1	Heterogeneous TZ adenoma with well-defined margins: "organised chaos"
2	Areas of more homogeneous low SI, however well marginated,

originating from the TZ/BPH
3 Intermediate appearances not in categories 1/2 or 4/5
4 Areas of more homogeneous low SI, ill defined: "erased charcoal sign"
5 Same as 4, but involving the anterior fibromuscular stroma or the anterior horn of the PZ, usually lenticular or water-drop shaped.

Diffusion Weighted Imaging (DWI)
1 No reduction in ADC compared with normal glandular tissue. No increase in SI on any high b-value image ($\geq b800$)
2 Diffuse, hyper SI on $\geq b800$ image with low ADC; no focal features, however, linear, triangular or geographical features are allowed
3 Intermediate appearances not in categories 1/2 or 4/5
4 Focal area(s) of reduced ADC but iso-intense SI on high b-value images ($\geq b800$)
5 Focal area/mass of hyper SI on the high b-value images ($\geq b800$) with reduced ADC

Dynamic contrast enhanced (DCE)-MRI
1 Type 1 enhancement curve
2 Type 2 enhancement curve
3 Type 3 enhancement curve
+1 For focal enhancing lesion with curve type 2-3
+1 For asymmetric lesion or lesion at an unusual place with curve type 2-3

Final PI-RADS Score

Every suspicious nodule is given a final PI-RADS score based on T2 weighted image, DWI and contrast enhancement patterns as per **PI-RADS** scoring system as suggested by ESUR prostate MR guidelines 2012, EurRadiol (2012) 22:746-757

PI-RADS classification	Definition	Total Score With T2,DWI,DCE
1	Most Probably Benign	3,4
2	Probably Benign	5,6
3	Indeterminate	7-9
4	Probably Malignant	10-12
5	Highly Suspicious of Malignancy	13-15

TRUS Guided Biopsy

An 18-gauge Bard biopsy needle loaded in a spring-action automatic biopsy device was used to procure multiple 1.9cm prostate biopsy specimens. A total of 6cores were taken from the base, midzone and apex. Any suspicious nodule noted in MRI was localised to a sector on TRUS and targeted biopsies taken. Biopsy samples were labelled according to their location and were sent for histopathology.

RESULTS:

Median age of all patients in this study was 65 years. Age varied between 48 to 90 years.

PI-RADS Classification	Total score with T2, DWI, DCE	Results
1	3,4	32 Benign
2	5,6	
3	7-9	
4	10-12	11 Malignant
5	13-15	7

Among 50 patients, 7 patients were diagnosed as PIRADS 5, 11 patients were categorised as PIRADS 4. 32 patients were diagnosed as having benign lesions. Among 50 patients, 32 were benign (PIRADS 0 to 3) and 18 were malignant (PIRADS 4 and 5).

	PI- RADS	Total	Gleason score	
Benign	0-3	32	<7	28
Malignant	4,5	18	≥ 7	4
		50		33

Among the 50 patients after TRUS guided Bx, 17 patients were diagnosed as malignant (adenocarcinoma) (Gleason score ≥ 7). 33 patients had benign disease (Gleason score < 7). We over-diagnosed 5 patients as malignant and under-diagnosed 4 patients as benign compared to Gleason score.

PIRADS VS GLEASON:

(PIRADS)	OUTCOME (GLEASON SCORE)		TOTAL
	≥ 7	< 7	
4,5	13	5	18
0-3	4	28	32

	17	33	
--	----	----	--

SENSITIVITY =76.5%
SPECIFICITY =84.8%
POSITIVE PREDICTIVE VALUE =72.22%
NEGATIVE PREDICTIVE VALUE =87.5%

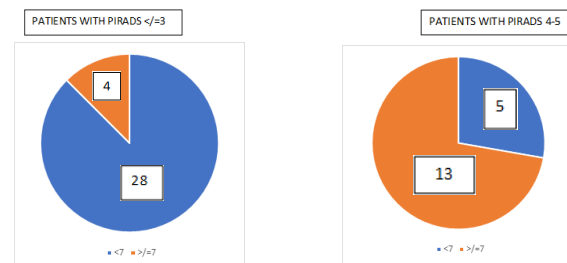


Chart 5 Relation Of Outcome Of Gleason Score With Outcome Of Test Result PI

DISCUSSION:

Out of 50 patients, 32 patients came out to be benign on histopathology and 18 patients proved to be malignant (adenocarcinoma). 5patients were over-diagnosed as malignant by PI- RADS and 4 patients proved to be malignant on histopathology while PI-RADS diagnosed them as Benign.

It was previously believed that prostate MRI has a limited role in few cases for localisation, staging, restaging and follow up. The role of MRI as a diagnostic tool is rather new and currently practised in very few areas around the world like France, Japan, India and UK [5]. Currently, the threshold for requesting a pre-treatment staging MRI is variable, with most clinicians advocating pre-treatment staging only for those with high-risk, localized prostate cancer, although some also advocate men with intermediate risk disease. The rationale for this view is that verification of organ-confined cancer in men with a low risk of locally advanced disease using a test that is both expensive and time consuming is not warranted. This situation has arisen owing to poor quality scans as a result of low-resolution magnetic field strengths combined with biopsy artefact. Evidence is increasing, however, that the threshold for requesting MRI should be lowered. This is related to improved technology, but is also linked to changes in diagnosis and management of prostate cancer, in which improved risk stratification is linked to reductions in treatment burden.

A review from 2006 that assessed the ability of MRI to localize disease within the gland showed that detection of cancer was variable. Whole-mount histology was used as the reference standard; T2W-MRI scans had a sensitivity of between 37-96%, whereas DCE MRI or MRS reduced this range to 57-89% and 50-86%, respectively. Accuracy of cancer detection also varied according to differences in methodology. This variation was due to a number of factors: the criteria used to define significant tumors (many studies excluded foci $< 0.5 \text{ cm}^3$); the method of analysis (studies often divided the gland into 2 regions of interest, to as many as 42); whether endorectal coils or pelvic phased arrays were used (coils improve the signal-to-noise ratio of the prostate); and whether the reference standard was TRUS biopsy or whole-mount histology. The accuracy for MRI was greater for detecting large and high Gleason grade tumors than small and low-grade tumors [6, 7].

In the current study 50 patients with clinically suspected prostate cancer were evaluated by MRI without the use of endorectal coil in a 1.5T system for lesion detection, characterisation, and correlation with TRUS guided prostate biopsies. To improve the quality of the procedure and reporting, a group of experts of the "European Society of Urogenital Radiology"(ESUR) published a guideline for MRI of the prostate. In addition to providing recommendations relating to indications and minimum standards for MR protocols, the guideline described a structured reporting scheme(PI-RADS).It was therefore the aim of this study to use the PI-RADS model for the detection of prostate cancer using representative images for the relevant scores, and to add a scoring table that combined the aggregated multiparametric scores to a total PI-RADS score according to the Likert scale.

We found that majority of patients' in this study belonged to sixth and seventh decade. Also most patients presented with some form of extra-prostatic involvement and all had an intermediate to high Gleason's score (i.e., ≥ 6).

'Turkbey et al' revealed that T2-weighted MR imaging alone had the highest sensitivity for PZ tumors alone and for PZ and TZ tumors combined for both small and larger lesions. Their sensitivity varied from 91% to 94% depending on the site. Sensitivity reduced with central lesions and in the presence of haemorrhage. They also reported that sensitivity for T2-weighted MR imaging was significantly higher than it was for dynamic contrast-enhanced MR imaging or MR spectroscopy, and specificity for T2-weighted MR imaging was lower than the others. This finding was similar to the present study. T2 -WI provides high-resolution morphologic imaging of the gland in the three planes, and axial T1 -WI is used to detect post-biopsy haemorrhage, lymph nodes, and bone metastasis. On T2 -WI, peripheral zone cancer typically shows a uniformly low signal with a nodular shape within the peripheral zone that shows high signal. However, there are numerous false positives because low intense signal in peripheral zone can also be caused by inflammation, haemorrhage, sequelae of radiation and hormonal treatment. Sensitivity of 77–91% and specificity of 27–61% were reported for PCa detection with T2-weighted imaging by Hricak & White et al [8]. "Wang el in his study in 2009 revealed that specificity 54-82% and sensitivity 46-96%"[9]. Detecting peripheral zone PC has been most effective using MR imaging. Detection of PCa in the transition zone is most effective when MR imaging and other functional sequences are used in combination.

Findings supporting the diagnosis of transition zone tumor are: the presence of homogeneous low-SI region in transition zone and in the absence of dominant peripheral zone tumor. Other alternatives are poorly defined or have speculated lesion margins in transition zone, lack of a low - SI rim (associated with benign adenomatous nodules), interruption of the surgical pseudocapsule, urethral or anterior fibromuscular stromal invasion or lenticular shape [10]. Extraprostatic spread especially involvement of seminal vesicles can be well depicted on T2WI alone.

Some studies report a significant correlation between ADC and Gleason, these findings have not been consistent. In the present study, **"PIRADS scoring for DWI correlated well with Gleasons score"**.

There have been several studies at 1.5 Tesla reporting statistical differences in ADC between prostate tissue types, especially between malignant lesions and normal peripheral zone.

Ren et al' demonstrated significant differences in ADC values between normal prostatic tissue in volunteers and prostatic diseases including prostate cysts, BPH and prostate cancer. They suggested the use of this technique in the differential diagnosis of prostatic diseases. In general, ADC values have been found to be significantly lower in malignant compared with non-malignant prostate tissue, leading to an improvement in tumour detection and identification, compared with T2 weighted imaging alone, with sensitivity and specificity values of 50% and 79.6% respectively for T2w alone, versus 73.2% and 80.8% for combined DWI and T2w imaging [11]. With advances in MR gradient coils, single shot echo planar imaging (EPI) has emerged as the technique of choice for diffusion measurements in the prostate providing better resolution ADC images [12]. A study by "Issa et al using EPI DW imaging also showed statistical differences in ADC values between normal PZ, BPH and cancerous prostatic regions" [13]. At 1.5 Tesla, the signal-to-noise ratio (SNR) is intrinsically low, and DW image quality is relatively poor. With the advent of 3.0 Tesla clinical scanners and improved receiver coils combined with parallel imaging, highSNR with low distortion DW images can be obtained within reasonable scan times. Consequently, the production of DW images of the prostate for clinical purposes is even more viable. Recent studies showed substantial promise using 3.0 Tesla diffusion imaging to differentiate between benign and malignant prostate tissue [14, 15, and 16]. Restriction in DWI and reduced ADC values were found to with tumour significantly correlate regions compared to normal PZ [14].

The criteria for a suspected malignancy on the ADC map was the presence of a hypointense focus relative to adjacent normal prostate tissue with or without comparison to T2 weighted images. Previous studies in which diffusion images were divided into regions and known as malignant or benign according to ADC values and compared with histology from biopsy samples for statistical analysis often showed discrepancies between the two [16, 17]. There are a few fallacies in the above method disadvantages leading to erroneous results: 1) the

number of TRUS biopsies varies from patient to patient; 2) biopsy findings do not provide tumour mapping and accurate localisation in relation to the whole prostate cannot be achieved; and 3) registering the TRUS and ADC images is difficult and the two procedures are often done by different clinicians. Recent reports have achieved a better comparison by using the whole mounted pathology specimen following radical prostatectomy. Mapping of tumour regions could then be drawn and direct comparison with ADC map performed [15]. Most malignant lesions (81%) showed ADC values lower than our arbitrary cut-off value of $1.62 \times 10^{-3} \text{ mm}^2/\text{s}$. However, there was considerable overlap between ADC values of tumour and normal PZ; this indicates that the use of ADC value alone for tissue discrimination could result in misdiagnosis. It is recommended that interpretation of ADC values be carried out in comparison with ADC values for benign PZ in the same gland.

A growing number of MRI studies have shown that the detection and characterization of prostate cancer can be significantly improved by performing the imaging examination on higher magnetic field strength MR scanners (3 T) and using either DWI or MRSI with DCE-MRI [18, 19, 20, 21]. In a multiparametric MRI examination, the high sensitivity of DCE-MRI may be used to select lesions for biopsy. Thus, DCE-MRI is interpreted both independently and together with other sequences especially for ambiguous lesions involving the central gland.

A study of DCE-MRI and combined DCE-MRI-MRSI in 150 patients with a negative prior transrectal ultrasound-guided prostate biopsy showed that DCE-MRI had sensitivity, specificity, and positive and negative predictive values of 76.5%, 89.5%, 84.5%, and 83.7%, respectively, and these numbers improved with the combined use of DCE-MRI and MRSI [22]. Others have shown a high correlation of DCE-MRI findings in prostate cancer with whole-mount histopathology [23, 24, 25]. Thus, DCE-MRI contributes valuable information to prostate MRI.

In the last decade, with greater use of 3 T systems and improved acquisition protocols the multiparametric approach has been shown to improve the accuracy of prostate MRI. Thus, DCE-MRI is significantly more effective and should preferably be viewed in the context of other MRI parameters. For instance, one study showed that combining T2-weighted MRI with DWI and DCE-MRI led to sensitivity of 83%, whereas the sensitivity of DCE-MRI alone was only 43% [19]. Recently, "Turkbey et al. reported that a four-sequence multiparametric approach (T2-weighted, DWI, DCE-MRI, and MRSI) had sensitivity of 86% and specificity of nearly 100% in a prospective trial of 45 patients" [26]. In the present study the sensitivity, specificity, PPV and NPV was 95.83%, 60%, 85.19% and 85.71%. When combined with T2WI the values the specificity, PPV and NPV improved to 80%, 92.31% and 100% but the sensitivity reduced mildly to 91.67%. Highest accuracy was obtained when all three parameters were used for evaluation. Multiparametric MRI has been more successful in the peripheral zone than the central gland [26]. A recent study reported that combined use of ADC maps and K^{trans} values extracted from DCE-MRI improved tumor detection in the central gland [27]. As experience grows and technology improves, the multiparametric MRI approach has also improved and very acceptable detection rates can now be obtained from both the peripheral zone and central gland.

CONCLUSION

Advocating the widespread use of MRI before biopsy in a population of men with risk parameters for harbouring prostate cancer has a number of advantages, which might ultimately benefit them. Increasing the detection of prostate cancer that requires treatment while avoiding biopsy—and hence unnecessary treatment—in those with insignificant or no cancer are compelling arguments for this approach. Conferring better staging accuracy and determining disease burden might also lead to greater benefit for those who undergo treatment.

The sensitivity, the positive predictive value, and the lesion location match rate of MRI performed before prostate biopsy were accurate enough to consider MRI as a first line investigation for prostate cancer detection. In comparison with other previous reports, our results suggest that the sensitivity and specificity of prostate cancer detection by multiparametric MRI is on the rise. We thus conclude that MRI as a screening tool to diagnose prostate cancer has become more useful. In addition, MRI before prostate biopsy can provide more information by

which to identify prostate cancer during prostate biopsy, which is anticipated to be of help in reducing the false-negative rate.

REFERENCES:

1. Trabulsi EJ, Sackett D, Gomella LG, Halpern EJ. Enhanced transrectal ultrasound modalities in the diagnosis of prostate cancer. *Urology*. 2010;76:1025–33. [PubMed]
2. Jemal A, Center MM, DeSantis C, Ward EM. Global patterns of cancer incidence and mortality rates and trends. *Cancer Epidemiol Biomarkers Prev*. 2010;19:1893–907. [PubMed]
3. Carter HB, Piantadosi S, Isaacs JT (1990) Clinical evidence for and implications of the multistep development of prostate cancer. *JUrol* 143:742–746
4. Parkin DM, Bray FI, Devesa SS (2001) Cancer burden in the year 2000. The global picture. *Eur J Cancer* 37(Suppl 8):S4–S66
5. Ahmed, H. U. *et al.* Is it time to consider a role of MRI before biopsy *Nat. Rev. Clin. Oncol.* 6, 197–206 (2009); doi:10.1038/nrclinonc.2009.18
6. Ikonen, *s. et al.* Magnetic resonance imaging of clinically localized prostatic cancer. *J. Urol.* 159, 915–919 (1998).
7. Zakian, K. L. *et al.* Correlation of proton Mr spectroscopic imaging with gleason score based on step-section pathologic analysis after radical prostatectomy. *Radiology* 234, 804–814 (2005).
8. Hricak H, Choyk PL, Eberhardt S, Leibel SA, Scardino PT. Imaging prostate cancer: a multidisciplinary perspective. *Radiology* 2007;243:28–53.
9. Wang L. Incremental value of magnetic resonance imaging in the advanced management of prostate cancer. *World J Radiol* 2009;3:13–14.
10. Ingrid Mocikova, Jozef Babelab, Vladimir Balazb Prostate cancer – the role of magnetic resonance imaging *Biomed Pap Med Fac Univ Palacky Olomouc Czech Repub.* 2012 Jun; 156(2):103–107.
11. Morgan VA, Kyriazi S, Ashley SE, DeSouza NM. Evaluation of the potential of diffusion-weighted imaging in prostate cancer detection. *Acta Radiol.* 2007 Jul; 48:695–703
12. Kozłowski, P. *et al.* Combined diffusion-weighted and dynamic contrast-enhanced MRI for prostate cancer diagnosis—correlation with biopsy and histopathology. *J. Magn. Reson. Imaging* 2, 108–113 (2006).
13. Issa, B. (2002). "In vivo measurement of the apparent diffusion coefficient in normal and malignant prostatic tissues using echo-planar imaging." *J Magn Reson Imaging* 16(2): 196–200.
14. Pickles MD, Gibbs P, Sreenivas M, Turnbull LW. Diffusion-weighted imaging of normal and malignant prostate tissue at 3.0 T. *J Magn Reson Imaging*. 2006 Feb; 23:130–4
15. Kim CK, Park BK, Han JJ, Kang TW, Lee HM. Diffusion-weighted imaging of the prostate at 3 T for differentiation of malignant and benign tissue in transition and peripheral zones: preliminary results. *Journal of computer assisted tomography*. 2007 May-Jun; 31:449–54
16. Miao H, Fukatsu H, Ishigaki T. Prostate cancer detection with 3-T MRI: comparison of diffusion-weighted and T2-weighted imaging. *European journal of radiology*. 2007 Feb; 61:297–302
17. Kumar V, Jagannathan NR, Kumar R, *et al.* Apparent diffusion coefficient of the prostate in men prior to biopsy: determination of a cut-off value to predict malignancy of the peripheral zone. *NMR in biomedicine*. 2007 Aug; 20:505–11
18. Beyersdorff D, Taupitz M, Winkelmann B, Fischer T, Lenk S, Loening SA, Hamm B: Patients with a history of elevated prostate-specific antigen levels and negative transrectal US-guided quadrant or sextant biopsy results: value of MR imaging. *Radiology* 2002; 224: 701–706.
19. Tamada, T., Sone, T., Jo, Y., Toshimitsu, S., Yamashita, T., Yamamoto, A., Tanimoto, D. and Ito, K. (2008). "Apparent diffusion coefficient values in peripheral and transition zones of the prostate: comparison between normal and malignant prostatic tissues and correlation with histologic grade." *J Magn Reson Imaging* 28(3): 720–6.
20. Sciarra A, Panebianco V, Cicciariello M, *et al.* Value of magnetic resonance spectroscopy imaging and dynamic contrast-enhanced imaging for detecting prostate cancer foci in men with prior negative biopsy. *Clin Cancer Res* 2010; 16:1875–1883 [CrossRef] [Medline]
21. Scherr MK, Seitz M, Muller-Lisse UG, Ingrisch M, Reiser MF, Muller-Lisse UL. MR-perfusion (MRP) and diffusion-weighted imaging (DWI) in prostate cancer: quantitative and model-based gadobenatadimeglumine MRP parameters in detection of prostate cancer. *Eur J Radiol* 2010; 76:359–366 [CrossRef] [Medline]
22. Panebianco V, Sciarra A, Cicciariello M, *et al.* Role of magnetic resonance spectroscopic imaging ([(1H)MRSI] and dynamic contrast-enhanced MRI (DCE-MRI) in identifying prostate cancer foci in patients with negative biopsy and high levels of prostate-specific antigen (PSA). *Radiol Med (Torino)* 2010; 115:1314–1329 [CrossRef]
23. Ocak I, Bernardo M, Metzger G, *et al.* Dynamic contrast-enhanced MRI of prostate cancer at 3 T: a study of pharmacokinetic parameters. *AJR* 2007; 189:849; [web]W192–W201 [Abstract] [Medline]
24. Kim JK, Hong SS, Choi YJ, *et al.* Wash-in rate on the basis of dynamic contrast-enhanced MRI: usefulness for prostate cancer detection and localization. *J Magn Reson Imaging* 2005; 22:639–646 [CrossRef] [Medline]
25. Villers A, Puech P, Mouton D, Leroy X, Ballereau C, Lemaître L. Dynamic contrast enhanced, pelvic phased array magnetic resonance imaging of localized prostate cancer for predicting tumor volume: correlation with radical prostatectomy findings. *J Urol* 2006; 1
26. Turkbey B, Pinto P, Mani H, Bernardo M, Pang Y, McKinney Y, Khurana K, Ravizzini G, Albert P, Merino M, Choyke P, Prostate Cancer: Value of Multiparametric MR Imaging at 3 T for Detection—Histopathologic Correlation *Radiology*. 2010 April; 255(1): 89–99 76:2432–2437 [CrossRef] [Medline]
27. Oto A, Kayhan A, Jiang Y, *et al.* Prostate cancer: differentiation of central gland cancer from benign prostatic hyperplasia by using diffusion-weighted and dynamic contrast-enhanced MR imaging. *Radiology* 2010; 257:715–723 [CrossRef] [Medline]