



STUDY OF VARIOUS LIGAMENTOUS AND MENISCAL INJURIES IN ACUTE KNEE INJURY (AKI)

Dr. Rajesh Kishanrao Ambulgekar

Professor and Head, Department of Orthopedics, Dr. S.C. Govt. Medical College, Vishnupuri, Nanded, Maharashtra, India.

Dr. Kundan Sen*

Junior Resident, Department of Orthopedics, Dr. S.C. Govt. Medical College, Vishnupuri, Nanded, Maharashtra, India. *Corresponding Author

ABSTRACT

Background: The knee joint is one of the major weights bearing joints in the lower extremity. An acute injury of the knee joint is the result of a single incident – such as a twist, fall, excessive force or direct blow from a solid object. Patient with acute knee injury may have associated injuries in the form of anterior cruciate ligament injury, posterior cruciate ligament injury, medial and lateral meniscus injury, medial and lateral collateral ligament injury.

Aims And Objectives: 1. To study various Ligamentous and Meniscal injuries in Acute Knee Injury. 2. To assess the epidemiology of various ligamentous injury in Acute Knee Injury.

Materials And Methods: A prospective study was done on 30 consenting patients with acute knee injury with-in 24 hours to 6 days of the initial trauma, closed trauma, mono-trauma cases, adult patients with age >10 years and cases in which MRI is contraindicated. Arthroscopy was done, the pathological structure was identified and further surgery was carried out accordingly.

Results: In the present study most common age group affected was 21-40 years (63.33% cases) and the mean age was 32.36±11.54 years. 70% were males and 30% were female. 03 cases (10.00%) presented with instability, 19 cases (63.33%) with pain and swelling, and 08 cases (26.66%) with pain, swelling and locking. 21 cases (70%) were having anterior cruciate ligament injury, 2 cases (6.67%) had posterior cruciate ligament injury, 22 cases (73.33%) had medial meniscus injury, 6 cases (20%) had lateral meniscus injury, 2 cases (6.67%) with medial collateral ligament injury and 2 cases (6.67%) were having lateral collateral ligament injury. 10 cases (33.33%) were having with anterior cruciate ligament tear, ACL sprain in 6 (26.67%) and avulsion in 3 cases (10%). We had three cases of ACL bony avulsion (10%) and one case of medial tibia plate injury (03.30%). OCD (osteochondral defect) was seen in one case.

Conclusion: In AKI, most commonly males of middle age group are affected. Most common affected ligament is ACL and medial meniscus. PCL and lateral meniscus are less commonly involved. Common associated injuries occur are ACL bony avulsion, medial tibia plate injury and osteochondral defect.

KEYWORDS : Acute Knee Injury, Arthroscopy, anterior cruciate ligament, posterior cruciate ligament injury, medial meniscus injury.

INTRODUCTION:

The knee joint is one of the major weights bearing joints in the lower extremity. Knee joint is made up of many different structures – ligaments, bones, joint cartilage and two menisci (which are also made of cartilage).

An acute injury of the knee joint is the result of a single incident – such as a twist, fall, excessive force or direct blow from a solid object. Patient with acute knee injury may have associated injuries in the form of anterior cruciate ligament injury, posterior cruciate ligament injury, medial and lateral meniscus injury, medial and lateral collateral ligament injury, patient may also have associated bony injury like tibial spine avulsion fracture, medial and lateral tibial condyle fracture, chip avulsion fracture of medial and lateral femoral condyle.¹

Injury to the anterior cruciate ligament is the most common ligamentous injury, ranging up to 200,000 injuries per year.² Combined injury of the anterior cruciate ligament, medial meniscus and the medial collateral ligament is the commonest finding.

Although conservative treatment can potentially be successful in the appropriate population (patients with partial tear of the ligament), patients with goals of returning to high levels of sport activity and with high grade ligamentous injury are typically treated with arthroscopy. In these patients, arthroscopy is carried out as soon as possible after admission to diagnose ligamentous injury and immediate repair or reconstruction procedure could be carried out if necessary.³ The aim of this study is to study various Ligamentous and Meniscal injuries in Acute Knee Injury.

AIMS AND OBJECTIVES OF THE STUDY

1. To study various Ligamentous and Meniscal injuries in Acute Knee Injury.
2. To assess the epidemiology of various ligamentous injury in Acute Knee Injury.

MATERIALS AND METHODS

This study was a prospective study done on 30 consenting patients with

acute knee injury with-in 24 hours to 6 days of the initial trauma, closed trauma, mono-trauma cases, adult patients with age >10 years and cases in which MRI is contraindicated. Patients with open fracture, age < 10 years of age and > 70 years of age, having distal neurovascular deficit, with signs of infection and patient who refused diagnostic Arthroscopy were excluded.

Arthroscopic Examination of the Knee

In arthroscopy of the knee, the pathological structure was identified and further surgery was carried out accordingly (partial/subtotal meniscectomy for meniscal tears, ACL reconstructions for ACL tears)

RESULTS AND OBSERVATIONS:**Age And Sex Distribution:**

In the present study 5 cases (16.67%), 9 cases (30%), 10 cases (33.33%), 4 cases (13.33%) and 2 cases (6.67%) were in the age groups less than 20 years, 21 years- 30 years, 31 years- 40 years, 41 years- 50 years and more than 50 years respectively. The mean age was 32.36±11.54 years. Most of the patients were males, 21 (70%) and 9 cases (30%) were female.

Table 1: Clinical Presentation:

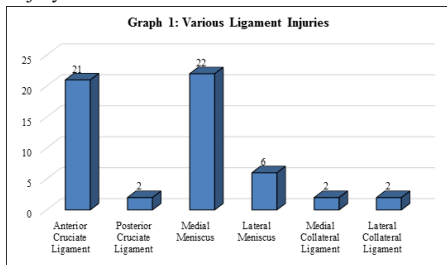
Clinical Presentation	Frequency	Percent
Instability	3	10.00%
Pain, Swelling and Locking	8	26.66%
Pain and Swelling	19	63.33%

In the present study we had 03 cases (10.00%) with instability, 19 cases (63.33%) with pain and swelling, and 08 cases (26.66%) with pain, swelling and locking.

In the present study, 12 cases had injury on the left side accounting for 40% and 18 cases on the right-side accounting of 60%. 26 (86.66%) hemarthrosis and 04 (13.33%) patients presented with effusion.

In the present study 21 cases (70%) were having anterior cruciate ligament injury. 2 cases (6.67%) had posterior cruciate ligament injury, 22 cases (73.33%) had medial meniscus injury, 6 cases (20%) had

lateral meniscus injury, 2 cases (6.67%) with medial collateral ligament injury and 2 cases (6.67 %) were having lateral collateral ligament injury.

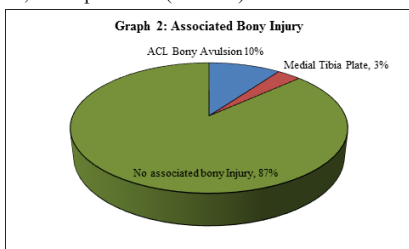


Graph 1: Various Ligament Injuries

Table 2: Anterior Cruciate Ligament Injuries

Anterior Cruciate Ligament	Frequency	Percent
TEAR	10	33.33%
SPRAIN	8	26.67%
AVULSION	3	10.00%
NO	9	30.00%
TOTAL	30	100.00%

In the present study we had 10 cases (33.33%) with anterior cruciate ligament tear, ACL sprain in 6 (26.67%) and avulsion in 3 cases (10%).



Graph 2: Associated Bony Injury

We had three cases of ACL bony avulsion (10%) and one case of medial tibia plate injury (03.30%). OCD (osteochondral defect) was seen in one case.

DISCUSSION

The knee joint is one of the major weights bearing joints in the lower extremity. The aim of arthroscopy in acute knee injuries is to diagnose various ligamentous injuries like anterior cruciate ligament, posterior cruciate ligament, medial and lateral meniscus injury also useful to diagnose avulsion fracture, osteochondral defect and to treat them as early as possible.

Demographic variables:

In the present study most common age group affected was 21-40 years having 63.33% cases and the mean age was 32.36±11.54 years. Our findings are comparable with the study by Brown et al.⁴ and Saravanan et al.⁵ where mean age of the affected patients was 28.8 and 29.6 years respectively. In our study, most of the patients were males (70%) and 30% were female. Similarly, in a study by Jay Kumar et al.⁶ and Vassiliou S Nikolaou et al.⁷ male and females were 77% & 23% and 65% & 35% respectively.

Clinical Presentation:

In the present study 70% were having anterior cruciate ligament (ACL) injury. 6.67% had PCL injury, 73.33% had medial meniscus injury, 20% had lateral meniscus injury, 6.67% with medial collateral ligament injury and 6.67% were having lateral collateral ligament injury. Our findings are in accordance with the study by Bomberg BC and McGinty JB⁸ where 71% patients had an ACL tear, meniscal tears occurred in 47% patients. 16% had medial collateral ligament and/or posteromedial capsular sprain. Similarly, in a prospective study by Ko-Hsiu Lu et al.⁹, ACL tears occurred in 51.1% cases, lateral meniscus injuries occurred in 40.4%.

In the present study, 86.66% hemarthrosis and 13.33% patients presented with effusion. Our findings are comparable with the findings of Johannsen, HV and Fruensgaard et al.¹⁰, hemarthrosis was present in 82% and a bloodless effusion in 10%. J. Gillquist et al.¹¹ in their study

mentioned that most of the cases were having hemarthrosis and serious ligament injury was present in nearly 50% cases.

Associated Injuries:

We had three cases of ACL bony avulsion (10%) and one case of medial tibia plate injury (03.30%). OCD (osteochondral defect) was seen in one case. In a study by Bomberg BC and McGinty JB⁸, 18% had an osteochondral fracture or patellar dislocation associated with an osteochondral fracture.

CONCLUSION:

In AKI, most commonly males of middle age group are affected. Most common affected ligament is ACL and medial meniscus. PCL and lateral meniscus are less commonly involved. Common associated injuries occur are ACL bony avulsion, medial tibia plate injury and osteochondral defect.

REFERENCES

- Gupte C and St. Mart JP. The acute swollen knee: diagnosis and management. J R Soc Med. 2013 Jul; 106(7): 259–268.
- Pache S, Aman ZS, Kennedy M, Nakama GY, Moatshe G, Ziegler C, LaPrade RF. Meniscal root tears: current concepts review. Archives of Bone and Joint Surgery. 2018 Jul;6(4):250.
- Evans S, Shaginaw J, and Bartolozzi A. ACL Reconstruction It's All About Timing. Int J Sports Phys Ther. 2014 Apr; 9(2): 268–273.
- Brown TN, Palmieri Smith RM, Mclean SG. Sex and limb differences in hip and knee kinematics and kinetics during anticipated and unanticipated jump landings: implications for anterior cruciate ligament injury. Br J Sports Med 2009;43(13):1049-1056.
- Saravanan P, Dominic D. Arthroscopic Acl Reconstruction Using Hamstring Tendon Autograft Fixed with Endobutton CL® and Biorci-HA® Interference Screw. Journal of Evolution of Medical and Dental Sciences. 2015;4(47):8190-8199.
- Pate JM, Chovatiya K, Rana H, Dabhi A. Comparison of different modalities of treatment for ACL tear. National Journal of Clinical Orthopaedics 2017; 1(3): 41-45.
- Nikolaou VS, Chronopoulos E, Savvidou C, Plessas S, Giannoudis P, Efsthathopoulos N, Papachristou G. MRI Efficacy in Diagnosing Internal Lesions of the Knee: A Retrospective Analysis J Trauma Manag Outcomes. 2008 Jun;2(2(1):4.
- Bomberg BC, McGinty JB. Acute Hemarthrosis of the Knee: Indications for Diagnostic Arthroscopy. Arthroscopy. 1990;6(3):221-5.
- Lu KH, Hsiao YM, Lin ZI. Arthroscopy for Acute Knee Haemarthrosis in Road Traffic Accident Victims. Injury. 1996 Jun;27(5):341-3.
- Johannsen HV, Fruensgaard S. Arthroscopy in the Diagnosis of Acute Injuries to the Knee Joint. Int Orthop. 1988;12(4):283-6.
- J. Gillquist, G. Hagberg & N. Oretorp (1977) Arthroscopy in acute injuries of the knee joint, Acta Orthopaedica Scandinavica, 48:2, 190-196.