



PRIMARY CEMENTED BIPOLAR HEMIARTHROPLASTY IN UNSTABLE OSTEOPOROTIC FRACTURE OF INTERTROCHANTRIC FEMUR IN ELDERLY PATIENT

Dr Supratim Roy	Department of Orthopaedics MGIMS , Sevagram.
Dr Kiran N Wandile*	Department of Orthopaedics MGIMS , Sevagram. *Corresponding Author
Dr Chandrashekhar M Badole	Department of Orthopaedics MGIMS , Sevagram.
Dr Rohan R Patil	Department of Orthopaedics MGIMS , Sevagram.
Dr Aniket K Wankhede	Department of Orthopaedics MGIMS , Sevagram

ABSTRACT **Background:** Inter trochanteric fractures are one of the most common injuries in orthopaedics with high incidence of morbidity due coexistent medical problems. 35-40% of total intertrochanteric fractures being unstable, is a major cause of disability and death in elderly. The main motive of performing bipolar hemiarthroplasty such fractures in elderly is early ambulation and to avoid complications associated with internal fixation.

Methods: 22 cases were operated with cemented bipolar hemiarthroplasty along with tension band wiring of trochanter by posterolateral approach. Results were analysed using standard Harris Hip Score.

Results: Out of 22 patients according to Harris Hip Score 8 patients had excellent results, 8 had good, 3 fair, 1 poor and 2 failed at the end of 1 year. Complications like dislocation , medial cortex fracture and shortening noted.

Conclusion: Cemented Bipolar Hemiarthroplasty in unstable Intertrochanteric fracture with osteoporosis can avoid complications associated with internal fixation and provide early mobilisation

KEYWORDS : Unstable Inter trochanteric fractures, cemented bipolar hemiarthroplasty, Harris Hip Score.

INTRODUCTION :

Intertrochanteric fractures make up 45% of all hip Fractures. 35% to 40% of intertrochanteric fractures are unstable, which are major cause of disability and death in elderly⁽¹⁾. Hip fractures are associated with high mortality among elderly after internal fixation that is 15%-20% in first 3 to 6 months and 30% at 12 month⁽²⁾. Cause of injury can be domestic fall or High velocity trauma seen in vehicular accidents. This has always remained a challenging problem for most of orthopaedic surgeons due to high incidence of morbidity along with other co-existent medical problems⁽³⁾

These old age patients have many associated diseases like diabetes mellitus, hypertension etc. In these patients due to combination osteoporosis and instability, early resumption to full weight bearing is difficult⁽⁴⁾

Stable intertrochanteric fractures can be easily treated by osteosynthesis with predictable good results.⁽⁵⁾ Failure rate of unstable intertrochanteric fractures with osteoporosis treated with osteosynthesis has been reported between 4% and 16.5%⁽⁶⁾ The weak and porotic bone tolerates screws poorly so cut out is a major problem in internal fixation⁽⁷⁾. The main motive of performing surgery in a unstable inter-trochanteric fracture femur is early ambulation and avoids complications associated with Open reduction and internal fixation in elderly osteoporotic patients.⁽⁸⁾ Bipolar hemiarthroplasty is an excellent and viable option for early ambulation and good early midterm survivorship with less implant related complications for elderly osteoporotic patients with comminuted intertrochanteric fracture femur.⁽⁹⁾

This study was done to evaluate the efficiency of primary Cemented bipolar hemiarthroplasty as a modality of treatment in unstable intertrochanteric fractures in osteoporotic elderly patients in terms of functional outcome in rural setup Mahatma Gandhi Institute of Medical Sciences.

METHODS :

In this study 22 elderly patients having Unstable Inter trochanteric fractures with osteoporosis were treated using cemented bipolar hemiarthroplasty. This study was conducted in the department of

orthopaedics, MGIMS Sewagram from May 2016 to October 2018. Patients in this study were sorted based on following inclusion and exclusion criteria.

Inclusion criteria:-

- 1) Elderly patients 65 years and above.
- 2) Patients were osteoporosis, graded by singh's index.
- 3) Unstable fractures.
- 4) Pre injury ambulatory patient

Exclusion criteria:-

- 1) Open Intertrochanteric Fractures
- 2) pathological fractures.
- 3) Polytrauma
- 4) vascular injury
- 5) Fractures with neurological involvement.
- 6) Infection or Poor skin conditions at operative site.
- 7) hip arthritis
- 8) ipsilateral fracture of the same limb.
- 9) Patients who did not give consent for the study

Fractures classified using Evan's Classification .

SURGICAL PROCEDURE :

Surgeries were performed in lateral position using posterolateral approach. After giving the skin incision, haemostasis is achieved. Tensor fascia lata cut in line with skin incision. Gluteus maximus muscle splitted. Short external rotators were identified and released from femoral attachment site after taking stay sutures and reflected. Sciatic nerve gets retracted along with rotators and thus protected. Capsule was identified and if intact cut longitudinally to expose hip joint and proximal part of femur.

Method of reconstruction

Greater trochanter was fixed by steel wires passing through lateral femoral shaft and under gluteus medius tendon in figure of 8 fashions. In some cases fracture anatomy was assessed and cut was taken high up in the neck to facilitate removal of head. When the lesser trochanter was in continuity with the neck, it was reconstructed with shaft and

greater trochanter with steel wire. Then neck was cut 1-2 cm above lesser trochanter depending on comminution. At time when lesser trochanter was found as separate entity, then its was difficult to reconstruct the calcar and then lesser trochanter and greater trochanter were fixed to shaft using steel wire and major portion of the neck sacrificed. Calcar was reconstructed using a graft from femoral neck. Cement was used in these cases to aid in calcar preparation. When the lesser trochanter was comminuted medial defect and calcar was reconstructed using cement mantle and greater trochanter if fractured en mass was fixed to shaft using steel wire and if fractured coronal plane was fixed with tension band technique. When the greater trochanter was severely comminuted it was sutured with ethibond along with soft tissue.

Femoral canal preparation was done by reamer and Rasp. Extracted head diameter was measured and noted and it helps to take out the appropriate size of prosthesis Some essential steps that we followed while doing hemiarthroplasty were-

Version of prosthesis- Imaginary trans condylar axis of lower end of femur was taken as guide. This was cross checked by temporarily reducing the lesser trochanter into its anatomical position and referring the endoprosthesis from it.

Femoral offset- In severely comminuted fractures it was difficult to determine prosthesis height properly. With trial implant in situ traction was applied to achieve the desired limb length by comparing with the opposite limb on table (both knees should be at same level). Applied traction cause femur to be pulled distally and the amount of distraction between prosthesis and femoral cut was noted and level on the prosthesis was marked. This gave the idea about length of prosthesis to be driven into femoral canal at the time of final cementing to achieve desired limb length. For the remaining portion cement mantle was made. Once the prosthesis was fixed the broken trochanter and calcar were tightened by tensioning the wire.

After reducing the prosthesis stability was checked in all range of movement. capsule was repaired and the operative wound closed in a layer over a negative suction drain and sterile dressing was done.

FOLLOW UP:

follow up done at 1 month, 3 months, 6 months and 1 year. During each follow up visit a clinicoradiological examination was done and the patient was evaluated using the Harris Hip score. Anteroposterior radiograph of the hip were analyzed at each follow up to note evidence of union of greater trochanter and loosening.

Harris Hip score for functional evaluation :

1. 90 -100- Excellent results
2. 80 -89- Good
3. 70 -79- Fair
4. 60 -69- Poor, and
5. <60 - as a failed result.

RESULTS :

In this study mean age was 74 with range of 65-85 years. Male outnumbered females accounting to 12(54.55%) and females proportion was 10(45.45%). There were more of right sided fractures accounting to 13 cases.

Singh's index used to find out severity of osteoporosis. Most of the participants 11(50%) belong to Grade II whereas 7(31.8%) were in grade III. Severe osteoporosis was seen in 4(18.2%) of the participants who were in grade I.

Most of the patient (81.82%) were operated within 3- 5 days of admission. Average Pre-operative period was found to be 4.5 days with range from 3-8 days.

Mean duration of surgery was 84.8 minutes with a range of 75-92 minutes.

Average duration of stay was 18.8 with minimum stay of 12 days and maximum stay of 27 days, maximum patients 13(59.1%) stayed for a duration of 16-20 days.

The average blood loss was 288.2 ml with range of 210-352 ml. 12 patients (54.5%) required 2 units of blood transfusion during hospital stay and 8 patients (36.4%) received 1 unit of blood transfusion that is 90.9 % cases needed blood transfusion.

15 patient (68.18%) started full weight bearing on 3rd day followed by 3 patients (13.6%) on 5th day. Maximum delay of 9th day occurred. Average time to bear full weight was 4th post operative day.

Intraoperatively 1 case (4.5%) had medial cortex fracture. During Post operative hospital stay 2 cases (9.1%) had superficial suture site infection. We encountered 2 cases (9.1%) of dislocation of prosthesis after discharge within duration of 1 month. In our study maximum (15 cases) patient had no shortening. A total of 7 cases(31.8%) had shortening of which 4 cases had shortening of less than 2 cm and 3 cases had shortening of 2 to <3 cm. Maximum shortening occurred up to 2.7cm.

Harris Hip Score in Follow Up Period:

Mean Harris hip score at 1 month was 65.7(±20.8), at 3 month mean score was 71.8(±15.9), at 6 month Harris hip score was 75.6(±17.2) and at 1 year Harris Hip Score was 80.7(±19.2).

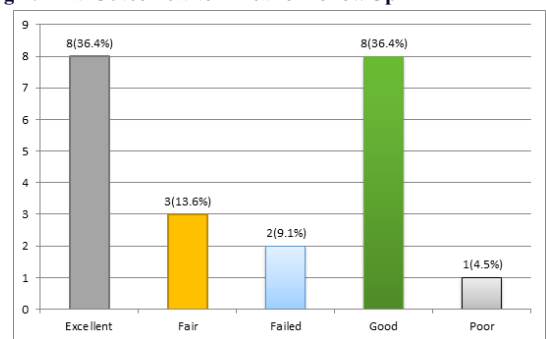
Table 1: Harris Hip Score in Follow up Period

Harris Hip Score In Follow Up Period	Mean	Std Dev
1 MONTH	65.7	20.8
3 MONTH	71.8	15.9
6 MONTH	75.6	17.2
12 MONTH	80.7	19.2

Final outcome

At final follow up of 1 year we achieved excellent outcome in 8 patients (36.4%), good outcome in 8 patients (36.4%) and fair outcome in 3 patients (13.6%). We could achieve excellent to fair outcome in 86.4% cases. There were only 2 failed cases (9.1%) and 1 case had poor outcome (4.5%)

Fig 1 : Final Outcome after 1 Year of Follow Up



RADIOLOGICAL OUTCOME

Case 1

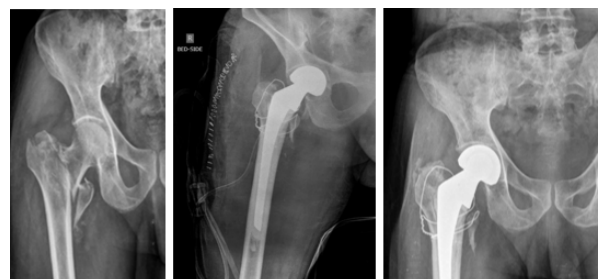

Fig 2: Preop xray post op xray 1 year followup xray

Case 2

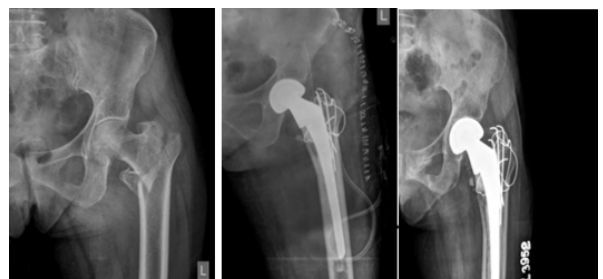

Fig 3: Preop xray post op xray 1 year followup xray

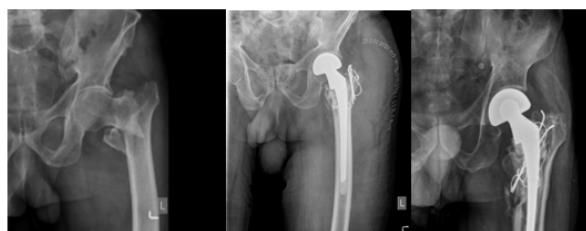Case 3

Fig 4: Pre-op xray post op xray 1 year follow-up xray

DISCUSSION

Complexity of intertrochanteric fractures in elderly osteoporotic patients possesses challenging problems, with an added risk of increased morbidity and mortality. Although union rates as high as 100 % have been reported in association with well reduced stable fractures that were treated with ideal implant placement, failure rates of as high as 56% have been noted in association with unstable fractures, comminuted fractures, sub optimal fracture fixation, or poor bone qualities in elderly patients.(10) Although internal fixation of such fractures may reduce the morbidity of pain, it does not permit an early mobilization with a fear of failure of fixation and thus, indirectly, the morbidity of fracture remains same. Early ambulation following surgeries are important for preventing complications that can be caused by long term bed rest in elderly patient with poor general condition. The poor mechanical properties of the weak and osteoporotic bones in elderly patients do not provide a good purchase for the screw which subsequently leads to an early bio mechanical failure. This leads to a collapse with migration of the femoral head into the varus and retroversion, resulting in limping which is caused by shortening and a decreased abductor muscle lever arm.(11) Another complication of internal fixation is that the implant can be cut out from the femoral head, which can lead to profound functional disability. Hemiarthroplasty is a frequently employed alternative, as it gives stability and allows full weight bearing.

All the cases in our study were operated by standard posterolateral approach. Rawate et al in their study from July 2008 to May 2010 also operated 34 patients by similar approach (12). It gives a good exposure with not much blood loss.

We reconstructed the fracture by fixing the greater trochanter with K wire and cerclage wire in figure of 8 manner and lesser trochanter was fixed with a cerclage wire around proximal femur. Reconstruction of greater trochanter is an important step of surgery for maintaining the stability of hip joint as done by Kiran Kumar G et al() and Bassiony A et al() with tension band wiring and cerclage wire.

We used cement in all cases for stem fixation and sometimes cement was used to reconstruct calcar and fill the medial defect. We did not observe any incidence of cement reaction though it is a serious complication and life threatening. Siwach R et al() in their study encountered 2 out of 3 cases of cement reaction where cement was used. Cement should be used cautiously in patients while doing bipolar hemiarthroplasty.

Cemented fixation is advantageous for achieving the initial implant stability and rapid rehabilitation. Cementation also enables early recovery of patient and allows painless early mobilization.

To assess the outcome of surgery many authors like Patil A et al(9) Sancheti K et al() Ingle M et al(), and Pradeep C et al (16) used Harris hip score as used in our study.

Mean blood loss was 288.2 ml which was comparable to other study as in Sancheti K et al(5) it was 350 ml, Patil A et al(9) 321 ml. Higher blood loss stated in study of Elmorsy A et al(17), mean of 567cc. Average duration of surgery in our study is 84.8 mins comparable with study by Sancheti K et al() (71 min) and Patil A et al(9)(61.35 min).

In this study there was no complications related to immobilization like pneumonia, DVT, Pulmonary embolism, or bed sore in post operative period due to early weight bearing following surgery. In our study the mean day of full weight bearing was 4th post operative day with support

of walker. In Sancheti's study() it was 3.2 day and 5.4th day in study by Puttakemparaju K and Beshaj N(18) and 4.7 days in study of Agrawal PV et al(19).

There was one case of Intraoperative Medial cortex (4.5%) fracture during stem insertion which was treated with encirclage. The final outcome was poor in this patient. Similar case of medial cortex fracture(2.4%) occurred in study by Elmorsy A et al (17) in which weight bearing was delayed up to 6 weeks.

Two patients (9.1%) had dislocation in this study 1 month following surgery due to fall at home out of which one case was operated by open reduction. The other patient did not give consent for surgery. Similar 1 case of dislocation(2.4%) occurred in study of Elmorsy A et al() which was also treated by open reduction. In study by Patil A et al(9) there was 2 cases of dislocation among 126 patients. One of them was treated by closed reduction under anesthesia and in other total hip replacement was done.

Shortening occurred in 7 patients (31.82%) post operatively in this study of which 4 patients had shortening less than 2 cm and 3 patient had shortening more than 2 cm but less than 3 cm. They walk with slight limp. In study by Sancheti K et al() 10 cases(27.02%) had shortening of average 1.1 cm. 16% patient had shortening less than 2 cm and 8% patient had shortening of more than 2 cm in study of Agrawal PV et al(19), 8 out of 126 patient had shortening treated by shoe raise in study of Patil A et al(9). Shortening was due to greater comminution at the fracture site in our study as also noted by Pradeep C et al(16) in 3 out of 25 cases in their study.

Elmorsy A et al() in their study noted 9.7% re-operation in 4 cases due to infection, dislocation, subsidence and acetabular wear. 5 cases under went revision in the form of total hip replacement and 1 case in the form of excision arthroplasty in study by Patil A et al(9). Total hip replacement was done for Implant loosening, Implant breakage, protrusion, recurrent dislocation and excision arthroplasty for deep infection. Tension band wiring with grafting along with freshening of fracture edges was done in 2 cases of non union of greater trochanter. Revision rate was 4.8%. In our study there was one case of revision surgery due to dislocation.

There was no death reported within a period of 1 year follow up in our study. 8% mortality within 6 months in study by Pradeep C et al(16) due to unrelated cause, 5.4% mortality within 6 months due to myocardial infarction, in study by Sancheti K et al()

We could achieve a mean Harris hip score at 1 month of 65.7(±20.8), at 3rd month mean score was 71.8(±15.9), at 6th month Harris hip score was 75.6(±17.2) and at 1 year Harris Hip Score was 80.7(±19.2). It was increasing trend of mean Harris Hip score among study participant favouring final outcome.

In our study we could achieve excellent result in 36.4 % patient, good in 36.4% patient, fair in 13.6% patient. 4.5 % patient had poor result and 9.1% patient had failed result. whereas in study by Sancheti K et al (5) there was 27.02% excellent result, 40.5% good, 18.9% fair, 5.4% poor and 2.7% failed result. Ingle M et al(4) had 65.4% excellent, 30.7% good and 3.85 % fair result. Agarwal PV et al (19) also had 24% excellent, 60 % good, 12% fair and 4 % poor result.

Primary hemiarthroplasty offers a modality of treatment that provides adequate fixation and early mobilization in these patients, thus preventing post-operative complications such as pressure sores, pneumonia, atelectasis, and pseudo arthrosis. Delays in the surgeries are one of the most important predictor of mortality in patients with intertrochanteric fractures and also of the postoperative morbidity. The cornerstone of management of such fractures is early surgery, followed by mobilization. Early mobilization is very essential, particularly in patients with other medical co morbidities and also to prevent post-operative complications.

CONCLUSION

Present study concludes that cemented bipolar hemiarthroplasty is a better option to avoid complications of internal fixation due to implant failure and non-weight bearing. It is an effective method to achieve early mobilization in elderly patient and resume their pre injury functional status and improved quality of life. This technique provides a stable, pain free and mobile joint with acceptable complication rate.

REFERENCES

1. GU G-s, Wang G, SUN D-h, QIN D-m, Zhang W. Cemented bipolar hemiarthroplasty with a novel cerclage cable technique for unstable intertrochanteric hip fractures in senile patients. *Chinese Journal of Traumatology (English Edition)*. 2008;11(1):13-7.
2. Moran CG, Wenn RT, Sikand M, Taylor AM. Early mortality after hip fracture: is delay before surgery important? *JBJS*. 2005;87(3):483-9.
3. Mulay S, Gouri F, Mahajan U. Treatment of Inter-trochantric Fracture by PFN or DHS. *International J of Healthcare and Biomedical Research*. 2015;3(03):209-15.
4. Ingle M, Sonar U, Koichade M, Yelne A, Radke A. Cemented bipolar hemiarthroplasty in unstable osteoporotic fractures of intertrochanteric neck femur in elderly patients: A prospective study.
5. Sancheti K, Sancheti P, Shyam A, Patil S, Dhariwal Q, Joshi R. Primary hemiarthroplasty for unstable osteoporotic intertrochanteric fractures in the elderly: A retrospective case series. *Indian journal of orthopaedics*. 2010;44(4):428.
6. Haidukewych GJ, Berry DJ. Hip arthroplasty for salvage of failed treatment of intertrochanteric hip fractures. *JBJS*. 2003;85(5):899-904.
7. Sheikh IS, No P, Colony P. Intertrochantric femur fracture in elderly treated with bipolar vs dhs-a prospective study. *Journal of Medical Thesis*. 2014;2(2):45-9.
8. Stern MB, Goldstein TB. The use of the Leinbach prosthesis in intertrochanteric fractures of the hip. *Clinical Orthopaedics and Related Research*. 1977;128:325-31.
9. Patil A, Ansari M, Pathak A, Goregaonkar A, Thakker C. Role of Cemented Bipolar Hemiarthroplasty for Comminuted Inter-trochanteric Femur Fracture in elderly osteoporotic patients through a modified Transtrochanteric approach-“SION Hospital Modification”. *IOSRJ Dental Med Sci*. 2013;9:40-7.
10. Haidukewych GJ, Israel TA, Berry DJ. Reverse obliquity fractures of the intertrochanteric region of the femur. *JBJS*. 2001;83(5):643-50.
11. Sinno K, Sakr M, Girard J, Khatib H. The effectiveness of primary bipolar arthroplasty in treatment of unstable intertrochanteric fractures in elderly patients. *North American journal of medical sciences*. 2010;2(12):561.
12. Rawate P, Kale AR, Sonawane CS. Functional Outcome of Cemented Bipolar Hemiarthroplasty for Unstable Intertrochanteric Fractures of Femur in Elderly: An Indian Perspective. *INTERNATIONAL JOURNAL OF SCIENTIFIC STUDY*. 2017;5(5):48-53.
13. Kiran Kumar G, Meena S, Kumar V, Manjunath S, MK VR. Bipolar hemiarthroplasty in unstable intertrochanteric fractures in elderly: a prospective study. *Journal of clinical and diagnostic research: JCDR*. 2013;7(8):1669
14. Bassiony A, Asal M, Mohamed H. Cemented calcar replacement hemiarthroplasty for unstable intertrochanteric fracture femur in elderly patients. *The Egyptian Orthopaedic Journal*. 2013;48(2):190-3.
15. Siwach R, Jain H, Singh R, Sangwan K. Role of hemiarthroplasty in intertrochanteric fractures in elderly osteoporotic patients: a case series. *European Journal of Orthopaedic Surgery & Traumatology*. 2012;22(6):467-72.
16. Pradeep C, Anuj A, Abhishek G. Treatment of Comminuted Unstable Inter-Trochanteric Fracture in Elderly Patients with Cemented Bipolar Prosthesis. *Indian Journal of Orthopaedics*. 2015;1(4):255-60.
17. Elmorsy A, Saied M, Zaied M, Hafez M. Primary Bipolar Arthroplasty in Unstable Intertrochanteric Fractures in Elderly. *Open Journal of Orthopedics*. 2012;2(1):4.
18. Puttakemparaju K, Beshaj N. Unstable intertrochanteric fracture in elderly treated with bipolar hemiarthroplasty: A prospective case series. *African Journal of Trauma*. 2014;3(2):81-6.
19. Agrawal PV, Wagh N, Pangavane S. To Study the Functional Outcome of Primary Cemented Bipolar Hemiarthroplasty in the Management of Unstable Inter-Trochanteric Fracture of Femur among Elderly. *MVP Journal of Medical Sciences*. 2017;4(1):78-83.