



## Radio Diagnosis

## FIBROLIPOMATOUS HAMARTOMA OF THE MEDIAN NERVE – RARE CAUSE OF DISTAL FOREARM SWELLING

**Dr. Aarthi Parthasarathy**

MD Department Of Radio Diagnosis, Santhi Social Services, Coimbatore, Tamilnadu

**Dr. Muhil Kannan\***

MD Department Of Radio Diagnosis, Santhi Social Services, Coimbatore, Tamilnadu  
\*Corresponding Author

## KEYWORDS :

## CLINICAL HISTORY:

45-year-old woman presented with a 2-year history right distal forearm swelling on the medial aspect that was gradually increasing in size. The lesion was smooth but tender, no associated skin changes were present .Altered sensations was felt in the right thumb along the swelling.

## IMAGING FINDINGS:

- MRI scan showed a lesion in the region of the median nerve at the level of distal forearm measuring 10 x 3.4 x3.0 cm. The elongated appearance of the lesion suggested a perineural origin .
- T1 and T2 images show enlargement of the median nerve was seen with thickened fascicles. The lesion showed interspersed high signal, which drops on fat suppression (T2 FATSAT) suggestive of fat. Compressed nerve bundles in between the fibro fatty elements .No significant enhancement was noted on administration of intravenous gadolinium.
- The normal nerve fibrils were interspersed in between the abnormal soft tissue and looked compressed. These imaging features give “coaxial cable-like” appearance on axial image and “spaghetti string” appearance on coronal image.

## DISCUSSION

- A fibrolipomatous hamartoma is a rare, benign, congenital lesion most commonly found in the median nerve, usually at the level of the wrist or hand[ 1 ] Fibrolipomatous hamartoma is usually present since birth due to hypertrophy of mature fat and fibroblasts infiltrating epineurium and perineurium resulting in fusiform nerve enlargement. It has marked predilection for median nerve (85%). [2]
- Fibrolipomatous hamartoma of the median nerve has been reported to be associated with macrodactyly and port-wine stain. Its natural history is a gradual increase in the size of the lesion along with symptoms of compressive neuropathy [3] When the median nerve is involved, patients may present with carpal tunnel syndrome or a slow-growing painless lump in the wrist or hand.
- While most commonly found in the median nerve, studies have reported the lesion at other sites such as the radial, ulnar, sciatic, and plantar nerves and in the lungs. [4] The gold standard for investigation is MRI. The pathognomonic appearance is that of low signal nerve bundles surrounded by high signal fibrolipomatous tissue on T1-weighted images, also called the cable sign. No other tumors have been found to have similar MRI characteristics.[5]
- Management of fibrolipomatous hamartomas can be conservative or surgical. Because MRI is often diagnostic, biopsy is often not needed to establish the diagnosis.[6] Surgical intervention is controversial and is only recommended for symptomatic management of this benign lesion.
- Documented management has been restricted to fibrolipomatous hamartomas arising from the wrist or fingers: carpal tunnel decompression, fibrofatty sheath debulking, microsurgical dissection of the neural elements, and excision of the involved nerve with or without grafting[ 6].The options are more limited in the elbow because excision of the median nerve at the elbow is associated with high morbidity and is not recommended.

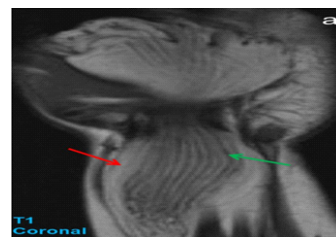
## FINAL DIAGNOSIS :

Fibrolipomatous Hamartoma of the Median Nerve – Rare cause of distal forearm Swelling

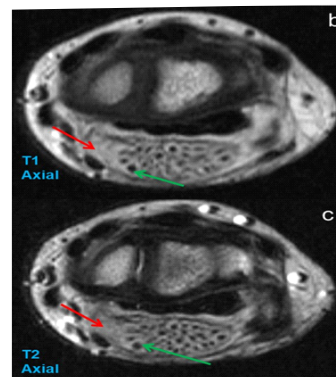
## DIFFERENTIAL DIAGNOSIS :

- Vascular malformations
- Ganglion cysts
- Nerve sheath tumors

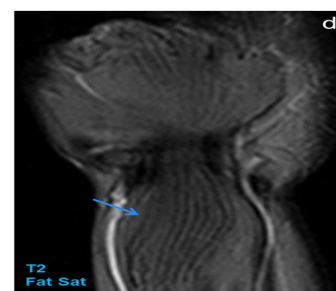
**FIGURE ORIGIN FOR ALL FIGURES WERE TAKEN FROM:**  
MRI PACS in Department of Radiology, Santhi Social Services, Coimbatore, Tamil Nadu



**Figure 1 – MRI in Department of Radiology , Santhi Social Services , Coimbatore ,Tamil Nadu**



**Figure 2 – MRI in Department of Radiology , Santhi Social Services , Coimbatore ,Tamil Nadu**



**Figure 3 – MRI in Department of Radiology , Santhi Social Services , Coimbatore ,Tamil Nadu**

**FIGURE CAPTION**

Figure A –T1 Coronal shows enlargement of the median nerve with thickened fascicles (low signal intensity on T1 (green arrow), interspersed high signal representing fat (red arrow))

Figure B –T1 and T2 Axial shows enlargement of the median nerve with thickened fascicles (low signal intensity on T1 and T2 (green arrow), interspersed high signal representing fat (red arrow))

Figure C –T2 FATSAT shows drop in signal signifying fat (blue arrow)

**REFERENCES**

1. Ha, J. F., Teh, B. M., Abeyseriya, D. T., & Luo, D. Y. (2012). Fibrolipomatous hamartoma of the median nerve in the elbow: a case report. *The Ochsner journal*, 12(2), 152–154.
2. Herrick RT, Godsil RD, Jr, Widener JH. Lipofibromatous hamartoma of the radial nerve: a case report. *J Hand Surg Am.* 1980 May; 5(3):211–213.
3. Goulesbrough DR, Kinny SJ. [1989] Lipofibromatous hamartoma of the ulnar nerve at the elbow: brief report. *J Bone Joint Surg Br. Mar;* 71(2):331–332
4. Johnson RJ, Bonfiglio M. [1969] Lipofibromatous hamartoma of the median nerve. *J Bone Joint Surg Am.* Jul; 51(5):984–990.
5. Berry MG, Mallucci P, Banwell PE, Heywood AJ [1999] Fibrolipoma of the median nerve. *JR Soc Med.* Aug; 92(8):408–409
6. Friedlander HL, Rosenberg NJ, Graubard DJ [1969] Intra-neural lipoma of the median nerve. Report of two cases and review of the literature. *J Bone Joint Surg Am.* Mar; 51(2):352–362.
7. Al-Qattan MM [2001] Lipofibromatous hamartoma of the median nerve and its associated conditions. *J Hand Surg Br.* Aug; 26(4):368–372