



EVALUATION OF POST OPERATIVE COMPLICATION OF MID SHAFT CLAVICLE FRACTURE

Dr.Rohit Amar

Senior Resident, Department of Orthopaedics AIIMS Patna.

Dr.Amaresh Kumar Ram*

Senior Resident, Department of Orthopaedics AIIMS Patna. *Corresponding Author

ABSTRACT

BACKGROUND: clavicle fractures are common fractures and the optimal treatment strategy remains debatable, It is impossible to support and immobilize a fracture of middle 3rd of clavicle in an adult by external means with figure-of-eight bandages. Clavicle fractures accounts for approximately 2.6% of all fractures in adults² 10% to 15% in children and comprise about 30 - 40% of all shoulder girdle injuries and 5% fractures occurs in medial end. The goal of clavicle fracture treatment is to achieve bony union while minimizing dysfunction, morbidity, and cosmetic deformity. Definitive indications for acute surgical intervention include skin tenting, open fractures, the presence of neurovascular compromise, multiple trauma, or floating shoulder. Outside of these indications, the management of displaced fractures of the mid shaft (Edinburgh type 2B) remains somewhat controversial.

MATERIAL AND METHODS: Patients included were cases of mid shaft clavicle fractures. 30 patients with mid shaft clavicle fractures were included in the study in the department of orthopaedics AIIMS Patna Bihar. (Mid shaft simple displaced and single butterfly fragment fracture), type 2 B2 (Mid shaft segmental fracture) classification. The patients were selected randomly and were divided in the following two groups of 15 patients each:

CONCLUSION: Operative treatment with either orif or imf leads, to improved short term functional outcome increased patient satisfaction, to maximise the healing potential of the bone, and to facilitate early and pain free recovery and MIPPO technique with the application of LCP offered an ideal combination in terms of bone fixation and soft-tissue sparing.

KEYWORDS : Clavicle fracture, operative, mid shaft treatment, conservative.

INTRODUCTION:

Clavicle fractures are common fractures, comprising 5 to 10 percent, of all fractures clavicle fractures are most commonly classified according to the allman classification, however, operative treatment is associated with an increased risk of complications and reoperations, while long term shoulder functional outcomes. it will likely bring to us images of simple injuries, simple treatments and favourable outcome. But of late a great deal of controversy exists in the management of clavicle fractures. Fractures of middle 3rd of clavicle are underestimated with respect to pain and disability during the first three weeks of treatment. It is impossible to support and immobilize a fracture of middle 3rd of clavicle in an adult by external means with figure-of-eight bandages¹.

Neer observed that only 3 of 235(0.1%) patients with middle third clavicle fracture treated conservatively healed whereas 2 of 45 patients (4.6%) treated with immediate open reduction and internal fixation. So, he felt, the primary cause of non -union to be open reduction and internal fixation¹¹.

Clavicle fractures accounts for approximately 2.6% of all fractures in adults² 10% to 15% in children and comprise about 30 -40% of all shoulder girdle injuries and 5% fractures occurs in medial end¹¹.

The goal of clavicle fracture treatment is to achieve bony union while minimizing dysfunction, morbidity, and cosmetic deformity.

Definitive indications for acute surgical intervention include skin tenting, open fractures, the presence of neurovascular compromise, multiple trauma, or floating shoulder. Outside of these indications, the management of displaced fractures of the mid shaft (Edinburgh type 2B) remains somewhat controversial. Recent literature is challenging the traditional belief that mid- shaft clavicle fractures uniformly heal without functional deficit¹¹.

Reported outcomes of surgical treatment of mid shaft clavicle fractures have become more favorable over the past 2 decades. A meta-analysis of current data on nondisplaced fractures suggested a relative risk reduction of 72% and 57% for nonunion as compared with non-operative treatment by use of intramedullary pin fixation and plate fixation, respectively¹¹.

With this background we carried out this study to evaluate the sign of union by x-ray finding- formation of callus, duration of surgery and post-operative skin complication in mid shaft clavicle fracture.

MATERIAL AND METHODS

This hospital based prospective, comparative study was carried out in department of orthopaedics at All india institute of medical science Patna Bihar. period of one year.

Patients included were cases of mid shaft clavicle fractures. 30 patients with mid shaft clavicle fractures were included in the study. All patients above 18 years of age were included in the study falling into Robinson's type 2 B1 (Mid shaft simple displaced and single butterfly fragment fracture), type 2 B2 (Mid shaft segmental fracture) classification.

Fracture of medial third clavicle and lateral third clavicle fracture were excluded from the study. Informed consent was obtained from all the patients.

Three follow-ups were assigned for the operated patients at 1 months, 2 months and 6 months. At each follow-up following investigations were done: X-ray of clavicle with shoulder Antero-posterior view, Chest X-ray- Postero-anterior view and specific investigations whichever need. Following points were noted at each examination: Patients with fracture clavicle supports the flex elbow of the injured side with the other hand. Abnormal swelling present in the middle third for middle third clavicle fracture and in the lateral third for lateral third clavicle fracture. The condition of the skin over the clavicle were noted for any abrasion, laceration and contusion. The movements of the affected side shoulder was restricted due to pain. The distal neurovascular status of the affected upper limb were examined and also the associated injuries along with fractured clavicle were noted. Palpation of the entire length of the affected clavicle for tenderness in the medial middle third or in the lateral third fracture compared to normal side.

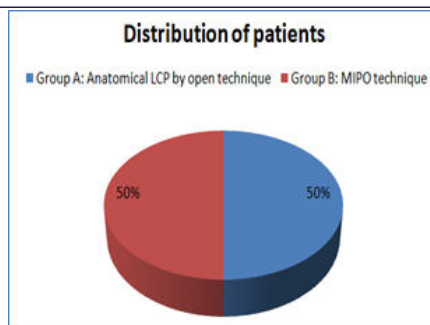
The patients were selected randomly and were divided in the following two groups of 15 patients each:

Group A: 15 patients treated by anatomical locking compression plate (LCP) by open technique.

Group B: 15 patients treated by minimal invasive percutaneous osteosynthesis (MIPO) technique

RESULTS

A total of 30 patients were included in the study. In group A 15 patients treated by anatomical locking compression plate (LCP) by open technique and in group B 15 patients treated by minimal invasive percutaneous osteosynthesis (MIPO) technique.



Majority of the patients in Group A (40%) and group B (46.7%) were in the age group of 31-40. There were 80% and 73.3% male patients in Group A and Group B respectively whereas female patients constituted 20% and 26.7% of the study group respectively. According to Robinson's classification, Type 2B1 and Type 2B2 was seen in 93.3% and 6.7% patients respectively in Group A while Type 2B1 and Type 2B2 was seen in 80% and 20% patients respectively in Group B. There was no significant association between the groups as per Chi-Square test ($p > 0.05$).

In Group A, 7 (46.7%) patients had operative time of 80-100 minutes whereas 6 (40%) and 2 (13.3%) patients had operative time of 100-120 and 120-140 minutes respectively. The mean operative time was 104.9 ± 13.52 mins.

In Group B, 6 (40%) patients had operative time of 80-100 minutes whereas 8 (53.4%) and 1 (6.6%) patients had operative time of 100-120 and 120-140 minutes respectively. The mean operative time was 106.5 ± 11.72 mins. There was no significant association between the groups as per Student t-test ($p > 0.05$).

Table 1: Comparison of Duration of Operative Time between groups

Operative Time (mins)	Group A		Group B		p Value
	N	%	N	%	
80-100 mins	7	46.7%	6	40%	>0.05
100-120 mins	6	40%	8	53.4%	
120-140 mins	2	13.3%	1	6.6%	
Total	15	100%	15	100%	
Mean±SD	104.9 ± 13.52		106.5 ± 11.72		

The mean duration of hospital stay in group A was 9.1 ± 4.06 days and in group B it was 8.5 ± 3.89 days.

The mean duration for radiological union in Group A was 12.7 ± 4.61 weeks. Majority of the patients (60%) achieved radiological union in <12 weeks while 6 (40%) patients achieved union in 12-24 weeks. In Group B, majority of the patients (66.7%) achieved radiological union in <12 weeks while 5 (33.3%) patients achieved union in 12-24 weeks. The mean duration for radiological union in Group B was 12.1 ± 6.68 weeks.

Two (13.3%) patients in Group A had shoulder stiffness while 1 (6.7%) patient each had plate prominence and infection. 2 (13.3%) patients each in Group B had shoulder stiffness and plate prominence while 1 (6.7%) patient had infection.

Table 2: Distribution of patients according to Complications

Complications	Group A		Group B		p Value
	N	%	N	%	
Shoulder Stiffness	2	13.3%	2	13.3%	>0.05
Plate Prominence	1	6.7%	2	13.3%	
Infection	1	6.7%	1	6.7%	

2 (13.3%) patients in Group A had shoulder stiffness while 1 (6.7%) patient each had plate prominence and infection. 2 (13.3%) patients each in Group B had shoulder stiffness and plate prominence while 1 (6.7%) patient had infection.

During 1 month follow-up period, 12 (80%) patients each in Group A and Group B had excellent score while 1 (6.7%) patient each had good score. Fair score was observed in 1 (6.7%) and 2 (13.3%) patients of Group A and Group B respectively whereas poor score was observed in 1 (6.7%) patient of Group A.

During 2 months follow-up period, 13 (86.7%) and 14 (93.3%) patients in Group A and Group B respectively had excellent score while 1 (6.7%) patient in Group A had good score. Fair score was observed in 1 (6.7%) patient each of Group A and Group B. During 6 months follow-up period, all patients in Group A and Group B had excellent score. There was increase in the functional outcome of patients in both the groups but the increase was statistically not significant ($p > 0.05$).

DISCUSSION:

The clavicle bone is S-shaped with a medial convexity and a lateral concavity. The middle third is the thinnest part of the clavicle and is located directly under the skin with no soft tissue or muscle attachment. Thus, it is vulnerable to direct and indirect trauma. This explains the high frequency of fractures in the middle third.

Fractures of the clavicular shaft were considered to be a domain of non-operative treatment for a long time. This dogma was based on the studies conducted by NEER CS and Rowe CR in the 1960s¹.

Open reduction and internal fixation with plates (plate osteosynthesis) is still the standard method for the surgical treatment of clavicular shaft fractures^{vi}. The goal of surgical treatment is the anatomic reduction with reconstruction of clavicular length and alignment of the shoulder girdle. To prevent early stress fracture of the implant, a fairly strong implant in comparison to the bone strength should be chosen. LCP have been preferred for plate osteosynthesis of the clavicle. The advantages of LCP include strong fixation due to locking between the screw and plate, and blood supply preservation due to minimal contact between plate and cortical bone^{vii}. Surgical treatment of displaced mid clavicular fractures with locking compression plate, which can be shaped to match the shape of the clavicle, can be effective in the treatment of clavicle mid shaft fractures. However, it remains some problem such as increased soft tissue stripping, infections, extensive scars, supraclavicular nerve injury.

Jiang H et alⁱⁿ their randomized, controlled, clinical trial compared minimally invasive percutaneous plate osteosynthesis (MIPPO) technique and conventional open reduction with LCP for the treatment of clavicle mid shaft fractures in adults found in MIPPO group 20 males and 12 females with a mean age of 40 years (range, 20 to 70 years). In the conventional open reduction group there were 20 males and 12 females with a mean age of 45 years (range, 18 to 69 years). These findings were in accordance with our study^{viii}.

Ravi KB et al^{ix} prospective study on operative management of clavicle fracture by Locking Compression Plate (LCP) and assess the functional outcome of clavicle fracture treated with open reduction and internal fixation with LCP found patients ranging from the age of 18-60. Among them the highest number of patients in the age group of 21-30 years (43.3%). The mean age was 36 years and among 30 patients, 27 (90%) were males and 3 (10%) were females.

It was observed in our study that in Group A, 7 (46.7%) patients had operative time of 80-100 minutes whereas 6 (40%) and 2 (13.3%) patients had operative time of 100-120 and 120-140 minutes respectively. The mean operative time was 104.9 ± 13.52 mins. In Group B, 6 (40%) patients had operative time of 80-100 minutes whereas 8 (53.4%) and 1 (6.6%) patients had operative time of 100-120 and 120-140 minutes respectively. The mean operative time was 106.5 ± 11.72 mins. prospective study reported 3.3% of the patient had hospital stay of 1-3 days, 63.3% had a stay of 4-6 days, 20% stayed for 7-10 days, 6.7% were admitted for 11-16 days and 6.7% were hospitalised for 17 or more days. Mean hospital stay was of 7 ± 5 days.

In Group A of our present study, majority of the patients (60%) achieved radiological union in <12 weeks while 6 (40%) patients achieved union in 12-24 weeks. The mean duration for radiological union in Group A was 12.7 ± 4.61 weeks. In Group B, majority of the patients (66.7%) achieved radiological union in <12 weeks while 5 (33.3%) patients achieved union in 12-24 weeks. The mean duration for radiological union in Group A was 12.1 ± 6.68 weeks. There was no significant association between the groups as per Chi-Square test ($p > 0.05$). Jiang H et al^x, Ravi KB et al^{xi} and Ethiraj P et al^{xii} noted similar observations in their studies.

In the present study, 2 (13.3%) patients in Group A had shoulder stiffness while 1 (6.7%) patient each had plate prominence and

infection. 2 (13.3%) patients each in Group B had shoulder stiffness and plate prominence while 1 (6.7%) patient had infection Al-Sadek TA et al¹ study assessing patients treated with minimally invasive plate osteosynthesis (MIPO) in Mid shaft Clavicle Fractures reported All fractures healed within a mean period of 4.9 months (range, 2- 10 months). Almost of all the cases didn't need bending of the plate.

CONCLUSION

MIPOs can be used to preserve the biology at the fracture site, to maximise the healing potential of the bone, and to facilitate early and pain free recovery and MIPPO technique with the application of LCP offered an ideal combination in terms of bone fixation and soft-tissue sparing.

REFERENCES

1. Rowe CR. An atlas of anatomy and treatment of midclavicular fractures. *ClinOrthop*. 1968;58:29–42.
2. Neer CS. Nonunion of the clavicle. *JAMA*. 1960;172:1006–1011.
3. O'Neill BJ, Hirpara KM, O'Brian D et al. Clavicle fractures: a comparison of five classification systems and their relationship to treatment outcomes. *IntOrthop* 2011;35:909.
4. Canadian Orthopaedic Trauma Society (MD McKee, principal investigator). Plate fixation versus nonoperative care for acute, displaced midshaft fractures of the clavicle. *J Bone Joint Surg*. 2007;89A:1–11
5. Zlowodzki M, Zelle BA, Cole PA et al. Treatment of midshaft clavicle fractures: systemic review of 2144 fractures. *J Orthop Trauma*. 2005;19:504–507
6. Smekal V, Oberladstatter J, Struve P et al. Shaft fractures of the clavicle: current concepts. *Arch Orthop Trauma Surg* 2009;129:807—15
7. Perren SM. Evolution and rationale of locked internal fixator technology. Introductory remarks. *Injury* 2001;32(Suppl. 2):B3—9
8. Jiang H and Qu W. Operative treatment of clavicle midshaft fractures using a locking compression plate: comparison between mini-invasive plate osteosynthesis (MIPPO) technique and conventional open reduction. *OrthopTraumatolSurg Res* 2012; 98: 666-671
9. Ravi KB, Ravishankar J, Shetty P et al. Operative management of clavicle fractures by LCP. *International Journal of Orthopaedics Sciences* 2017; 3(3): 519-530
10. Al-Sadek TA, Niklev D, Al-Sadek A. MidshaftClavicular Fractures - Osteosynthesis with Minimally Invasive Technique. *Open Access Macedonian Journal of Medical Sciences*. 2016;4(4):647-649