



INTERTROCHANTERIC FRACTURES FIXATION WITH PFN AND PFNA2 PROXIMAL FEMORAL NAILS- PROSPECTIVE RANDOMISED COMPARATIVE STUDY ASSESSING FUNCTIONAL OUTCOME

Dr. Yogesh Sharma	Professor, Dept. of Orthopaedics, MMIMSR, Mullana.
Dr. Yogesh Malik	Senior Resident, Dept. of Orthopaedics, MMIMSR, Mullana
Dr. Dhritobroto Bhattacharjee	3 rd Year PG Resident, Dept. of Orthopaedics, MMIMSR, Mullana
Dr. Rijuta De	2 nd Year PG Resident, Dept. of General Surgery, MMIMSR, Mullana.
Dr. Dhruv Gautam	3 rd Year PG Resident, Dept. of Orthopaedics, MMIMSR, Mullana.
Dr. Srikant Maheshkumar Pandya	3 rd Year PG Resident, Dept. of Orthopaedics, MMIMSR, Mullana.

ABSTRACT **Introduction:** Trochanteric fractures are among the most common injuries which are usually resulting from minimal to moderate physical trauma to areas of bone significantly weakened by osteoporosis. The greatest problems for the orthopaedic surgeon to treating the unstable trochanteric fracture and the complications (implant failure, varus collapse, non-union) occur from fixation that result of instability. The implants have evolved from extramedullary implants like dynamic hip screw to the intramedullary types of PFNA2 nail. **Material And Methods :** 50 patients were included in our study from July 2019 to July 2021. 25 patients were treated with PFNA2 (Group I) and 25 patients with PFN (Group II) Nails. **Results :** Mean blood loss during surgery was 153.8±10.92 & 201.6±38.48 in group I & group II respectively and the mean duration of surgery in group I and group II was 65.24+6.57 min and 85.44 + 11.08 min respectively. **Conclusion :** We concluded that use of helical blade PFN is certainly better in 31A2.2 and 31A3.3 type of fracture than screw PFN.

KEYWORDS : PFN (Screw), PFNA2 (Helical blade), intertrochanteric fractures

INTRODUCTION:

Trochanteric fractures are among the most common injuries. Proximal femoral fractures in elderly are usually resulting from minimal to moderate physical trauma to areas of bone significantly weakened by osteoporosis. In younger patients, proximal femoral fractures are usually the result of high energy physical trauma. Surgery has been the mainstay of the treatment for these fractures to allow early mobilization of the patient, with partial weight bearing restrictions, depending on the stability of the reduction and fixation achieved. Among the surgical treatment, dynamic hip screw (DHS) as extramedullary power transmission system and proximal femoral nail (PFN) as the means of intramedullary stabilization are the established and standard in the treatment of trochanteric femoral fractures, particularly in elderly patients with osteoporotic bone.

MATERIAL AND METHODS :

It is a hospital based Prospective Randomised Comparative Study which includes fractures in adults and elderly patients of both genders. The study was done between July 2019 to July 2021 at Orthopaedic wards in Maharishi Markandeshwar Institute of Medical Sciences and Research, Mullana (Ambala), Haryana. The study was conducted on fifty patients [(25 cases by PFNA2 (Helical Blade) and 25 cases by PFN (Screw)] of unstable intertrochanteric femoral fractures by using Harris Hip Score.

Inclusion Criteria

- Close unilateral unstable fracture intertrochanteric femur.
- AO/OTA fractures 31A2.2 through 31A3.3.
- Elderly (50 - 80 years of age or more) patients.
- Patient's who are willing to give consent.
- No associated injuries.

Exclusion Criteria

- Open and pathological intertrochanteric fracture.
- Patients with vascular injury.
- Medically or anaesthetically unfit patients.
- Patient refusing consent for surgery.

RESULTS AND OBSERVATIONS :

Table 1: Distribution According To Type Of AO Classification Of Fracture In Two Groups

	Group I (N=25)	Group II (N=25)
31A2.2	13	11

31A2.3	12	14
Total	25	25

Table 2 : Distribution Of Surgical Time Between Two Groups Of Subjects

	Mean	Sd	P value	Difference
Group I (N=25)	65.24	6.57	0.0004	Highly
Group II (N=25)	85.44	11.08		

Table 3 : Amount Of Blood Loss (ml) Between Two Groups Of Subject

	Mean	Sd	P value	Difference
Group I (N=25)	153.8	10.92	0.0024	Significant
Group II (N=25)	201.6	38.48		

Table 4 : Bone Union Duration (In month)

	Mean	Sd	P value	Difference
Group I (N=25)	3.66	0.45	0.290	Non
Group II (N=25)	3.80	.20		Significant

Table 5 : Complications

	Group I (N=25)	Group II (N=25)
Screw cut out	1	-
Z Effect	-	2
Non union	-	-
Implant failure	1	2
Wound infection (superficial)	-	1
Total	2	5

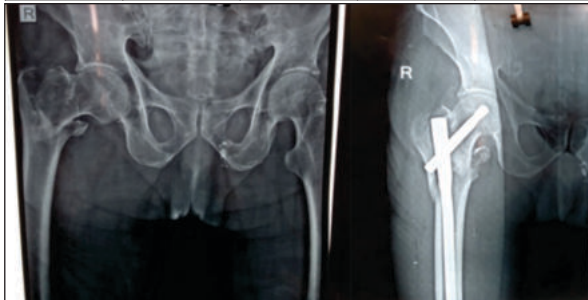
Table 6 : Limb Length Discrepancy

Limb length discrepancy	Group I (n=25)		Group II (n=25)	
	No.	%	No.	%
0 cm	15	60	13	52
1 cm	7	28	9	36
2 cm	3	12	3	12
Total	25	100	25	100

Table 7 : Functional status (Harris Hip Score)

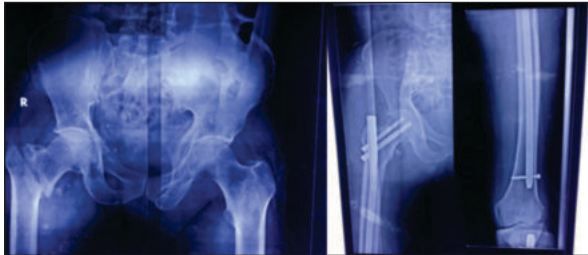Grade	Group I (n=25)		Group II (n=25)	
	n	%	n	%
Excellent	12	48	11	44
Good	10	40	9	36

Fair	2	8	3	12
Poor	1	4	2	8
Total	25	100	25	100



Intertrochanteric Fracture

Post operative IT fracture using PFNA2



Intertrochanteric Fracture

Post operative IT fracture using PFN

DISCUSSION

Treatment of intertrochanteric fractures superadded with osteoporosis is a challenge in the community of orthopaedic surgeons. Screw pull-out in a dual screw design due to osteoporosis in old age is the most common cause of implant failure.

The aim of management accordingly has drifted to achieving early mobilization, rapid rehabilitation and quick return of individuals to pre-morbid home and work environment as a functionally and psychologically independent unit.

In this study an attempt was made to survey, evaluate, document and quantify and compare the results of patients treated by using Helical proximal femoral nail (PFNA2) and Screw proximal femoral nail (PFN) implants. The study was conducted on fifty patients (25 cases by PFNA2 and 25 cases by PFN) of unstable intertrochanteric femoral fractures attending outpatient / casualty department of Orthopaedics, Maharishi Markandeshwar Institute of Medical Sciences and Research, Mullana(Ambala), Haryana (During the study period between July 2019 to July 2021).

Amongst the various types of implants available i.e. fixed nail plate devices, sliding nail/screw plate and intramedullary devices, the compression hip screw is most commonly used (still remains the GOLD STANDARD) but recently techniques of closed intramedullary nailing have gained popularity.

In present study, the cases of unstable intertrochanteric femur fracture were taken. 50 (100%) cases had AO type, 31A2.2 & 31A2.3. The most of the patients of trivial injury had 31A2.3 type of fracture in both the groups. In our study not include A1 and A3. Jung Ho Park et al (2010) in term of AO classifications in the screw proximal femoral nail group, 5, 10, and 2 patients were classified A1, A2 and A3 respectively, and in helical proximal femoral nail group, 7, 13, and 3 patients were classified A1, A2, and A3, respectively. Fracture subtype classifications showed no statistical difference.

The mean duration of surgery in group I and group II was 65.24±6.57 min and 85.44 ± 11.08 min respectively while compared to Jung HO Park et al (2010) in Group I – 83.33 min and in Group II – 86.12 min. Mean blood loss during surgery was 153.8 ml in group I and 201.60 ml in group II while in the study of Kumbaraci M et al. (2017) mean blood loss in Group I - 126.8±49.5 and in Group II - 162.8±45.6.

In present study observation shows that bone union duration in Mean +SD in group I & group II was 3.66±0.45 & 3.80±0.20 in month respectively. Jung Ho Park et al (2010) observed similar time of bone

union in the screw proximal femoral nail groups was (3.82 months) and helical proximal nail group (3.43 months), and this was not significantly different.

In the present study, Group I had screw cut and implant failure in 1 case and in Group II Z effect, implant failure and wound infection had 2 cases. In another study Manoj R. Kasid in (2016) also found similar results.

The present study showed that 60% patients of group I and 52% of group II had no LLD. Maximum shortening (2 cm) was found in only three patient of group I, whereas, in group II three patients were found. Manoj R. Kasid et al (2016) The loss of reduction including shortening (>1 cm) (p=0.684) and varus malalignment (p=0.552) were similar between the two groups though they were relatively lower in PFNA group as compared to PFN group.

The functional status according to Harris Hip Score was excellent in 48% in Group I and In Group II 44%, good in Group I 40% and in Group II 36%, fair in Group I 8% and in Group II 12% cases and poor in 4% group I and 8% in Group II cases. Mean Harris hip score is group I 85.15 and in Group II 83.12. Manoj R Kashid et al in their study of PFNA2 had mean Harris hip score of 88.48.

Mean Singh's indexes of the helical proximal femoral nail groups and screw proximal femoral nail groups were 2.12 and 2.60, respectively, which were significantly different (p =0.035). It's denote helical proximal femoral nail group had more osteoporotic bones. Jung Ho Park et al 2010 Mean singh's indexes of the helical proximal femoral nail groups and screw proximal femoral nail groups were 2.46 and 2.67, respectively which were not significantly different (p=0.59).

In the present study in both groups maximum cases were due to triva injury.

In the present study of X-ray exposure shots mean±SD was 35.0±4.44 & 70.56±10.76 in group I & group II respectively which is highly significant (p<.0006). This is because of more accuracy required in screw proximal femoral nail for putting two screw. Manoj R. Kasid et al 201633 observed that mean number of images taken per-op was significantly lower in PFNA group as compared to PFN group (18.60 ± 3.12 vs 29.52± 4.85 (p<0.001).

CONCLUSION :

we can conclude that use of helical blade PFN is certainly better in 31A2.2, 31A2.3 type of fracture than screw PFN. The claimed advantage with helical blade PFN is that a single neck screw without drilling neck in osteoporotic bone which provides better contact area between helical blade and bone which have lesser chance of screw cutout or Z-effect. Helical blade PFN is less operative and less fluoroscopy time with minimal surgical blood loss and with better functional and radiological outcome than screw PFN.

REFERENCES

1. Jung HO Park, Yong Seuk Lee, Jong Woong Park, Jae Gyoong Kim.: Orthopedics February 2010; 33(2): 81-5.
2. Manoj R. Kashid, Tushar Gogia, Anjan Prabhakara, Mohammad A. Jafri, Dilip S. Shaktawat, Gopal Shinde. Int J Res Orthop. 2016 Dec; 2(4): 354-358.
3. Singh's index for osteoporosis, Wheelless textbook of orthopedics.
4. Harris WH. Traumatic arthritis of the hip after dislocation and acetabular fractures: treatment by mold arthroplasty. An end-result study using a new method of result evaluation. J Bone Joint Surg Am. 1969 Jun; 51(4):737-55.
5. Shashikant S Gadhe, Pramod Bhor, Ibad Patel, Arvind J Vatkar, Sachin Kale and Dr. Gaurav Kanade : Comparative study of PFNA vs PFNA 2 in unstable intertrochanteric fractures: A randomised control study of 50 cases. International Journal of Orthopaedics Sciences 2019; 5(3): 162-164.
6. Sharan Mallya, Surendra U. Kamath, Arkesh Madegowda, Sunil Lakshimpura Krishnamurthy, Manesh Kumar Jain, Ramesh Holla : Comparison of radiological and functional outcome of unstable intertrochanteric femur fractures treated using PFN and PFNA-2 in patients with osteoporosis. European Journal of Orthopaedic Surgery & Traumatology. 2019; 29 : 1035-1042.
7. Masuraj Atal Bihari Mandal, Rajnish Kumar, Dilip Kumar Singh, Vidya Sagar, Nitin Kumar and Rakesh Chaudhary. Comparative study of PFN vs PFNA 2 in intertrochanteric fractures: A randomised control trial. IJOS 2020; 6(4): 461-465.