



A STUDY OF RHINO-ORBITAL-CEREBRAL MUCORMYCOSIS CASES AT A TERTIARY CARE HOSPITAL.

Dr. Arundhati Pande

Associate Professor , Department of Ophthalmology, Smt Kashibai Navale Medical College and General Hospital.

Dr. Snehal Phalke*

Junior resident , Department of Ophthalmology , Smt Kashibai Navale Medical College and General Hospital. *Corresponding Author

ABSTRACT

Introduction: Mucormycosis is an aggressive opportunistic fungal infection. The fungus that causes the disease is ubiquitous in nature and is found in soil and on decaying vegetation. Because the fungus is so widespread, humans are exposed to it on a regular basis. The spores of the fungus are inhaled through the mouth and nose, but infection rarely occurs in a person with an intact immune system because macrophages phagocytize the spores. However, an immunocompromised individual is unable to mount an effective immune response against the inhaled spores; thus, germination and hyphae formation occur and infection develops, most commonly in the sinuses.[1] They may enter the orbit or brain parenchyma, causing sino-orbital and/or rhino-orbital-cerebral mucormycosis, respectively.[2]

Aim: The study aims at providing demographic data of the patients, risk factors for the disease , presenting signs and symptoms, intervention done and outcome of the treatment.

Methods: This was a prospective, interventional study done in a tertiary care hospital carried out from May 2021 to July 2021

Results: With 40 patients under study, the mean age of patients was 52.4 years. The incidence was more in males (80%) than in females. 95% patient had history of COVID-19. In these patient, the treatment of COVID-19 received were either Steroids (92%), O2 therapy (57.5%) or had an ICU stay (37.5%). T2DM was present in 62.5% while T1DM in 2.5%. These patients mainly received Intravenous Amphotericin-B (92.5%) along with Syrup Posaconazole as medical management. Functional Endoscopic Sinus Surgery(FESS) was done in all the patients while Maxillary Debridement or Maxillectomy was done in 42.5% patients. In Ophthalmic conservative line of management 37.5% received Transcutaneous Retrobulbar Amphotericin B (TRAMB) . 10% patients underwent Exenteration who presented in later stages of the disease. In spite of all the interventions, 22.5% succumbed due to low health conditions.

Conclusion: Corticosteroids followed by DM were the commonest pre-disposing factor for COVID-19 related Mucormycosis. Early FESS and timely TRAMB reduced the spread of the disease and conserved vision respectively.

KEYWORDS : COVID-19, Mucormycosis, TRAMB, Exenteration, Amphotericin-B

INTRODUCTION

A drastic spike of cases of Rhino-Orbital-Cerebral Mucormycosis (ROCM) have been seen during this COVID-19 pandemic. Because mucormycosis may involve the orbit and other ocular structures, the ophthalmologist may be the first physician to see a patient with this highly morbid condition.

METHODS AND MATERIAL

We performed a Prospective, Interventional study on 40 patients admitted in mucus ward of a tertiary care centre who had ROCM and concurrent or past history of COVID-19 infection. Patients with any symptoms or signs suspicious of Mucormycosis were evaluated at presentation with a detailed history, clinical signs, ENT, ophthalmic, and neurological examination to assess the extent of disease followed by diagnostic nasal endoscopy and KOH mount was sent.^[3] Investigations for the treatment plan include CT-PNS, MRI (Brain+Orbit+PNS) and Histopathology. Wherein Histopathology was useful for confirming the diagnosis and radiological imaging to know the extent of spread of the disease and help in surgical plan.^[4]

RESULTS-

DEMOGRAPHIC DETAILS:

Out of 40 patients, 8 were females and 32 were males. The average incidence age was 52 years (ranging from 30 years old to 82 years old).

RISK FACTORS:

Pre-disposing risk factors in descending order are listed in the table below:

Table No.1 : High Risk Factors For Mucormycosis

Pre-disposing factors	Number out of 40	%
1. COVID-19 infection	38	95
2. Steroids	37	92.5
3. O2 therapy	23	57.5
4. Diabetes		
(a) Type 1	01	2.5
(b) Type 2	25	62.5
5. ICU stay	15	37.5

Clinical Presentation:

Ocular signs and symptoms encountered in 23 patients (57.5%). Rest

17 patients showed ophthalmic examination within normal limits though they had ENT or dental symptoms or signs. Varied Ocular symptoms and signs seen are listed below:

Table No.2 : Ocular Signs And Symptoms

Symptoms and Signs	Number out of 40	%
1. Orbital Pain	2	5
2. Decreased vision	2	5
3. No PL	9	22.5
4. Lid Oedema	5	12.5
5. Ptosis	13	32.5
6. Conjunctival Chemosis	6	15
7. RAPD	8	20
8. Movement Restriction	5	12.5
9. Complete Ophthalmoplegia	9	22.5
10. Eschar	2	5
11. Proptosis	10	25
12. CRAO	2	5

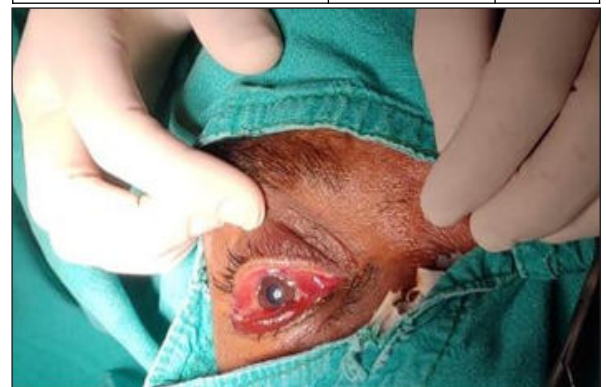

Fig No.1 : Right Eye Of Patient Showing Conjunctival Chemosis & Mid-dilated Pupil.

IMAGING:

15 (37.5%) out of the total patients showed normal orbital findings on

imaging. Imaging of 7 patients could not be due to low general health condition (ventilated or tracheostomised) who eventually succumbed. 18 Imaging films showed orbital involvement which are enlisted as follows:

Table No.3: Percentage Of Various Findings Seen On MRI Orbit

Findings	Number out of 18	%
Extraconal medial wall fat stranding	6	33.3
Extraconal inferior wall fat stranding	6	33.3
Retrobulbar Space	4	22.2
Bulky EOM	3	16.6
Orbital Apex	2	11.1
Both Intraconal + Extraconal fat stranding	2	11.1
Extraconal lateral wall fat stranding	1	5.5
Orbital Cellulitis	1	5.5

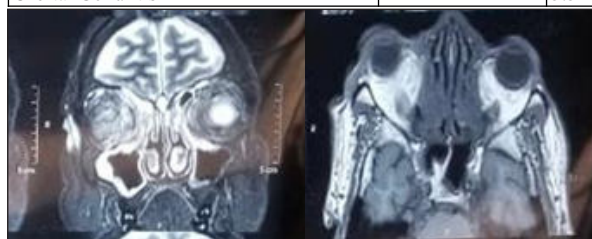


Fig No.2 and 3 : MRI(Brain+Orbit+PNS) Showing Extensive Fat Stranding In Right Orbit In Coronal And Axial Section Respectively.

INTERVENTION:

ENT (Ear, Nose and Throat) experts used FESS to clear the sinuses from infection in all 40 patients.

OMFS (Oral Maxillofacial Surgeon) operated patients for Maxillary Debridement or Maxillectomy depending on severity of maxillary sinus involvement and was done in 42.5% of the patients.

In Ophthalmic Management, 17 (42.5%) being clinically within normal limits no ophthalmic intervention was done. 4 (10%) patients underwent Lid Sparing Exenteration, 15 (37.5%) patients received TRAMB and 4 (10%) succumbed even before exenteration could be performed.

Out of 15 TRAMB given, 6 (42.8%) ocular status improved, 6 (42.8%) ocular status remained same as before TRAMB, 1 (7%) ocular status deteriorated after TRAMB.

The commonest complication seen after TRAMB was pain followed by Chemosis and subconjunctival haemorrhage. Mild proptosis was noted in few cases. One patient had complication of 3rd nerve palsy noted.

DISCUSSION:

Mucormycosis is amongst the most fulminant form of Zygomycosis caused by Mucorales species of the phylum Zygomycota.^[5]

The studies for pathogenesis of the infection show that there are alterations in cell-mediated immunity, such as chemotaxis, phagocytosis and cytokine secretion in Diabetics. Thus T-cells (CD4+ and CD8+) that produce cytokines such as interleukin (IL) 4, IL-10, IL-17 and interferon-gamma (IFN- γ) and damage the fungal hyphae lack in such patients leading to pre-disposition to infection.^[6] Also procoagulant state and vasoconstriction lead to ischaemia and hence necrosis.

Early sign and symptoms of Rhino-Orbital Mucormycosis include fever, sinusitis, nasal discharge, epistaxis, orbital and periorbital pain, nasal mucosal ulceration, crusting, and necrosis.^[7] A black eschar over skin, nasal mucosa, or palate discoloration are characteristic of mucormycosis. Decreased vision, proptosis, periorbital edema, and complete external ophthalmoplegia are the most common ophthalmic features. Other ophthalmic signs and symptoms include ptosis, chemosis, congestion, internal ophthalmoplegia, and corneal anaesthesia^[8]. Sudden blindness can occur due to central retinal artery occlusion, thrombosis of posterior ciliary arteries, infarction of the intraorbital part of optic nerve, or direct fungal invasion of the intracranial part of the optic nerve or optic chiasm.^[9] It can also present less commonly as a painless orbital apex syndrome without any signs of orbital cellulitis.^[10] From the orbit, the infection can spread to brain

through cribriform plate and orbital apex. Invasion of the cavernous sinus and cavernous part of carotid artery can lead to carotid occlusion, cerebral infarction, intracranial aneurysm/hemorrhage, fungal meningitis, mycotic abscess, and, eventually, death.^[11]

A scoring system was devised by a team of experienced ENT surgeons and Ophthalmologists in from prior experience in managing mucormycosis.^[12]

The scoring system is based on 3 main criteria, namely:

1. Clinical signs and symptoms
2. Direct and Indirect Ophthalmoscopy
3. Imaging.

Severity marked as :

- 1 point = Mild symptoms/s
- 2 points = Moderate symptoms/signs
- 3 points = Severe symptoms/signs

Table No.4: Clinical Symptoms

	0	2	3
Vision	Normal or same as prior to other symptoms	Decreased vision after developing other symptoms	Total blindness
Pupil	Normal	RAPD	Fixed
Ocular motility	Normal	Extra-ocular muscle palsy/Diplopia	Fixed eyeball
Proptosis	Absent	-	Present
Intracranial spread	Normal	Headache, projectile vomiting, confusion	Altered consciousness, Pulsatile Exophthalmos, coma

Table No.5: Ophthalmology

Fundus changes	Points
Normal	0
Cotton wool spots	1
Congested tortuous retinal blood vessels	2
Optic disc oedema	2
Central retinal vein occlusion	2
Central retinal artery occlusion	2
Retinal detachment	2
Choroidal folds	2
Optic disc pallor	2
Total	15

Table No.6: Imaging

Orbital involvement by the disease (globe/muscles/fat)	3
Intracranial spread/superior orbital fissure/inferior orbital fissure involvement	3
Optic neuritis	3
Sphenoid sinus involvement	2
Frontal sinus involvement	1
Ethmoidal sinus involvement	1
Infra-temporal fossa involvement	1
Maxillary sinus involvement	1

If the total score,

>=23 – Orbital Exenteration

<23 – Conservative Management

For Conservative Management, Luna and colleagues studies show that they have treated a patient with rhino-orbital mucormycosis by direct irrigation of amphotericin B into the muscle cone^[13]

CONCLUSION:

Mucormycosis is a severe, emergent and fatal infection requiring multidisciplinary management. Early diagnosis and urgent antifungal treatment associated to surgery with joint care are of extreme importance for successful eradication of infection and for patient survival and decrease residual morbidities. In order to achieve this, screening of patients with high risk factors should be done. Simple tests like vision, pupil, ocular motility and sinus tenderness can be a part of routine physical evaluation in Covid-19 hospitalised patients and home quarantined patients should be made aware of the early symptoms.

REFERENCES:

1. Courtney Y. Kauh et al, Diagnosis and Management of Orbital Mucormycosis, American Academy Of Ophthalmology, June 2014
2. Roden MM et al. *Clin Infect Dis*. 2005;41(5):634-653.
3. Nan Jiang et al, A retrospective analysis of eleven cases of invasive rhino-orbito-cerebral mucormycosis presented with orbital apex syndrome initially, *BMC Ophthalmology*, January 2016; 10
4. Kathleen P. Hartnett et al, A Guide to Investigating Suspected Outbreaks of Mucormycosis in Healthcare, *J Fungi (Basel)*. 2019 Sep; 69
5. Deepak Khanna et al, Sino-orbital mucormycosis in a COVID-19 patient: A case report, *International Journal of Surgery Case Reports*, Volume 82, May 2021
6. Shweta Mallikarjun Revannavar et al, COVID-19 triggering mucormycosis in a susceptible patient: a new phenomenon in the developing world, *BMJ Journal* Volume 14, Issue 4
7. Yohai RA, Bullock JD, Aziz AA, Markert RJ. Survival factors in rhino-orbital-cerebral mucormycosis *Surv Ophthalmol*. 1994;39
8. Johnson TE. Fungal disease of the orbit *Ophthalmol Clin North America*. 2000;13:643-56
9. Downie JA, Francis IC, Arnold JJ, Bott LM, Kos S. Sudden blindness and total ophthalmoplegia in mucormycosis. A clinicopathological correlation *J Clin Neuroophthalmol*. 1993;13:27-34
10. Balch K, Phillips PH, Newman NJ. Painless orbital apex syndrome from mucormycosis *J Neuroophthalmol*. 1997;17:178-82
11. Mukherjee, Bipasha; Raichura, Nirav Dilip; Alam, Md. Shahid, Fungal infections of the orbit, *Indian Journal of Ophthalmology*: May 2016 - Volume 64 - Issue 5 - p 337-345
12. Kshitij Shah, Varun Dave, Renuka Bradoo, Chhaya Shinde and M. Prathibha, Orbital Exenteration in Rhino-Orbito-Cerebral Mucormycosis: A Prospective Analytical Study with Scoring System, *Indian J Otolaryngol Head Neck Surg*. 2019 Jun; 71(2): 259-265
13. Luna JD, Ponssa XS, Rodríguez SD et al. Intraconal amphotericin B for the treatment of rhino-orbital mucormycosis. *Ophthalm Surg Laser* 1994;27:706-8.