



## EPIDEMIOLOGY, CLINICAL PROFILE OF COVID-19-ASSOCIATED RHINO-ORBITAL-CEREBRAL MUCORMYCOSIS IN GDMCH

Dr S.Senthil  
Kumaran\*

MS (ENT), Associate Professor Government Dharmapuri Medical College and Hospital Dharmapuri \*Corresponding Author

**ABSTRACT** **Introduction:** Mucormycosis is a deadly opportunistic fungal infection and a large surge in COVID-19-associated mucormycosis is occurring in India. The second COVID-19 wave in India, triggered by the Delta variant, has been associated with an unprecedented increase in cases of COVID-19 associated Mucormycosis, mainly Rhino-orbito-cerebral mucor mycosis (ROCM). Our aim was to delineate the clinico-epidemiological profile and identify risk factors of rhino orbito cerebral mucormycosis patients presenting to the department of otorhinolaryngology. **Methods:** This was a retrospective, single-centre, observational study. We included patients who presented with clinical features or diagnosed MM and who were previously treated for COVID-19 in last 3 months of presentation or currently being treated for COVID-19. Information regarding clinical features of ROCM, possible risk factors, examination findings, diagnostic including imaging and treatment details were collected. **Results:** In our study 100 ROCM patients with active or recent COVID-19 who presented to the department of ENT in between March 2021 and November 2021, were included. A median duration of 20 days was present between the onset of COVID-19 symptoms and the onset of ROCM symptoms. Most of the patients had at least one risk factor. Most common risk factors were diabetes mellitus and steroid use for COVID-19 disease (70%). **Conclusion:** ROCM is an uncommon, rapidly progressive, angioinvasive, opportunistic fungal infection which is fatal if left untreated. Combination of surgical debridement and antifungal therapy leads to clinical and radiologic improvement in majority of cases.

**KEYWORDS :** Mucor mycosis, COVID

### INTRODUCTION:

Mucormycosis in humans caused by the mucorale group of fungi. These fungi are ubiquitous and present in any environment including hospitals. Inhalation of fungal spores is harmless in immunocompetent individuals but can cause life-threatening disease in those who are immuno-compromised.<sup>1</sup> The immune system is weak in those with uncontrolled diabetes mellitus, prolonged intake of steroids or immunosuppressant medications, malignancies and other debilitating conditions like chronic liver disease and chronic malnutrition state.<sup>2</sup>

By 1st August 2021, there have been more than 300 million infections and 0.4 million deaths due to COVID-19 in India<sup>3</sup>. With COVID-19, the incidence of secondary bacterial or fungal infections is 8%, with aspergillosis and candida being the most common fungi reported<sup>4</sup>. The second COVID wave in India (March 2021 – May 2021), triggered by the Delta variant, has also been associated with an unprecedented increase in the cases of COVID-19 associated Mucormycosis<sup>5</sup>.

Overlapping with the rise in COVID-19 cases, there was a surge of rhino-orbito-cerebral mucormycosis in those with active or recent COVID-19. MM has a high mortality even with the best of treatment. Thus, we designed a retrospective observational study in our department with an objective to document the clinical features, radiological extent and possible risk factors which might be contributing to this illness in the context of the COVID-19 pandemic.

### METHODOLOGY

This was a retrospective, single-centre, observational study. The study was conducted in the Department of ENT at a tertiary care teaching institute of India. Between March 2021 and November 2021, our hospital treated 6418 COVID-19 confirmed admission requiring patients. We observed a surge in mucor mycosis cases in May and June with 100 cases reported upto November. We planned to conduct this study to delineate the clinico-epidemiological profile of ROCM in active or recent COVID-19 patients. Active COVID-19 cases were defined as patients who were laboratory confirmed for SARS-CoV-2 (by RT-PCR). Recent COVID-19 cases were defined as patients who had suffered from COVID-19 in the past 3 months of presentation, but currently SARS-CoV-2 negative. The time limit of 3 months was taken according to commonly accepted definition of post-acute COVID-19 syndrome.<sup>8</sup> ROCM was defined as patients with MM along with acute or recent COVID-19 illness. The ethical approval was obtained from the Institute Ethics Committee before the commencement of the study.

### Data collection

Information was collected, from the hospital records with an emphasis on the demographic profile, date of arrival, date of onset of symptoms, clinical features of ROCM, clinical features, detailed comorbidities

and risk factors, steroid usage details for COVID-19, radiological and microbiological evaluation.

### Statistical analysis

Counts and percentages were used to summarize categorical data. Mean and standard deviation were used to summarize normally distributed data. As this was a descriptive study, no analytical tests were applied on any subgroups. All the analyses were performed with IBM SPSS. Version 26.0

### Results

#### Demographic profile

A total of 100 diagnosed ROCM were included for the analysis. These patients presented to our department. 83 out of 100 patients (83%) were active COVID-19, whereas 17 patients (17%) were with recent COVID-19 infection (COVID-19 negative during presentation). The median age of the included patients was 52.8 years, with an range of 36–82 years, with 70% males. Overall, a lag period was observed between the onset of COVID-19 symptoms and the onset of ROCM symptoms.

Only 1 out of 100 patients (1%) had no comorbidities, immunosuppressant use (including steroids) or recent blood glucose elevation. Majority of patients had underlying diabetes mellitus (n=63), of which five patients were recently diagnosed during their COVID-19 illness. Eight patients (8%) had concomitant diabetic ketoacidosis. Following diabetes, the second most common comorbidity was hypertension (8%). Other comorbidities were present in <10% of population.

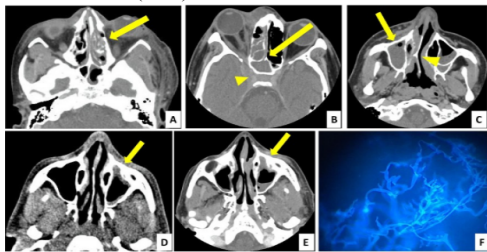
An important risk factor for ROCM was the use of steroids for COVID-19. A total of 79 patients (79%) had received steroids for COVID-19 disease prior to arrival. Fifteen patients (15%) received both inhaled and systemic steroids. Systemic steroids were prescribed for a median duration of 7.5 days in these patients. A notable complication of systemic steroids, i.e. hyperglycemia requiring insulin therapy, was observed 55% of patients receiving systemic steroids. Almost all patients had antibiotics (azithromycin, doxycycline, amoxicillin, piperacillin-tazobactam) in patients with ROCM.

#### Signs and symptoms of MM.

In our study 58 patients out of 100 were on oxygen therapy. Most common symptom reported in ROCM was related to the eye and its adnexal tissues. Sino-nasal symptoms like nasal stuffiness, nasal discharge and epistaxis were present in 38%, 25% and 18% of patients, respectively. Nearly 80% patients had eye pain, swollen eyes and significant lid oedema on examination. Other ophthalmic symptoms were diminution of vision, proptosis, ptosis and double vision. On examination of nasal cavity, crusting and ulceration were present in

25% patients. Another common symptom was facial pain, which was the presenting complaint in 35% patients. Nearly 5% of patients presented with hemiplegia.

23 patients out of 100 patient presented to our department with unstable vital signs and triaged as 'Red' category (highest priority) as per institution protocol. The value of C-reactive protein was available for all 100 patients, 83% of them had values higher than 10 mg/l, indicating severe inflammation due to COVID-19. For definitive diagnosis of ROCM, microbiological samples were taken from the active lesions (with or without nasal endoscopy). Potassium hydroxide (KOH) mount with calcofluor stain was positive for aseptate hyphae in many patients (63%). Radiological diagnostic modalities included contrast-enhanced computed tomography of brain, orbit and paranasal sinuses. Most common radiological diagnosis was rhinosinusitis, followed by orbital extension and intracranial invasion. After clinical, microbiological and radiological workups, final diagnosis was Rhino-orbital (76%) was the most common variety, followed by rhino-orbital-cerebral CAM (24%).



**Figure: Radiological diagnosis of mucor mycosis**

Along with the stabilization of haemodynamic parameters, all the ROCM cases were managed with initiation of systemic antifungals as soon as possible. Intravenous liposomal amphotericin—B or oral posaconazole was initiated. Control of underlying comorbid illness including insulin therapy for hyperglycaemia was initiated for all. Urgent ophthalmology and neurosurgery consultations were taken for shared decision on the surgical debridement pathway.

## DISCUSSION

We conducted a single-centre, retrospective study of 100 patients with mucor. As the number of covid associate mucormycosis cases were increasing in India during the second wave of COVID-19 pandemic, we have tried to delineate the clinico-epidemiological profile of these patients.

Majority of the patients in our study were middle-aged, of which nearly two-thirds were male. This demographic profile was similar to the population of 82 patients studied by Chander et al., of which two-third were male and aged between the ages 31–60 years.

Many experts believe that the combination of high dose steroids and uncontrolled diabetes has led to this epidemic of MM in COVID-19 patients. In the setting of COVID-19, case series by Sharma et al<sup>7</sup>. described diabetes as a risk factor in 90% cases of which 52% had uncontrolled disease. Our study has reflected their findings.

Prolonged use of corticosteroids increasing risk of MM has been reported in patients. Ribes et al. described that acute or chronic use of steroids in such patients predisposed them to fungal infection. Steroid use during the pandemic has been supported by the Randomized Evaluation of COVID-19 Therapy trial, only in those receiving supplemental oxygen therapy and has been endorsed by major international guidelines.

Our study had 79 patients who received steroid therapy. Other comorbid conditions identified include hypertension, coronary artery disease, chronic kidney disease, chronic liver disease, organ transplant recipients and immunosuppression. Airway epithelial damage and immune dysfunctions are known complications of COVID-19, which may provide an opportunity for fungus to invade lung tissues.,

Patterns of MM in patients can differ based on their risk factors, e.g. sinus involvement is common among diabetics. Presence of associated facial erythema, perinasal swelling, nasal ulcers or eschar should serve as early pointers. The red flag signs to look for are cranial nerve palsy, diplopia, periorbital swelling, proptosis, orbital apex syndrome, sinus pain and palatine ulcer.

In the background of COVID-19, Satish et al. reported that 48%

patients in their case series had rhino-orbital disease followed by rhino-orbital-cerebral form. Our study too had most common features related to rhino-orbital followed by rhino-orbital-cerebral type.

Microbiological diagnosis was confirmed by KOH-calcofluor mount showing aseptate hyphae and extent was assessed with contrast-enhanced computed tomography scans as per guidelines. All patients in our study were started on systemic antifungals and majority received liposomal amphotericin B.

## CONCLUSION

Uncontrolled diabetes and unchecked steroid use were major risk factors for the development of ROCM. Other factors like unhygienic oxygen therapy, indiscriminate antibiotic use and COVID-19 itself may have contributed to the ROCM crisis. A large-scale multi-centric prospective study would help gain useful data on this deadly disease.

## REFERENCES

1. Farmakiotis D, Kontoyiannis DP. Mucormycoses. *Infect Dis Clin North Am* 2016; 30:143–63.
2. McNulty JS. Rhinocerebral mucormycosis: predisposing factors. *LARYNGOSCOPE* 1982;92(10 Pt1):1140–3.
3. CDC. Underlying MEDICAL Conditions ASSOCIATED with High Risk for Severe COVID-19: INFORMATION for HEALTHCARE Providers. <https://www.cdc.gov/coronavirus/2019-ncov/hcp/clinical-care/underlyingconditions.html> (2 July 2021, date last accessed).
4. Lancet E. India's COVID-19 emergency. *LANCET* 2021; 397:1683.
5. Kaji AH, Schriger D, Green S. Looking through the retrospective: reducing bias in emergency medicine chart review studies. *Ann Emerg Med* 2014; 64:292–8.
6. Chander J, Kaur M, Singla N, Punia RPS, Singhal SK, Attri AK, et AL. Mucormycosis: battle with the deadly enemy over a five-year period in India. *J Fungi* 2018; 4:46.
7. Sharma S, Grover M, Bhargava S, Samdani S, Kataria T. Post coronavirus disease mucormycosis: a deadly addition to the pandemic spectrum. *J LARYNGOL Otol* 2021; 135:442–7.
8. Ribes JA, Vanover-sams CL, Baker DJ. Zygomycetes in human disease. *Clin Microbiol Rev* 2000; 13:236–301.
9. Satish D, Joy D, Ross A, Balasubramanya. Mucormycosis coinfection associated with global COVID-19: a case series from India. *Int J Otorhinolaryngol Head Neck Surg* 2021; 7: 815–20.