



CLINICAL AND FUNCTIONAL OUTCOME OF PROXIMAL HUMERAL FRACTURE FIXATION WITH RUSHNAIL AND K WIRE FIXATOR VS PHILOS PLATING : A STUDY OF 30 CASES

Dr Shailesh Ramavat	MS Orthopaedics, Professor and Head of the Department, P.D.U. Medical College and Hospital, Rajkot, Gujarat.
Dr. Tarun Parmar*	MS Orthopaedics, Junior resident doctor in Orthopaedics, P.D.U. Medical College and Hospital, Rajkot, Gujarat. *Corresponding Author
Dr. Shalin Patel	MS Orthopaedics, Junior resident doctor in Orthopaedics, P.D.U. Medical College and Hospital, Rajkot, Gujarat.

ABSTRACT **Introduction-** Proximal humerus fractures represent one of the most common fracture type in upper extremity. **Aim-** this study aimed to see clinical and functional outcome of proximal humeral fracture fixation with Rushnail and K-wire fixator vs PHILOS plating. **Material And Method-** A prospective study was conducted over 6 months of a total of 30 patients with proximal humerus fracture. Patients were divided into two groups by randomized controlled trial. Group 1 included 15 patients who were treated with closed reduction and Rushnail with percutaneous k wire fixation. Group 2 included 15 patients who were treated with ORIF with PHILOS plate. All these 30 patients were followed up for mean duration of 6 months. **Results-** Mean neer score at final follow up was 90 in group 1 patients while it was 80 in group 2 patients As per the Neers scoring system. Mean neer score at final follow up was 90 in group 1 patients while it was 82 in group 2 patients. As per the Neers scoring system; 8 patients (54%) in group1 had excellent results, 7 patients(46%) had satisfactory Results. For Group 2 ,as per Neers scoring system 6 patients (40%)had excellent results,7 patients (47%) had satisfactory results,2 patients (13%) had unsatisfactory result with poor outcome. **Conclusion-**In conclusion it was found that Rushnail with K- wires fixation for proximal humerus fractures type II and type III (Neer's) gives superior results than proximal humerus interlocking system (PHILOS).

KEYWORDS : Rushnail and K-wire fixator, Proximal humerus interlocking system Neer's score.

INTRODUCTION

Proximal humerus fractures represent one of the most common fracture type in upper extremity. They constitute about 4-5% of all fractures and represent the most common humerus fracture (45%). Higher incidence is found in elderly with osteoporosis following low energy trauma. Though most of the proximal humerus fracture are non displaced, however Displaced fractures require operative intervention. The choice of treatment is guided by multiple factors such as age of patient, physical activity, fracture pattern. The complex periarticular anatomy, cancellous nature of proximal humerus, deforming Forces of attached muscles make reduction and fixation of fracture quite difficult. The desired result of fixation, among various treatment options can be achieved either by closed reduction by rushnail and percutaneous k-wire fixation or open reduction internal fixation with PHILOS plating. Closed reduction with rushnail and k wire fixation is advantageous in respect with less blood loss, lower risk of neurovascular complication, but prolonged immobilization. Pre contoured Philos plate working on principle of angular stability, 3-dimensional distribution in humeral head has advantages of early mobilisation and less chance of malreduction but extensive surgical exposure and risk of neuromuscular damage, more risk of infection and avascular necrosis of humeral head may however be associated. The aim of this study is to evaluate clinical and functional outcome and compare results of rushnail with k wire fixation and PhiLOS plating in proximal humerus fracture.

MATERIALS AND METHODS

A prospective study was conducted in our institution over six months of a total of 30 patients with proximal humerus fracture. Patients were divided into two groups by randomized controlled trial. Group 1 included 15 patients who were treated with closed reduction and rushnail with percutaneous k wire fixation. Group 2 included 15 patients who were treated with ORIF with PHILOS plate. All these 30 patients were followed up for mean duration of 6 months.

Inclusion Criteria

1. Displaced proximal humerus fracture with >45% angulation and > 1cm of separation
2. Male and female with age >20 years
3. Patient operated within 7 day of injury
4. Neer's Type II and III

Exclusion Criteria

1. Skeletally immature patients
2. Patients with open fractures
3. Pathological fracture

4. Patient with any serious medical comorbidity
5. Neer's Type IV
6. Proximal Humerus Fracture dislocation

Pre-operative AP, lateral X-rays were reviewed to define fracture type. CT scan was done in some of the cases. Fracture of proximal humerus were classified according to NEER classification.

Operative Technique For Each Group Was As Follows Group 1

Surgery was performed under general anaesthesia with the patient in simple table supine position. Near anatomical reduction was achieved by manual traction and arm mobilization.

We use Rushnail for maintaining axial length and reduction followed by three to four 2.5 mm k- wire inserted under image intensifier depending on the number of fracture fragments followed by fixator was placed to maintain reduction and control migration of pins.

Care was taken on the pin placement to avoid injury to the axillary nerve, the radial nerve and the anterior circumflex humeral vessels lying medially. K-wires were left out of skin and fixator was placed using clamps and rods to control migration. Patients were encouraged to start active mobilisation of wrist and elbow on the second postoperative day. Dressing of the pin tracts were done.

Follow up was taken at one week, then every week for 4 weeks, and then at 3 months and 6 months for final evaluation. K-wire fixator was removed at the end of 4-6 weeks and Active shoulder mobilization exercises were started 4 to 6 weeks postoperatively depending on the patient's co-operation.

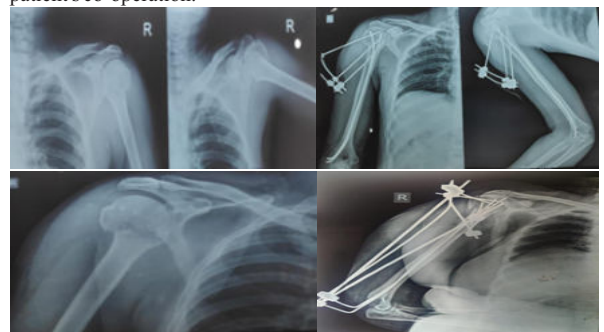


Image 1 : Preop and postop Image of proximal humerus Rushnail with

k-wire Fixator

Group 2

Patients with proximal humerus fractures were treated with open reduction and internal fixation (ORIF) with PHILOS plate. Surgery was performed under general anaesthesia, patient in supine position with a small sand bag under the shoulder. All patients received prophylactic dose of intravenous antibiotic preoperatively. The fracture was exposed through a deltoid pectoral approach and fracture fragments were reduced. The reduced fracture fragments were held in position with K-wires under guidance of image intensifier. Definitive fixation with PHILOS plate was done with the plate positioned lateral to the bicipital groove, sparing the tendon of long head of biceps.

The required lengths of the locking screws were determined and at least six locking screws were inserted in the humeral head. Range of motion of shoulder and impingement were checked on the table. Wound was closed in layers with suction drain. Passive range of motion (ROM) exercises were initiated on the second postoperative day. Sutures were removed after 12-15 days. Active shoulder mobilization exercises were started 4 to 6 weeks postoperatively depending on the patient's co-operation. Follow up was at one week, then every weeks for 4 weeks, and then at 3 months and 6 months for final evaluation.

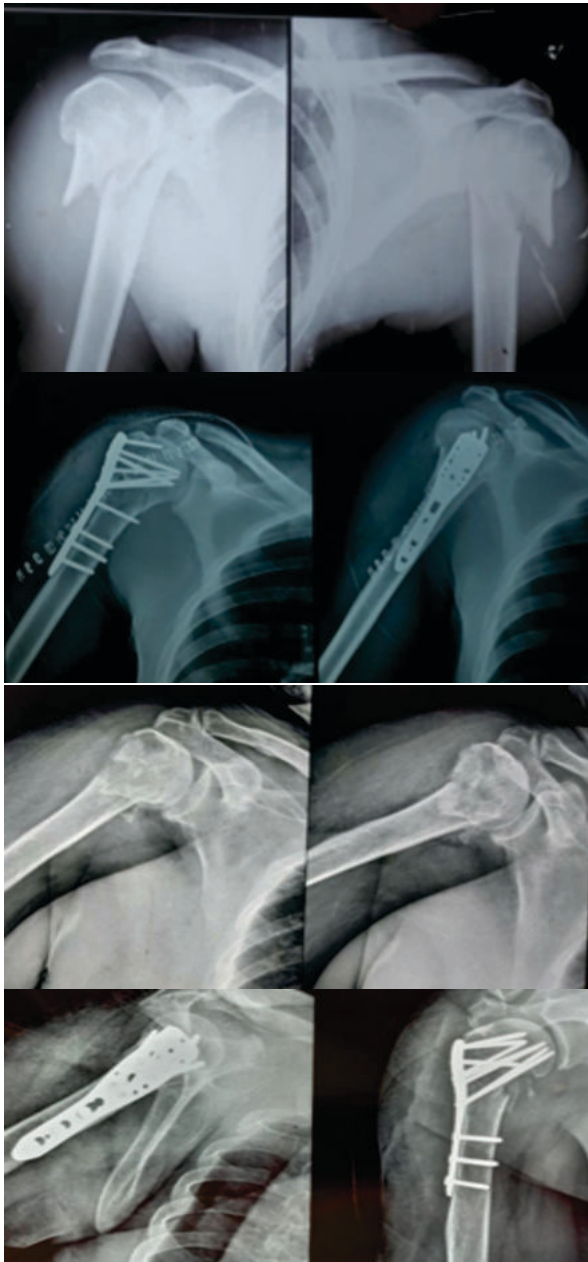


Image 2: Preop and postop Image of proximal humerus fracture

operated with PHILOS Plate

Standard anteroposterior, axillary and lateral radiographs were obtained and evaluated for fracture healing, non-union, malunion, loosening of implant, loss of reduction and avascular necrosis of head of humerus. Clinical examination included pin site infection, loosening of pin, range of motion and strength evaluation, pain assessment according to NEER score. The criteria for radiographic healing was when all fragments showed substantial cortical continuity.

RESULTS

Mean operation time was 60 minutes in group 1 (range 40-80Minutes) and 120 minutes in group 2 (100 -140 minutes). In group 1, the average blood loss during surgery was 80 ml (range 60-120 ml), whereas in group 2 it was 600 ml (range 400- 900ml). Both groups received broad spectrum antibiotics.

The average age of the patient was 50+/-6 in both the groups.

Group 1 had 8 males (54%) and 7 females (46%) whereas Group 2 had 7 males (46%) and 8 females (54%). Over- all 18 patients (60%) had history of road side accident while 12 patients had history of fall, following which were diagnosed by fracture proximal humerus. All fractures were classified as per the Neer classification which came out with overall 14 cases of 2-part (47%), 16 cases of 3 -part (53%) fracture.

Postoperatively no major complication was encountered intra-operatively. One female patient had tachycardia due to excessive blood loss, which was managed with blood transfusion. Post op complications were noted in 6 patients in group 1 and 8 patients in group 2. In group 1, 2 patients had pin tract infection, 2 patients had pin migration, 2 patients had malunion (2 patients with 3 part fracture). Patients with pin tract infection were treated with daily dressing and antibiotics. K wire removal was done in one patient. The range of movements was acceptable in patients in whom malunion had occurred, so no further intervention was done. The patient with k wire loosening had their k wire removed and new wires inserted. In group 2, 2 patients (with 3 part fracture) had nonunion, 4 patients had infection and 2 patients had avascular necrosis of humeral head. For patients with nonunion, bone grafting was done. Patients with infection were treated with antibiotics after obtaining culture sensitivity report. Mean time for radiology union in group 1 was 16 weeks while it was 14 weeks in group 2 patients. Mean neer score at final follow up was 90 in group 1 patients while it was 82 in group 2 patients. As per the Neers scoring system; 8 patients (54%) in group 1 had excellent results, 7 patients (46%) had satisfactory Results. For Group 2, as per Neers scoring system 6 patients (40%) had excellent results, 7 patients (47%) had satisfactory results, 2 patients (13%) had unsatisfactory result with poor outcome.




Image 3: Functional outcome GROUP 1



Image 4-Functional outcome GROUP 2

DISCUSSION

Proximal humerus fractures when undisplaced can be treated conservatively but when they are displaced fractures, require surgical treatment for better outcomes as they are one of the most difficult fractures to treat. These are common both with high energy trauma as well as simple fall in elderly patients with osteoporosis making these fractures difficult to manage conservatively because of their anatomical location. Although fracture union has never been a problem in proximal humeral fracture as had been mentioned in many studies due to cancellous nature of bone unless anatomical neck or articular of humerus is involved, compromising bone of its blood supply. Surgical procedures like rushnail with percutaneous K-wires has the advantage of less soft tissue damage, less blood loss but do not ensure anatomical reduction and has limitations such as delayed mobilization and longer period of recovery whereas pre-contoured PHILOS plate has revolutionized the treatment of proximal humerus fracture with better results in respect with higher rate of union, especially in osteoporotic bone, more stable anatomical reduction which is of great importance in any surgery, with ease of reconstruction of comminuted irreducible fractures. It has disadvantage of excessive soft tissue dissection and blood loss, risk of injury to neurovascular structure and increased risk of avascular necrosis of humeral head, higher risk of infection. However long term results of proximal humerus fractures managed by PHILOS plate are lower as compared with rushnail K-wire fixator. higher Neer's score with better ROM was observed in patients of Group A as compared to Group B operated type II, type III

Fixation with percutaneous k wire may present an effective treatment for 2 or 3 part fractures with advantage of minimal invasiveness. Better functional results were seen in patients treated with rushnail and percutaneous k-wire fixation than those treated with PHILOS plate.

Mean Neer's score for ROM was significantly more in patients treated with rushnail and percutaneous k-wire fixation.

In the present study it was concluded that though PHILOS plate provide stable fixation and anatomical reduction but there is more chance of infection, avascular necrosis of head of humerus, rotator cuff injuries and extensive soft tissue damage. In case of closed reduction by rushnail with k-wire fixator shows better functional outcome despite of delayed mobilization and there is less risk of neurovascular damage, blood loss and infection and less intra-operative time.

CONCLUSION

Although Radiological results are slightly better with PHILOS than

rushnail with k-wire fixator but functional outcomes are better with rushnail and k-wire fixation.

As other Medical commorbidities accompany elderly patient and are fitness for anesthesia fitness is sometimes in questioned, rushnail and k-wire fixation is preferred.

In conclusion it was found that rushnail with K-wires fixation for proximal humerus fractures type II and type III (Neer's) gives superior results than proximal humerus interlocking system (PHILOS).

REFERENCES

- 1) Chu SP, Kelsey JL, Keegan TH, Sternfeld B, Prill M, Quesenberry CP. Risk factors for proximal humerus fracture. *Am J Epidemiol.* 2004;160:360-367.
- 2) Magovern B, Ramsey ML. Percutaneous Fixation of Proximal Humerus Fractures. *Orthopedic Clinics of North America.* 2008;39(4):405-416. Available from: <https://dx.doi.org/10.1016/j.ocl.2008.05.005>.
- 3) Magovern B, Ramsey ML. Percutaneous Fixation of Proximal Humerus Fractures. *Orthopedic Clinics of North America.* 2008;39(4):405-416. Available from: <https://dx.doi.org/10.1016/j.ocl.2008.05.005>.
- 4) Neer CS, Nd. Displaced proximal humeral fractures. I. Classification and evaluation. *J Bone Joint Surg Am.* 1970;52:1077-89.
- 5) Millet PJ, Warner JJ. Percutaneous treatment of proximal humerus fractures. *Am Acad Orthop Surg.* 2005;p. 15-26.
- 6) Rowles DJ, McGrory JE. Percutaneous Pinning of the Proximal Part of the Humerus. *The Journal of Bone and Joint Surgery-American Volume.* 2001;83(11):1695-1699. Available from: <https://dx.doi.org/10.2106/00004623-200111000-00012>. doi:10.2106/00004623-20011100000012.
- 7) Andrew H, Crenshaw JR. Surgical techniques and approaches. *Operative Orthopedics Ch I Elsevier Mosby.* 2013;12:100-104.
- 8) Hoppenfield S, Deboer P, Buckley R. The Shoulder. *Surgical Exposures in Orthopedics. The Anatomic Approach Ch 1 Lippincott, Williams & Wilkins: Wolterskluwer.* 2009;4:4-17.
- 9) Chowdary U, Prasad H, Subramanyam PK. Outcome of Lock-ing Compression Plating for Proximal Humeral Fractures: A Prospective Study. *Journal of Orthopaedic Surgery.* 2014;22(1):4-8. Available from: <https://dx.doi.org/10.1177/230949901402200104>. doi:10.1177/230949901402200104.
- 10) Herscovici D, Saunders DT, Johnson MP, Sanders R, DiPasquale T. Percutaneous Fixation of Proximal Humeral Fractures. *Clinical Orthopaedics and Related Research.* 2000;375:97-104. Available from: <https://dx.doi.org/10.1097/00003086-200006000-00012>. doi:10.1097/00003086-200006000-00012.
- 11) Daljit S, Mohd Y, Ashwini S. Three and four part fractures of proximal humerus - Is percutaneous K-wire fixation a good option. *J Orthop.* 2010;7:11-11.
- 12) Carulli C, Nistri L, Innocenti M, Muncibi F, Paez D, Matassi F. Long term results of percutaneous fixation of proximal humerus fractures. *Indian Journal of Orthopaedics.* 2012;46(6):664-664. Available from: <https://dx.doi.org/10.4103/0019-5413.104203>. doi:10.4103/00195413.104203.