Case Report

Volume - 12 | Issue - 09 | September - 2022 | PRINT ISSN No. 2249 - 555X | DOI : 10.36106/ijar

Periodontology

AMLODIPINE: A DIHYDROPYRIDINE INDUCED GINGIVAL OVERGROWTH- A CASE REPORT WITH ONE YEAR FOLLOW UP

Dr Aysha Jebin A* Post graduate student, Department of Periodontics, Vydehi institute of dental sciences and research centre, Whitefield, Bangalore, Karnataka, India *Corresponding Author

Dr Sanjeela Guru Reader, Department of Periodontics, Vydehi institute of dental sciences and research centre, Whitefield, Bangalore, Karnataka, India

ABSTRACT **Background:** Etiopathogenesis of drug induced ginigival overgrowth has been attributed mainly to three classess of drugs including Calcium channel blockers, Anticonvulsants, and Immunosuppressants eventhough newer drugs been expanded to the record. Amlodipine, a calcium channel blocker, a dihydropyridine derivative, most routinely recommended antihypertensive drug, with very little incidence of gingival hyperplasia. **Case report:** Here we descibed a case report of gingival overgrowth induced by amlodipine drug in a 40 year old male patient along with the etiological hypothesis proposed for the same. **Conclusion:** It can be treated by conventional periodontal therapy, but surgical intervention needed in severe cases of gingival overgrowth.

KEYWORDS : Amlodipine; Gingival Overgrowth; Calcium Channel Blockers; Antihypertensive Agents; Dihydropyridines

INTRODUCTION

There are so many medication which are used for non dental/ non oral conditions that causes gingival overgrowth as their side effect[1] One group of drugs among them calcium channel blockers.1 Initially, the terminology gingival hypertrophy and gingival hyperplasia were used to describe gingival enlargement, later these terms were discarded as it describes histologic aspects rather than clinical diagnosis.[2]

Gingival overgrowth caused by a dihydropyridine dervative, Amlodipine, ,used in the management of hypertension was reported first in 1994 by Seymour et al.[1] The hastened growth of gingiva in patients with medication of 10 mg per day of amlodipine within two months of consumption was reprted by Lafzi et al In 2006.[3]

Risk factors ascribed for gingiva overgrowth includes poor oral hygiene maintenance, genetic predisposition, drug metabolites interaction with gingival fibroblast, age factor and gender predilection.[4] Nifidipine, a calcium channel blocker, which is one of the drug frequently reported with adverse effect of gingival overgrowth.[5] Amlodipine has similar pharmacological actions as Nifidipine. Its a drug with mechanism of action of coronary artery and pheripheral arterial vasodilation, given either as monotherapy or combined with atenolol, in single/dual dosage of 2.5 to 5 mg, which is a long acting one.[5] Other reported undesirable effects of this drug are headache, dizziness, facial flushing, oedema etc. In patients exhibiting gingival overgrowth with detectable levels of drug in gingival crevicular fluid, there is distinct levels of drug sequestration .[6]

Literature on amlodipine induced gingival enlargement is sparse. So here, we depict a case presentation of gingival enlargement in a hypertensive patient under low dose amlodipine medication since past seven months.

CASE REPORT

A 40 year old male patient reported to the institute's department of periodontics with a chief complaint of swollen and bleeding gums with upper and lower front tooth region since last 3 to 4 months.On intraoral examination, both the anterior maxillary and mandibular arches were with soft tissue overgrowth interdentally and marginally which were nodular with spontaneous bleeding [Fig-1]. Gingival Surface appears lobulated with loss of scalloping.

Medical and drug history revealed that the patient was diagnosed with hypertension 7 months back and was prescribed with amlodipine 5 mg once daily during night and was on same medication since last 7 months.The patient was moderately built with no signs of anaemia and jaundice. His vital signs were within the normal range.Routine blood investigation values were in normal range which includes bleeding time and clotting time. Intraoral periapical radiograph(IOPA) showed crestal bone loss with upper and lower anteriors. Based on patients medical & drug history, clinical oral examination and radiographic interpretation a provisional diagnosis of amlodipine induced gingival overgrowth overlapped with inflammation was given.

Histopathological Findings

After initial examination, incisional biopsy was done. Histopathological investigation unveiled some areas of hyperplastic orthokeratinized and parakeratinised stratified squamous epithelium and connective tissue exhibiting mixture of loose dense fibrous area. Inflammatory component with neutrophils and dilated blood capillaries with few areas of calcifications were evident.

Medical And Dental Management

Depending on history, clinical examination, and routine investigations, final diagnosis of combined gingival overgrowth was established. Treatment plan of scaling and root planning with drug substitution with the patient's physician consent were performed. Patient was put on tablet Telma R 5 mg once daily. Patient was examined after a time period of 2 months during which he was asked to rinse with 10 ml of 0.2% chlorhexidine mouthwash twice daily to maintain proper oral hygiene. There was a substantial improvement in the clinical picture of maxillary anterior gingiva compared mandibular anteriors.

External bevel gingivectomy was performed under local anaesthesia with respect to mandibular anterior sextant [Fig-2A, 2B] to remove the fibrous tissue followed by placement of periodontal dressing. He was also prescribed anti-inflammatory analgesic drug for management of postoperative pain for five days. Patient was recalled after one week for evaluation, were the tissue was showing regression in size with proper healing. Patient was asked for oral hygiene maintenance using 0.2% chlorhexidine mouthrinse and interdental aids. On assessment after 1 year [Fig-3], the gingival enlargement had subsided almost completely.

DISCUSSION

Recently , more drugs have been identified as possible causative agents for gingival overgrowth, including oral contraceptives.[8] But, gingival overgrowth is well recognized undesirable side effect associated with three major classes of drugs viz, anticonvulsants, immunosuppressants and calcium channel blockers[1] Although the pharmacological actions of these drugs is different and directed towards different target tissues, all of them appear to act alike on the secondary target tissue, which is gingiva.[1,2]

Seymour et al. In his review on the pathophysiology of drug-induced gingival overgrowth (DIGO) considered it as a multifactorial paradigm, which involves an interaction between different factors, along with the interaction between drug metabolite and gingival fibroblasts.[1] Different predisposing factors for DIGO includes age, genetic predisposition, pharmacological variables, drug-induced changes in gingival connective tissue homeostasis and growth factors, histopathological factors, ultrastructural factors and inflammatory changes.[9]

The intrinsic mechanism behind DIGO includes inflammatory and noninflammatory pathways.[10] The suggested noninflammatory mechanisms are defective collagenase activity due to decreased uptake of folic acid, aldosterone synthesis blockage in adrenal cortex and

subsequent feedback increase in adrenocorticotropic hormones in blood and upregulation of receptors for keratinocyte growth factor. Inflammatory changes may develop as an outcome of direct toxic effects of concentrated drug metabolite in gingival crevicular fluid and dental plaque.[2,10] This inflammatory changes generate the upregulation of various cytokines such as transforming growth factor-1.[10]

Amlodipine, the drug that cause gingival hyperplasia is a second-generation dihydropyridine calcium channel blocker with a prevalence rate between 1.7% and 3.3%.[11] The prevalence with the use of calcium channel blockers comes up to 38% and higher prevalence rate of 3.3 times in men compared to women.[11] The incidence rate of gingival enlargement with amlodipine was described to be less than nifedepine. Gingival overgrowth, despite of its etiology, may be troublesome and contribute to an increased risk for other oral and periodontal diseases.[12] It also causes changes in aesthetics along with symptoms including speech impediment, tendernes, pain, bleeding, ,abnormal tooth movement, and occlussal disturbances etc.[12] The gingival architecture changes seen in DIGO will be amplified by plaque leading to inflammatory changes like edematous and hyperemic gingiva.[12, 13] This hampers the plaque control in these patients maintaining the cycle.

The ultimate goal of conventional periodontal therapy is to control the inflammation in gingiva & thereby avoiding the requirement of surgical part and it also allows for a blood less field during surgical intervention.[14] Corresponding to present case scenario, asking medical physician consent and consultation for drug substitution (Amlodipine) is unavoidable, but the dentist should acknowledge that these drugs are being given for systemic condition which are difficult to control in other ways and may present threats to patient's well being, so it should be given up on physician's evaluation and judgement, either to withdraw/substitute the drug or not. A periodontal supportive therapy for 3-months interval has been generally recommended for patients consuming drugs related with gingival hyperplasia.[1 2] In this case scaling and root planing followed by adequate oral hygiene maintenance programme helped to reduce gingival inflammation. In addition patient was continued on chlorhexidine mouthrinse for oral hygiene maintenance for 3 months .

Different studies have showed that amlodipine induced gingival overgrowth can occur at dose of 10 mg/day or higher.[6,11,14] The depicted case is a discrete one, because even a 5 mg/day dosage of amlodipine can cause gingival enlargement after 7 months usage. Treatment consists of withdrawal and substitution of that particular drug with the patient's physician consent and providing folic acid and vitamin c supplements.[13] Improvement in the size of the gingival overgrowth has been reported even within a week of drug substitution and can lead to complete resolution in few cases. Patients are also gained from successful oral hygiene practices including scaling and root planing.[10] Importance of oral hygiene maintenance in minimizing complications should be explained to the patients at regular intervals. Routine dental evaluation is necessary to control the bacterial plaque which is a major predisposing factor for DIGO.[10]

If gingival condition persevere even after careful consideration of non surgical approaches, surgical intervention, either by gingivectomy or flap surgery is indicated. In this case patient was subjected to drug substitution along with sessions of scaling and root planning. On examination after the period of 3 months, there was complete regression of lesion in maxillary anteriors compared mandibular, hence surgery was indicated in mandibular anterior gingiva only.

CONCLUSION

Amlodipine can induce gingival overgrowth even at a singlel dose (5 mg). Dentists should be vigilant regarding the medications that can cause gingival overgrowth and should identify changes in the oral cavity in these patients for diagnosis, and successful treatment of the same. Treatment of DIGO can be done by a dental professional either conservatively and/or systemically with the help of a medical practitioner. Hence the team of the patient, his consulting medical professional, the dental professional and their integrated efforts are compulsory for the successful treatment of such undesirable side effects of drugs.

The basic treatment includes drug withdrawal/ replacement, oral hygiene maintenance decreasing the inflammatory components like plaque and calculus accumulation. In severe cases which may not resolve even after decreasing the dose or substitution of the causative drug, surgical therapy is indicated . The relevance of maintaining oral hygiene in preventing and managing these drug side effects should not be under estimated as this is probably the best feasible and economic solution.

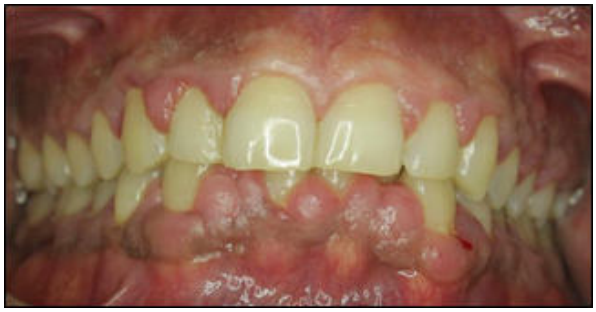

Figure:1 Pre-operative clinical image

Figure 2A External bevel gingivectomy

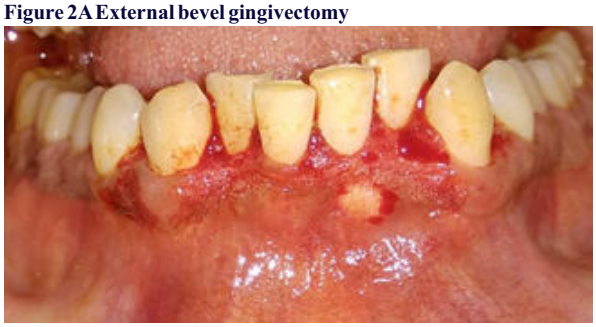

Figure 2B Immediate post operative image

Figure:3 1 year post operative image

REFERENCES

1. Seymour RA, Thomason JM, Ellis JS. The pathogenesis of drug induced gingival overgrowth. J Clin Periodontol. 1996; 23:165-75.
2. American Academy of Periodontology. Informational paper: drug associated gingival enlargement. J Periodontol. 2004; 75:1424-31.
3. Lafzi A, Farahani RM, Shoja MA. Amlodipine induced gingival hyperplasia. Med Oral Patol Oral Cir Bucal 2006; 11: 480–2.
4. Ellis JS, Seymour RA, Steele JG, Roberston P, Butler TJ, Thomason JM. Prevalence of gingival overgrowth induced by calcium channel blockers: a community based study. J Periodontol 1999; 70: 63–7
5. Jorgensen MG. Prevalence of amlodipine-related gingival hyperplasia. J Periodontol. 1997;68:676-78
6. Triveni MG, Rudrakshi C, Mehta DS. Amlodipine induced gingival overgrowth. J Indian Soc Periodontol 2009; 13: 160–3.
7. Marshall RI, Bartold PM. A clinical review of drug induced gingival overgrowth. Aust Dent J 1999;44:219-232.

8. Brown RS, Beaver WT, Bottomley WK. On the mechanism of drug-induced gingival hyperplasia. J Oral Pathol Med 1991;20:201-209.
9. Hallmon WW, Rossmann JA. The role of drugs in the pathogenesis of gingival overgrowth. A collective review of current concepts. Periodontol 2000 1999;21:176 -196.
10. Hall EE. Prevention and treatment considerations in patients with drug-induced gingival enlargement. Curr Opin Periodontol 1997;4:59-63.
11. Jose J, Santhosh YL, Naveen MR, Kumar V. Case report of amlodipine induced gingival hyperplasia – late onset at a low dose. Asian J Pharm Clin Res 2011; 4: 65–6.
12. Prisant LM, Herman W. Calcium channel blocker induced gingival overgrowth. J Clin Hypertens 2002; 4: 310–1.
13. Taib H, Ali TBT, Kamin S. Amlodipine induced gingival overgrowth: a case report. Arch Orofac Sci 2007; 2: 61–4.
14. Sharma S, Sharma A. Amlodipine induced gingival enlargement – a clinical report. Compend Contin Educ Dent 2012; 33: 78–82.