



## A COMPARATIVE STUDY BETWEEN OPEN AND LAPAROSCOPIC REPAIR OF INGUINAL HERNIA

**Dr.B.Sneha Sree Lakshmi\***

Post Graduate, \*Corresponding Author

**Dr. P. Naresh Kumar**

Professor

### ABSTRACT

**Background:** Hernias of the abdominal wall constitute an important public health problem. Laparoscopic inguinal hernia repair (TEP) is a minimal access surgical procedure as compared to open hernia repair. The objective of the study was to compare open and laparoscopic hernia repair in terms of safety, complications, morbidity, recurrence, post-op pain and hospital stay. **Material and Methods:** This was a prospective observational comparative study. Total 50 patients were taken in this study; out of them 25 patients subjected to group A (open repair of inguinal hernia) and 25 patients subjected to group B (laparoscopic repair of inguinal hernia). Postoperatively patients were observed for any complications and followed up one year. **Results:** Present study shows Mean operative time for open hernia repair group was less than laparoscopic hernia repair group. Time to return to normal work, duration of hospital stay and postoperative pain were less in laparoscopic hernia repair group than open hernia repair group. Out of 25 patients in laparoscopic hernia repair (TEP) 1 patient had recurrence but in open hernia repair group there was no recurrence. **Conclusion:** Laparoscopic hernia repair is quite safe; it has definite advantages in bilateral and recurrent cases, postoperative pain, early return to normal activities, less postoperative hospital stay and better cosmetic results although it has its own disadvantages in terms of recurrence rate, operative time and cost effectiveness.

**KEYWORDS :** Laparoscopic hernia repair, Open hernia repair, cost effectiveness

### INTRODUCTION:

Inguinal hernia affects both men and women but it is much more common in men who constitute over 90% of operated patients. Considering both operated and non-operated inguinal hernias, the lifetime prevalence rate is 47% for men. The lifetime risk of undergoing such a repair is 27% for men and 3% for women. High incidence of the disease makes inguinal hernia repair the most frequent procedure in general surgery, accounting for 10-15% of all operations. Laparoscopic inguinal hernia repair is a minimal access surgical procedure. Laparoscopic repair is usually undertaken by two methods one is TAPP other one is TEP repair, the main variation between these two techniques is the sequence of gaining access to peritoneal space. In TAPP the surgeon goes into the peritoneal cavity and places a mesh through a peritoneal incision over possible hernia sites. TEP is different from TAPP as the peritoneal cavity is not entered and mesh is used to seal the hernia site from outside the thin membrane covering the organs in the abdomen (the peritoneum).

### AIMS AND OBJECTIVES:

The objective of the study was to compare open and laparoscopic inguinal hernia repair in terms of safety, complications, morbidity, recurrence, post-op pain and hospital stay.

### METHODS:

This prospective observational comparative study was conducted in the Department of General surgery in Government General Hospital affiliated with Rangaraya Medical college, Kakinada during the period of September 2020 to August 2021. Out of 50 patients, 25 patients subjected to group A (open Lichtenstein repair of hernia) which was a control group and 25 patients subjected to group B (laparoscopic TEP repair of hernia) which was a study group (Table 1). In Group A, out of 25 patients 20 unilateral hernia and 5 bilateral hernia repaired with open Lichtenstein approach and in Group B, out of 25 patients 20 unilateral hernia and 5 bilateral hernia repaired with laparoscopic TEP approach (Table 1). Postoperatively patients were observed for any complications and were followed up in OPD after discharge. Thorough examination was done on follow-up for 3 months to detect any complication. Visual analogue scale was used for assessment of severity of pain.

### Inclusion criteria:

Patients admitted in Government General Hospital, Kakinada diagnosed with inguinal hernia and undergoing open Lichtenstein repair and laparoscopic TEP repair as an elective surgery.

### Exclusion criteria:

Emergency surgery for complicated hernias; all recurrent hernias.

### Procedure

**Anaesthesia:** In group A (control group), 25 patients were operated under spinal anaesthesia and in group B (study group) 25 patients were operated under general anaesthesia.

**Preoperative preparation:** All the patients in group B (study group) those operated under laparoscopic TEP hernia repair were catheterised prior to surgery.

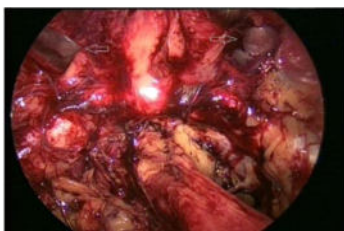
### Steps of surgery for open hernia repair

IV antibiotic (1 gram ceftriaxone) was given to all patients before incision, draping done. An inguinal incision was used in all cases, which extend from the mid inguinal point to the ipsilateral pubic tubercle above the inguinal ligament and one finger breadth below the internal inguinal ring. Dissection was continued through the subcutaneous tissues and Scarpa's fascia. The external oblique fascia and the external inguinal ring were identified. The external oblique fascia and aponeurosis were incised through the superficial inguinal ring to expose the inguinal canal. The space created between external oblique aponeurosis and internal oblique muscle. The genital branch of the genitofemoral nerve, ilioinguinal and iliohypogastric nerves, were identified and mobilized to prevent transection and entrapment. The spermatic cord was mobilized at the pubic tubercle by a combination of blunt and sharp dissection. The cremasteric muscle was separated parallel to its fibers from the underlying cord structures. In case of indirect hernia; the sac was separated from adjacent cord structures and dissected to the level of the internal inguinal ring. The sac was opened and examined for visceral contents. The sac was twisted and transfixed at the base with catgut 2-0. Remaining sac was incised and displaced into the peritoneal cavity. In case of direct hernia; sac protruded from floor of inguinal canal, sac didn't open and replace into peritoneal cavity. In our study, polypropylene mesh placed in the space below the external oblique aponeurosis and internal oblique muscle. Mesh was fixed with prolene 2-0 RB with inguinal ligament inferiorly, superiorly and posteriorly with the internal oblique muscle. External oblique aponeurosis was sutured with vicryl 2-0 RB and wound was closed in layers. Skin is sutured with ethilon 2-0 RC.

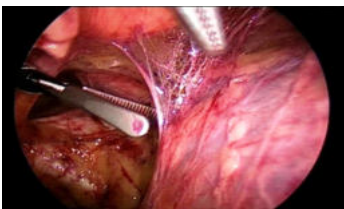
### Steps of surgery for laparoscopic (TEP) inguinal hernia repair

IV antibiotic (1 gram ceftriaxone) was given to all patients before incision, draping was done. A 10mm infraumbilical incision is made. The anterior rectus sheath was exposed and transverse incision was made on anterior rectus sheath to one side of midline to avoid opening of the peritoneum. The margins of the incised sheath are held in stay sutures by using vicryl 11-0 RB. The ipsilateral rectus abdominis muscle was retracted laterally,


and blunt dissection was used to create a space beneath the rectus. A dissecting balloon is inserted deep to the posterior rectus sheath in the preperitoneal space advanced to the pubic symphysis, and inflated under direct laparoscopic vision. A 10 mm Hassan's canula introduced in the preperitoneal space through infraumbilical incision. A 10 mm 30 degree telescope used. The camera is introduced through the sub umbilical port and preperitoneal space is visualized. Other two ports are placed in the preperitoneal space. First, a 5 mm port was placed about 2-3 cm above the pubic symphysis in the midline and second, 5 mm port was placed in the midline midway between the two ports (subumbilical and suprapubic). The inferior epigastric vessels were identified in the lower portion of the rectus muscle which was a useful landmark. Cooper ligament cleared from the pubic symphysis medially to the level of the external iliac vein. Dissection in extraperitoneal space done by dividing the loose areolar tissue in the midline using sharp and blunt dissection.



**Figure 1: Laparoscopic posterior extra peritoneal space with bilateral direct hernia defect**



**Figure 2: Laparoscopic extra peritoneal dissection**



**Figure 3: Endoscopic image showing unfolded polypropylene mesh.**

The first landmark/reference point e.g. the pubic bone is identified which appears as white glistening structure in the midline. In laparoscopic posterior view bilateral direct hernia defect was identified (Figure 1). In case of a direct hernia; sac was gently reduced by traction. A small indirect hernia sac was mobilized from the cord structures and after gentle dissection it was reduced into the peritoneal cavity (Figure 2). After reduction of hernia 15x10 cm unfolded polypropylene mesh inserted through a trocar (Figure 3). After spreading, it covers the direct and indirect hernial sites (Figure 4). The mesh was carefully secured with a tacking stapler to Cooper's ligament from the pubic tubercle to the external iliac vein, anteriorly to the posterior rectus musculature and transversus abdominis aponeurotic arch at least 2 cm above the hernia defect, and laterally to the iliopubic tract. The mesh extended beyond the pubic symphysis and below the spermatic cord and peritoneum. Port had been removed and wound closer was done. After operation in both groups patients were carefully monitored postoperatively. On day 1, in the evening Foley's catheter removed in the patients who had undergone TEP repair. 1 gm ceftriaxone continued till the patient discharge. The analgesic used was diclofenac sodium 40 mg tablet 12 hourly and pain was recorded on visual analogue score. Patients monitored for postoperative pain as per VAS on consecutive postoperative days. The patients were motivated to move in the early postoperative period and to take liquid diet on the evening of day of surgery. Sutures were removed between 7-10 days. Patients were evaluated on day 1, day 5-7, at the time of discharge, day 14, 1 month and 3 months presence of any superficial wound infection,

recurrence, post op pain, seroma formation, swelling, and signs of recurrence. Patients who have recurrence kept under close observation. The scars were checked at each follow-up and compared between the two groups during and after surgeries.

**RESULTS:**

- Group A-open Lichtenstein repair of hernia (control group).
- Group B-laparoscopic TEP repair of hernia (study group).

Data obtained was tabulated and expressed as statistics and percentages. Comparison was done during T test. A probability value of (p value) of less than 0.05 was considered as statistically significant. Following observations were noted and results were drawn. The distribution of hernias based on side was compared between the two groups. The number of bilateral hernias was found to be more in TEP group (Table 1).

**Table 1: Site of hernia among the study groups**

SITE	GROUP A	GROUP B	TOTAL N (%)
RIGHT	10	10	20 (40%)
LEFT	10	10	20 (40%)
BILATERAL	5	5	10(20%)
TOTAL	25	25	50(100%)

**Table 2: Post-operative pain visual analogue score of patients operated by Lichtenstein (open) method and laparoscopic method.**

VAS SCORE	GROUP A N (%)	GROUP B N(%)
1-2	7 (28)	19(76)
3-4	14(56)	5(20)
5-6	4(16)	1(4)
7-8	0	0
9-10	0	0
TOTAL	25(100)	25(100)

In this study, there was a marked reduction in postoperative pain in laparoscopic (TEP) hernia repair compared to open inguinal hernioplasty (Table 2).

Present study shows recurrence in 3 patients in laparoscopic (TEP) hernia group but there was no recurrence in open hernia repair group (Lichtenstein's repair) (Table 3)

POSTOPERATIVE COMPLICATIONS	GROUP A	GROUP B
Seroma	1	0
Superficial wound infection	5	0
Groin pain	6	5
Recurrence	0	3
Subcutaneous emphysema	0	1
Urinary retention	2	0

**Table 4 : Hospital stay and time to return to normal activities.**

VARIABLE	GROUP A	GROUP B
HOSPITAL STAY	4.5 DAYS	2.5 DAYS
TIME TO RETURN TO WORK	7 DAYS	5 DAYS

**Table 5: Mean operative time**

GROUP A	GROUP B
76.72 mins	106.96 mins

**DISCUSSION:**

In present study, postoperative pain is higher in open repair of inguinal hernia (Lichtenstein) than laparoscopic repair (TEP) which is compatible with other study like Prasad. There is a significant reduction in the duration of postoperative pain (in days) following a TEP repair than a Lichtenstein's repair (p<0.00001). In study of Jaykar, postoperative pain was higher in Lichtenstein's meshplasty group than Laparoscopic hernia repair group. Also there were no incidence of orchitis in postoperative period of both groups.

Incidence of urinary retention is noticed in 2 patients of open hernia repair. In present study, there was no major complication observed in either group like any major vascular injury, visceral injury or bladder perforation.

Superficial wound infection was found to be more in open inguinal hernia repair group than laparoscopic (TEP) hernia repair group (Table 4) which is compatible with study of Rathod, in which the postoperative surgical site infection was found to be very less in case of TEP. In present study recurrence rate in laparoscopic (TEP) hernia repair is 12% but that is 0 in open hernia repair. In present study seroma formation in laparoscopic (TEP) hernia repair is 0 but that is 1 in open hernia repair. This result was compatible with the study of Shah, in which seroma formation was more in open hernia repair than laparoscopic hernia repair.<sup>8</sup>

Present study shows mean operative time for open hernia repair and laparoscopic hernia repair are 76.72 mins and 106.96 mins. Thus the mean taken time to complete a laparoscopic hernia repair was significantly higher ( $p=0.00001$ ) which is also compatible with other studies like Shah, Athmaram, Rathod and Jaykar.<sup>8-1</sup>

Present study shows duration of hospital stay for open hernia repair and laparoscopic hernia repair are 4.5 days and 2.5 days. Thus postoperative hospital stay was significantly lower in laparoscopic hernia repair than open hernia repair ( $p=0.00001$ ) which is compatible with other studies like Athmaram, and Jaykar, Prasad.<sup>7,9,11</sup>

Present study shows time to return to normal work for open hernia repair and laparoscopic hernia repair were 7 days and 5 days. Thus time to return to normal work was significantly lower in laparoscopic hernia repair than open hernia repair ( $p=0.000253$ ) which is compatible with other studies like Athmaram and Prasad.<sup>7,9</sup>

#### CONCLUSION:

In the era of laparoscopic surgery, laparoscopic hernia repair has gained its popularity. Laparoscopic hernia repair is quite safe; it has definite advantages in bilateral and recurrent cases, although it has its own disadvantages in terms of recurrence rate, operative time and cost effectiveness. Postoperative pain, early return to normal activities, less postoperative hospital stay and better cosmetic results are also an important factor, which is seen in laparoscopic repair. Long learning curve for laparoscopic hernia repair is there but in experienced hands the results are comparable between open and laparoscopic repair. Small sample size and study period was short. So, the long term outcome results and recurrences would not be assessed. For that sample size should be large and study period should be long.

#### REFERENCES:

1. LeBlanc K, Kingsnorth A. Hernias: inguinal and incisional. *Lancet*. 2003;362(9395):1561-71.
2. Lichtenstein IL, Shulman AG, Amid PK, Montllor MM. The tension-free hernioplasty. *Am J Surg*. 1989;157(2):188-93.
3. Bruniciardi FC, Andersen DK, Billiar TR, Dunn DL, Hunter JG, Matthews JB, et al. *Schwartz's Principles of Surgery*. 10th Ed. Mc Graw Hill; 2015.
4. Primates P, Golacre MJ. Inguinal hernia repair, incidence of elective and emergency surgery. *Int J Epidemiol*. 1996;25:835-9.
5. Schools IG, Van Dijkman B, Butzelaar RM, Van Geldere D, Simons MP. Inguinal hernia repair in Amsterdam region. *Hernia*. 2001;5(1):37-40.
6. Ahmad G, Duffy JM, Phillips K. Laparoscopic entry techniques. *Cochrane Database Syst Rev*. 2008;(2):CD006583.
7. Prasad K. Comparative evaluation of Lichtenstein tension free hernia repair vs laparoscopic tep repair of inguinal hernia. *Asian Pac J Health Sci*. 2016;3(4):300-5.
8. Shah HA. A Comparative Study between Laparoscopic Hernia Repair and Open Lichtenstein Mesh Repair. *BJMMR*. 2017;21(9):1-8.
9. Athmaram A.A Comparative Study between Laparoscopic Hernia Repair and Open Lichtenstein's Hernia Repair. *Int J Sci Res*. 2015;6:391.
10. Rathod C.A comparative study between laparoscopic inguinal hernia repair and open inguinal hernia repair. *Int Surg J*. 2016;3(4):1861-7.
11. Jaykar RD. Prospective comparative study of open meshplasty (Lichtenstein's method) versus laparoscopic inguinal hernia repair. *Int Med J*. 2014;1(9).
12. Koshariya M, Soni M, Malpani P, Parmar B, Shukla S. A comparative study between open and laparoscopic repair of inguinal hernia. *Int Surg J*. 2019;6:3353-8.