



## Radio Diagnosis

## ROLE OF NON CONTRAST COMPUTED TOMOGRAPHY OF PARANASAL SINUSES IN EVALUATION OF PATIENTS WITH HEADACHE.

<b>Dr. Meghanath N</b>	Junior Resident, The Oxford Medical College, Hospital & Research Centre, Bengaluru.
<b>Dr. Suresh P</b>	Professor and HOD, The Oxford Medical College, Hospital & Research Centre, Bengaluru.
<b>Dr. Lakshmeesha M T</b>	Assistant Professor, The Oxford Medical College, Hospital & Research Centre, Bengaluru.
<b>Dr. Vikas M*</b>	Senior Resident, The Oxford Medical College, Hospital & Research Centre, Bengaluru. *Corresponding Author

**ABSTRACT** Headache is the most frequently suffered illness by human beings and affects wide range of population with a variety of etiology. The primary headache disorders which include migraine, cluster and tension-type headaches, account for the majority of headaches, while secondary headaches which are those with underlying pathology are far less common. Most patients presenting with headache in the primary care setting do not have serious underlying conditions. The relative rarity of secondary headaches compared with the large number of patients with primary headache raises concerns about the wisdom of routine studies like computed tomography of paranasal sinus to exclude underlying causes of headache.

**KEYWORDS :** Headache, Non Contrast CT, Paranasal sinuses.

**INTRODUCTION**

Headache is one of the common symptoms of various disorders with multi-factorial origin.

As much as 90 percent of individuals have at least one episode of headache each year and severe headache is reported to occur at least in 40 % of population annually.<sup>1</sup> Headache can be acute or chronic and it is classified as primary headache and secondary headache. The primary headache disorders which include migraine, cluster and tension-type headaches, account for the majority of headaches, while secondary headaches which are those with underlying intracranial or paranasal sinus pathologies are less common.<sup>2</sup>

Diseases of the paranasal sinuses include wide spectrum of disorders ranging from inflammatory conditions to neoplasms (both benign and malignant).<sup>3</sup>

In the last 25 years, CT scan has become a useful diagnostic modality in the evaluation of PNS and an integral part of surgical planning. Most patients presenting to the primary-care physician with non-acute headaches and no other neurological signs or symptoms would not be suffering from underlying serious conditions.<sup>4</sup>

The CT images clearly show fine structural architecture of bony anatomy thereby determining various anatomical variations, extent of the disease and characterization of various inflammatory, benign and malignant sinonasal diseases.<sup>5</sup>

CT has become the investigation of choice for radiological diagnosis of nasal and sinus diseases, as CT images clearly show air filled sinuses and fine structural architecture of bony anatomy.<sup>6</sup>

Multi Detector CT (MDCT) allows assessment of the patency of sinonasal passages and shows the effect of anatomic variants, inflammatory disease or both on patency. MDCT can show anatomic structures that are not visualized by physical examination or diagnostic nasal endoscopy.<sup>7</sup>

**OBJECTIVES OF THE STUDY**

1. To evaluate the role of non-contrast paranasal sinuses in patients with headache.
2. To diagnose the cause of the headache

**METHODOLOGY**

The study was performed from April 2021 to May 2022 on 52 patients who presented with acute and chronic headache with various departments of The Oxford Medical College, Hospital and Research Centre Bangalore. They were evaluated clinically and underwent Non-Contrast CT PNS using a 16 slice GE Revolution ACT CT scanner machine. All patients aged between 18 to 85 years were included and

excluding patients with headache due to ophthalmic cause, immediate history of trauma and pregnant patients.

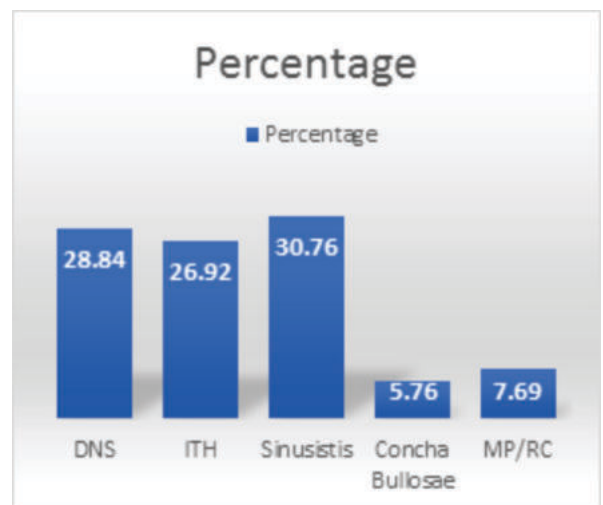
**Study Design**

- Descriptive Cross-sectional study.
- Study Duration: 12 Months from 01<sup>st</sup> March 2021 to 28<sup>th</sup> Feb. 2022.
- Place of study: The Oxford Medical College, Hospital and Research Centre, Bangalore
- Sample Size: 52 Patients.

**RESULTS**

**Table 1: Distribution Of Patients With Headache On Ct Pns Findings.**

CT PNS	Frequency	Percent (%)
DNS	15	28.84
ITH	14	26.92
Sinusitis	16	30.76
Concha bullosae	3	5.76
Sinonasal polyp/Mucosal polyp / Retention cyst	4	7.69



**Graph 1: Bar Diagram Showing Distribution Of Patients According To Ct Pns Findings.**

**DISCUSSION**

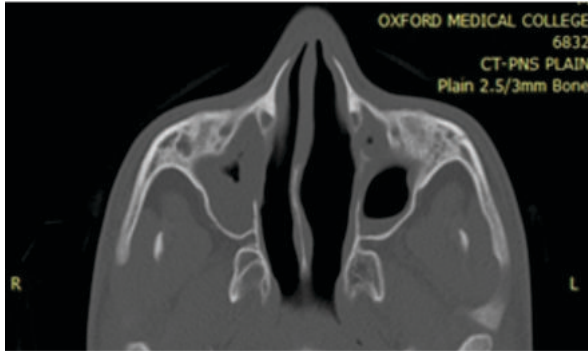
A total 52 patients underwent CT scan of Paranasal sinuses.

A detailed clinical history was taken from the patients and requisition

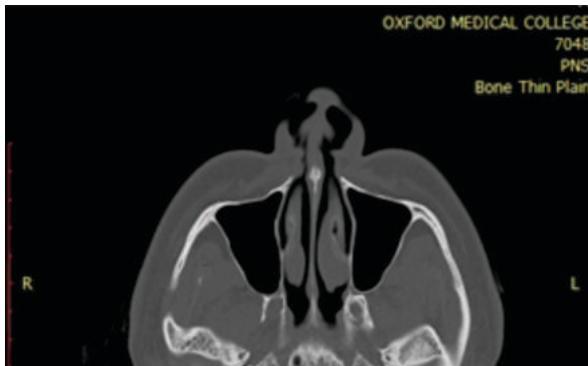
by clinician prior to including them in the study and included a history of the nature of the headache, onset of headache (sudden or insidious), duration of headache, associated symptoms like nausea, vomiting, blurring of vision, photophobia, fever, running nose, neurological deficits or any Systemic illness.

Those patients with known refractory error of the eye were excluded in this study.

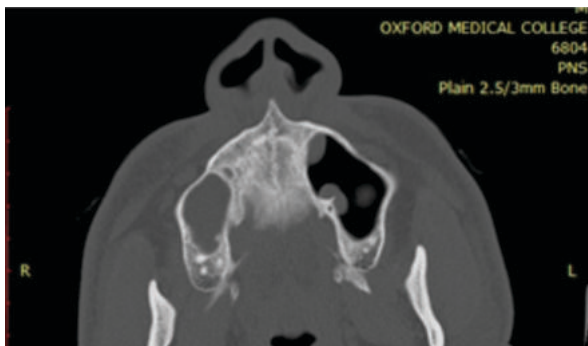Significant abnormalities on CT PNS in patients presenting with headache were 15 patients (28.84 %), 14 patients (26.92 %) had Inferior turbinate hypertrophy (ITH), 16 patients (30.76%) had sinusitis, 3 patients (5.76%) -concha bullosae, 4 patients (7.69 %) - Mucosal polyp/Retention cyst (MP/RC), on computed tomography of paranasal sinus.



**Case No:1 Non-contrast CT PNS Showing Chronic Bilateral Maxillary Sinusitis With DNS With A Bony Nasal Spur Towards Right Side.**



**Case No:2 Non-contrast CT PNS showing bilateral Inferior Turbinate Hypertrophy (ITH)**



**Case No: 3 Non-contrast CT PNS Showing a large Mucosal Polyp/Retention Cyst (MP/RC) in the maxillary sinus.**

## CONCLUSIONS

- Non-Contrast CT Scan of PNS is useful screening modalities in evaluation of patients presenting with headache.
- Non-Contrast CT Scan of PNS can diagnose the cause of headache and can also rule out structural abnormalities.
- Non-Contrast CT of PNS is the modality of choice in imaging the paranasal sinuses.
- Non-Contrast CT evaluation of PNS in symptomatic patients helps in planning the further management of the patient.

## REFERENCES

1. Fauci AS, Braunwald E, Kasper, Hauser SL, Longo DL, Jameson JL, et al. Headache. In: Harrisons Principles of Internal Medicine. 17th ed. New York: McGraw Hill; 2008. p.95-106(vol 1).
2. Levin M. The international classification of headache disorders, (ICHD III)-changes and challenges. Headache: The Journal of Head and Face Pain. 2013 Sep;53(8):1383-95.
3. Verma J, Tyagi S, Srivastava M, Agarwal A. Computed tomography of paranasal sinuses for early and proper diagnosis of nasal and sinus pathology. Int J Otorhinolaryngol Head Neck Surg. 2016 Apr;2(2):70.
4. Holle D, Obermann M. The role of neuroimaging in the diagnosis of headache disorders. Therapeutic advances in neurological disorders. 2013 Nov;6(6):369-74.
5. Kandukuri R, Phatak S. Evaluation of sinonasal diseases by computed tomography. Journal of clinical and diagnostic research: JCDR. 2016 Nov;10(11):TC09.
6. Zinreich S. Rhinosinusitis: Radiologic diagnosis. Otolaryngology - Head and Neck Surgery. 1997;117(3):27-34.
7. Miller JC. Imaging for Sinusitis. Radiology Rounds A Newsletter for Referring Physicians Massachusetts General Hospital Department of Radiology. 2009;7(8)