



## LARGE OVARIAN TUMOR IN TERM PREGNANCY

Dr. CH sai vasudha

Dr. Vara Prasanna

Dr. Shamshad  
Begum

## KEYWORDS :

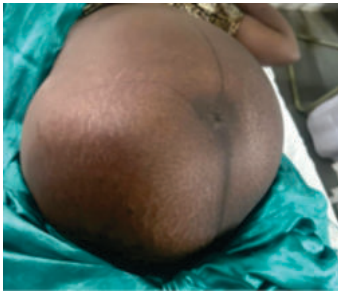## INTRODUCTION

Incidence of ovarian tumor in pregnancy is 1-2%. Most common are functional cyst of ovary, others being cystic teratoma, serous & mucinous cystadenoma. Tumors >10cms are operated in II trimester.

## Case Report

20yrs primi 39wks 2days came with pain abdomen since 1 day.

P/A ;Abdomen was over distended with irregular surface, uterus pushed to right side, whole cystic mass occupying left hypochondrial, iliac, lumbar region with variable consistency, irregular surface restricted mobility, mild tenderness, dull note over mass.



## Investigations:

**USG Abdomen:** single live intrauterine gestation of 38wk with AFI 8cms, multiloculated left ovarian cystic mass 23\*26 cms, thick septations.

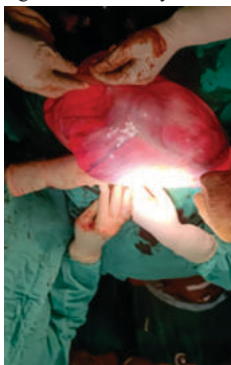
**MRI Abdomen & Pelvis:** left ovarian mass 28\*23\*23 suggestive of serous cystadenoma.

Other routine blood investigations are within normal.

- CA125 - 12u/ml, CEA- 0.785ng/ml
- LDH- 212U/ml, AFP- 162.8ng/ml
- RMI: U\*M\*CA125
- $1 \times 1 \times 12 = 12$  suggestive of benign mass

## Management

- As patient is in latent labor, emergency
- laparotomy with left ovarian cystectomy & primary cesarean
- section under GA was done.
- patient was discharged in satisfactory condition.



## Intra Operative Findings

Alive, mch, 2.5kgs was delivered by lower segment cesarean section. a huge cyst of 35\*25 cms cystic mass arising from left ovary with pedicle. contralateral ovary, both fallopian tubes normal. peritoneal washings done sent for HPE. clockwise examination of pelvic, intra abdominal organs was done, no evidence of metastasis noted.

**HPE:** suggestive of mucinous cystadenoma.

## CONCLUSION

Ovarian mass during pregnancy should be accurately evaluated to decide most appropriate treatment.

USG & MRI are safe, allow distinguish between benign & malignant lesions.

Watchful waiting adopted unless acute emergency, is advised for benign ovarian tumors in pregnancy.2