



## SPONTANEOUS URETHRAL PROLAPSE WITH GANGRENOUS CHANGES IN POST-MENOPAUSAL PATIENT- A RARE PRESENTATION.

**Dr. Deepak M**

Professor & HOD, Department of Urology, Chettinad Medical College, Chennai.

**Dr. Komaragiri  
Viswanadh\***

Urology Resident, Chettinad Medical College, Chennai. \*Corresponding Author

**ABSTRACT** **Introduction:** Urethral prolapse (UP) is a circular complete eversion of the distal urethral mucosa through the external meatus. It is a rare condition seen mostly in African American premenarcheal girls & rarely in post-menopausal women. **OBJECTIVE:** Our approach and surgical management of Urethral prolapse. **Case Report:** A 75-year-old female patient presented with complaints of mass per vagina for 3 years. Patient also gives History of Obstructive LUTS for 6 months. History of associated with Bleeding Per vagina for 1 week. On thorough evaluation, patient is diagnosed to have Urethral mucosal Prolapse with gangrenous changes and Grade 4 Uterine Prolapse. Patient Underwent Urethral Prolapse Excision plus Vaginal Hysterectomy with Pelvic floor repair. **Results:** On follow up of 6 months after surgery, Patient is asymptomatic. **Conclusion:** Urethral prolapse is a rare encounter among adult female patients. In choosing this patient's management we had to bear in mind the severity of her symptoms, a high recurrence rate after pure medical treatment. Surgical excision remains the most definitive therapy, in our opinion achieves a more complete resection and is more anatomic.

**KEYWORDS :** Urethral Prolapse, Surgical Management.

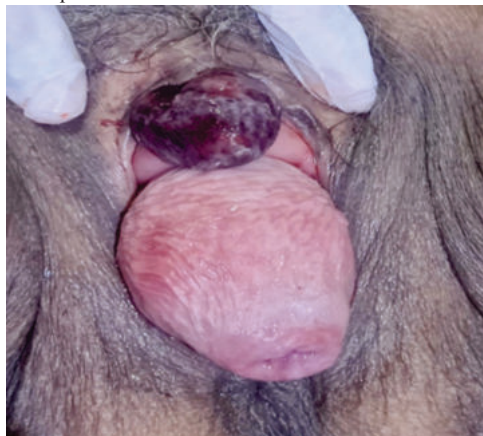### INTRODUCTION

Urethral prolapse is a rare clinical condition presented as a round doughnut-shaped mass secondary to complete distal urethral mucosa protrusion through the external meatus of the urethra.

Urethral prolapse has been reported mostly in prepubertal girls and post-menopausal women [1]. Prepubertal girls are usually asymptomatic, while post-menopausal women are often symptomatic [2]. Common symptoms include vaginal bleeding and irreducible painful round doughnut-shaped mass. Treatment of urethral prolapse should begin with medical therapy in most patients [3]. However, in patients who are symptomatic with severe pain, visible thrombosis, necrosis of the tissue, bleeding, or distress, surgical excision may be a first-line option given the effective time required for oestrogen, as well as the low likelihood of successful resolution. Especially in cases of clearly thrombosed or strangulated prolapse, surgical excision should be the first-line therapy [4]. We here report a case of spontaneous urethral prolapse in a post-menopausal woman, successfully managed by primarily circumferential excision of the prolapsed urethral mucosa.

### CASE REPORT

A 75-year-old female patient presented with complaints of mass per vagina for 3 years. Patient also gives History of Obstructive LUTS for 6 months. H/o of burning micturition for 10 days. History of associated with Bleeding Per vagina for 1 week. No h/o chronic Cough or constipation. Patient attained menopause 25 years back. Obstetric history-patient has 6 children; P6L6A1, previous 6 Full term normal vaginal delivery. On examination, we found a tender blackish globular doughnut-shaped mass (5 x 3 cms) protruding from vagina, mass bleeds on touch. Our per vaginum examination also revealed Grade 4 uterine Prolapse/Procidencia.

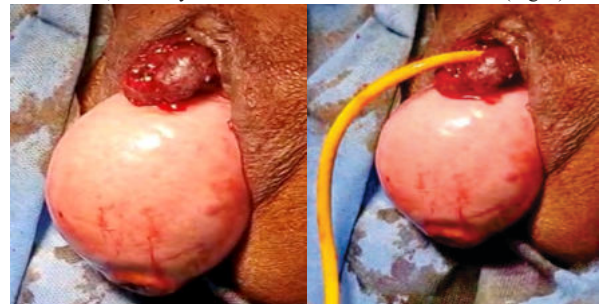


**Figure 1.** Photograph of urethral prolapse on admission.

A pelvic ultrasound scan was done and apparently it is normal.

On thorough evaluation, patient is diagnosed to have Urethral mucosal Prolapse with gangrenous changes and Grade 4 Uterine Prolapse/Procidencia.

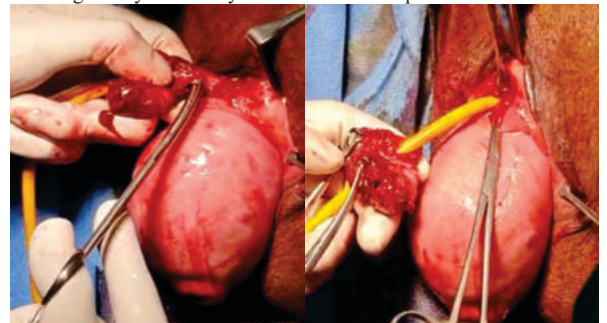
Since ours is a tertiary institute, we have taken opinion of Gynaecologist. We along with gynaecology team have planned for Urethral prolapse excision with vaginal hysterectomy. The patient was taken to the theatre after taking informed consent and was counselled about the diagnosis, the option management, and eventual complications. A preoperative assessment was made. Under Spinal anaesthesia, a urinary catheter was inserted into the bladder (Fig. 2)



**Figure 2.** Photograph of urethral prolapse after Foley catheter insertion.

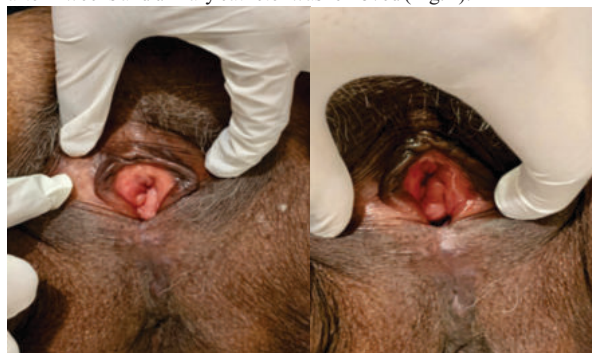Patient in lithotomy position, a circumferential excision of the prolapsed urethral mucosa was made followed by an interrupted haemostatic suturing using vicryl 4/0. There was no complication, and the blood loss was estimated to be less than 50 ml. The procedure lasted 15 minutes.

After our excision case was handed over to gynaecologist to proceed with Vaginal Hysterectomy and Pelvic Floor Repair.



**Figure 3.** Intra-Operative Photographs of urethral prolapse excision.

The catheter was left in situ for 2 weeks before being discharged. After then she started applying Evalon (oestrogen) cream, a conjugated oestrogen cream, twice per day for 2 weeks. Patient came for follow up after 2 weeks and urinary catheter was removed (Fig. 4).



**Figure 4.** Photograph-2 weeks post-management of the urethral prolapse.

Histopathology report showed haemorrhagic necrosis of urethral mucosa.

Six months later she was reviewed and was found asymptomatic.

## DISCUSSION

Urethral prolapse occurs when the distal urethral mucosa protrudes through the external meatus. The diagnosis is based essentially on by clinical findings on physical examination, which reveals an anterior vulvar bulk of soft, friable tissue, with the urethral meatus usually in the center (a “doughnut”-shaped mass). In symptomatic cases, vaginal bleeding is the most common complaint; however, hematuria, dysuria, frequency, urgency, nocturia, pain, dyspareunia, and urinary retention are other potential presenting symptoms. Imaging is usually unnecessary and should be ordered only if another condition or infection is suspected [2].

UP is an uncommon condition, occurring more frequently in prepubertal girls and postmenopausal women; the possibility should always be considered when evaluating a periurethral lesion in these patients. The differential diagnosis includes neoplasm (vaginal rhabdomyosarcoma, urethral carcinoma or papilloma); urethral caruncle, polyp, or diverticulum; Skene's cyst; abscess; HPV; prolapsing ureterocele; imperforate hymen; and sexual abuse [10].

In one study, three patients were treated for more than a year on the basis of an incorrect diagnosis of urethral caruncle, without resolution. One can argue that the conservative treatment with topic oestrogen is the same for both conditions, but resolution was nevertheless considerably delayed in the presence of major symptoms.

The pathophysiology of UP remains uncertain. The main etiologic hypothesis is oestrogen deficiency, because of the preponderance of UP in the prepubertal and postmenopausal periods. Postpartum, there is a mild oestrogen deficiency, which may explain the rare cases that occur in this period [9]. Other contributing factors include high intra-abdominal pressure, perineal or urethral trauma (including catheterization), injection of bulking agents, sexual abuse, and infection [7].

In 1986, Lowe studied the histopathology of UP and observed a cleavage plane between the inner longitudinal and outer circular-oblique smooth muscle layers of the urethra, as well as marked mucosal eversion and vascular congestion [6, 10]. Another possible risk factor could be a malformation or weak collagen structures, since many patients report a family history of hernias and vaginal prolapses. UP can be complicated or uncomplicated and partial or total. It is complicated when there is vascular thrombosis of the mucosa, significant bleeding, pain, infection, or urinary retention. The most common presentation is uncomplicated prolapse, which can be fully asymptomatic or present with minor bleeding or mild pain. The theory is that UP begins as a partial prolapse and becomes complete (circumferential), since in many cases a complete prolapse becomes partial with conservative measures and an untreated partial prolapse can become complete.

Treatment of UP is controversial and can be surgical or conservative.

The nonsurgical approach consists basically of sitz bath and topical oestrogen cream for approximately 6 weeks; we usually recommend it for mild or asymptomatic cases [8, 10, 11]. As urinary infection is rare, antibiotics are unnecessary. Topical steroids are ineffective. The success of nonsurgical treatment is variable, ranging from 33 to 92%, and appears to be more effective in prepubertal girls than in postmenopausal women [10]. In some cases, spontaneous resolution may occur. The recurrence rate with conservative management is up to 67%, while surgery is associated with higher cure rates and rapid relief of symptoms [5].

Our case, patient is postmenopausal patient was treated surgically with good outcome. There are many surgical options, all of which include resection of the prolapsed mucosa (over a Foley catheter or not) and suture of the urethral mucosa to the meatus. We used the Kelly–Burnham (excisional) technique, excising the prolapsed mucosa over an indwelling foley catheter and closing the incision by approximating the normal urethral mucosa to the introital mucosa with interrupted absorbable sutures[7, 10]. Another option is manual prolapse reduction under general anaesthetic, but this is associated with a risk of only partial reduction of 62% and recurrence of 12% in children. This technique has not been studied in adults [12]. Some authors argue that slings can be effective to treat UP [13].

As per literature, the most frequent complications described are urethral stricture and postoperative urinary retention.

Therefore, we believe that management should be individualized, with the conservative approach selected for asymptomatic or mild cases and surgical excision for complicated or very symptomatic patients.

In short, UP is an underdiagnosed entity not only due to its rarity, but also to the unfamiliarity of clinicians—even specialists—with this condition. Complications are not uncommon, and although UP should be readily recognized by clinical examination alone, correct diagnosis is the main determining factor of timely treatment and resolution of symptoms. We hope this case report can raise awareness of this diagnosis in the adult population and improve the care of these patients.

## CONCLUSION

Surgical excision may be a first-line option given the effectiveness of the long-time required for oestrogen, as well as the low likelihood of successful resolution, especially in case of thrombosed or strangulated prolapse, severe prolapse mimicking a uterus prolapse, and a high likelihood of recurrence and loss to follow up.

## REFERENCES

- [1] C. Holbrook, D. Misra Surgical management of urethral prolapse in girls: 13 years' experience *BJU Int.*, 110(1)(2012), pp. 132-134
- [2] T.-C. Hu, C.-R. Ker, C.-Y. Long Urine retention caused by urethral prolapse mimicking uterine prolapse Taiwan. *J. Obstet. Gynecol.*, 59(1)(2020), pp. 165-166
- [3] Y. Wei, *et al.* Diagnosis and treatment of urethral prolapse in children: 16 years' experience with 89 Chinese girls *Arab J. Urol.*, 15(3)(2017), pp. 248-253
- [4] M.E. Hall, T. Oyesanya, A.P. Cameron Results of surgical excision of urethral prolapse in symptomatic patients *NeuroUrol. Urodyn.*, 36(8)(2017), pp. 2049-2055
- [5] Jessop ML, Zaslau S, Al-Omar O. A case of strangulated urethral prolapse in a premenopausal adult female. *Case Rep Urol.* 2016;2016:1802623. doi: 10.1155/2016/1802623.
- [6] Olumide A, Kayode Olusegun A, Babatola B. Urethral mucosa prolapse in an 18-year-old adolescent. *Case Rep Obstet Gynecol.* 2013;2013:231709. doi: 10.1155/2013/231709.
- [7] Ninomiya T, Koga H. Clinical characteristics of urethral prolapse in Japanese children. *Pediatr Int.* 2017;59(5):578–582. doi: 10.1111/ped.13226.
- [8] Holbrook C, Misra D. Surgical management of urethral prolapse in girls: 13 years' experience. *BJU Int.* 2012;110(1):132–134. doi: 10.1111/j.1464-410X.2011.10752.x.
- [9] Dorado M, Molina R, Alvarez M, et al. Urethral prolapse, is surgical treatment necessary? *Arch Esp Urol.* 2019;72(6):619–620.
- [10] Hill AJ, Siff L, Vasavada SP, et al. Surgical excision of urethral prolapse. *Int Urogynecol J.* 2016;27(10):1601–1603. doi: 10.1007/s00192-016-3021-9.
- [11] Fiogbe MA, Hounnou GM, Koura A, et al. Urethral mucosal prolapse in young girls: a report of nine cases in Cotonou. *Afr J Paediatr Surg.* 2011;8(1):12–14. doi: 10.4103/0189-6725.78661.
- [12] Ballouhey Q, Abbo O, Sanson S, et al. Urogenital bleeding revealing urethral prolapse in a prepubertal girl. *Gynecol Obstet Fertil.* 2013;41(6):404–406. doi: 10.1016/j.gyobfe.2013.04.006.
- [13] Levin P, Harvie HS, Guertel NL. Novel approach for correction of urethral prolapse using a retropubic sling with urethral fixation. *Int Urogynecol J Pelvic Floor Dysfunct.* 2009;20(8):995–997. doi: 10.1007/s00192-009-0806-0.