

A Case Report on The Triple Variations in The Arm and Their Developmental Basis



Medical Science

KEYWORDS : Median Nerve, Brachial Artery, Biceps Brachii Muscle, Supernumerary Head, Surgeons, Orthopaedicians, Anaesthetist

Dr. Sharadkumar Pralhad Sawant

Associate Professor, Department of Anatomy, K. J. Somaiya Medical College, Somaiya Ayurvihar, Eastern Express Highway, Sion, Mumbai-400 022.

ABSTRACT

During routine dissection of a 70 years old embalmed male cadaver in the department of Anatomy at K. J. Somaiya Medical College, Sion, Mumbai, INDIA, the triple variations i.e. the unusual course of median nerve and brachial artery in relation to the supernumerary head of biceps brachii muscle were observed in the right upper limb. The variant median nerve was piercing the supernumerary head of biceps brachii muscle. The brachial artery travelled posterior to the supernumerary head of biceps brachii muscle. The short and long heads have their normal origin, supernumerary head had originated from the anteromedial surface of the superior part of the shaft of the humerus. The common tendon then got inserted into the posterior rough part of the radial tuberosity. The thorough and meticulous dissection of axilla, arm, forearm and palm of both the upper limbs were done. The variations were unilateral and the left upper limb was normal. The photographs of the variations were taken for proper documentation. Conclusion: The variations of median nerve and brachial artery in relation to the supernumerary head of biceps brachii muscle are clinically important for surgeons, orthopaedicians, anaesthetist performing pain management therapies on the upper limb and plastic surgeons doing flap surgery. A lack of awareness of these variations might complicate surgical repair and may cause ineffective nerve blockade.

Introduction:

The biceps brachii is a muscle with two heads in the flexor compartment of the arm. The short head arises from the tip of coracoid process along with the coracobrachialis and, the long head from the supraglenoid tubercle of scapula. The origin of long head is intracapsular and extra synovial. The tendon of the long head then descends on the humerus lying in the bicipital groove. The two heads of the muscle fuse in the middle of the arm forming a common tendon and inserts on the radial tuberosity and into the deep fascia on the medial aspect of the forearm by an aponeurotic band named bicipital aponeurosis (also called lacertus fibrosis). The muscle is the prime supinator of the forearm and a powerful flexor of the elbow joint as well. It is also a weak flexor of the shoulder joint. The biceps brachii muscle is innervated by the musculocutaneous nerve (1, 2). The median nerve is normally formed by the union of lateral root of median nerve arising from the lateral cord (C5, C6, C7) of brachial plexus and medial root of median nerve arising from the medial cord (C8, T1) of brachial plexus anterior to the axillary artery. Some fibres from C7 often leave the lateral root to join the ulnar nerve. Clinically they are believed to be mainly motor to the flexor carpi ulnaris. The median nerve enters the arm at first lateral to the brachial artery. Near the insertion of the coracobrachialis, it crosses in front of the artery, descending medial to it, to the cubital fossa, where it is posterior to the bicipital aponeurosis and anterior to the brachialis. It usually enters the forearm between the heads of the pronator teres, crossing to the lateral side of the ulnar artery and separated from it by the deep head of pronator teres (1). Many authors have documented variations of biceps brachii muscle (3, 4, 5, 6).

Case Report:

During routine dissection of a 70 years old embalmed male cadaver in the department of Anatomy at K. J. Somaiya Medical College, Sion, Mumbai, INDIA, the triple variations i.e. the unusual course of median nerve and brachial artery in relation to the supernumerary head of biceps brachii muscle were observed in the right upper limb. The variant median nerve was piercing the supernumerary head of biceps brachii muscle. The brachial artery travelled posterior to the supernumerary head of biceps brachii muscle. The short and long heads have their normal origin, supernumerary head had originated from the anteromedial surface of the superior part of the shaft of the humerus. The common tendon then got inserted into the posterior rough part of the radial tuberosity. After piercing the accessory head the median nerve descends over the brachialis muscle and enters to the forearm passing between the two heads of pronator teres in its usual course. It was observed that the accessory head was innervated by the muscular branches of musculocutaneous nerve as the main two heads. The vascular supply of this third head was also the brachial artery. The thorough and meticulous dissection of axilla, arm, forearm and palm of both the

upper limbs were done. The variations were unilateral and the left upper limb was normal. The photographs of the variations were taken for proper documentation.

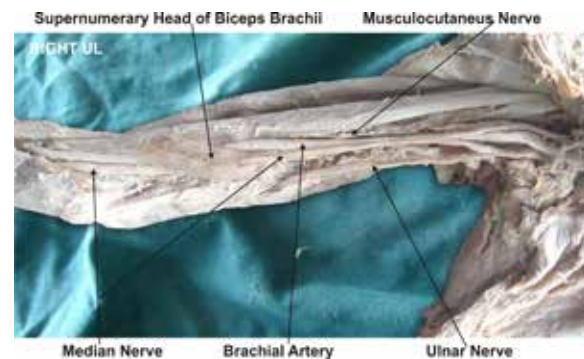


Figure – 1 : Photographic presentation of the unusual course of median nerve and brachial artery in relation to the supernumerary head of biceps brachii muscle.

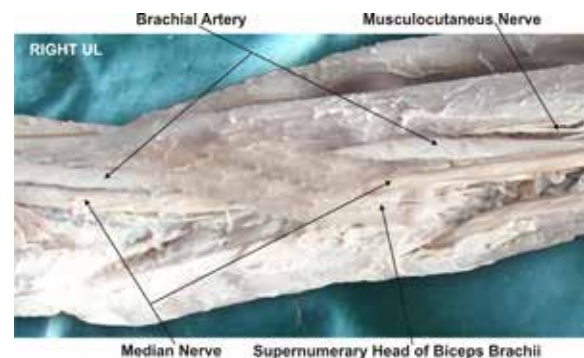


Figure – 2 : Photographic presentation of the variant median nerve piercing the supernumerary head of biceps brachii muscle. The brachial artery travelled posterior to the supernumerary head of biceps brachii muscle.

Discussion:

The variations of the biceps brachii muscle are very common (4, 6, 7, 8, 9). According to some authors the most frequent variations of biceps brachii was in the number of the bellies (10). Supernumerary heads of the biceps brachii can be three, four, five or even seven headed biceps brachii (11). Supernumerary third head of Biceps brachii is frequently reported in literature (6). Racial difference is found in the number of supernumerary heads i.e. in 8% of Chinese, 10% of European populations, 12%

of African blacks, and 18% of Japanese population (7). A high incidence of the third head has also been reported in South African Blacks (20.5%), as compared to the African Whites (8.3%) (4). Though some of the authors claim that there were no clear racial differences, some of them mention significant differences between the populations (4, 10, 12, 13, 14). No significant differences in the prevalence of variations has been reported between male and female or between left and right sides, but the variation was high unilaterally (6). Classification of the accessory heads is according to their location as superior, infero-medial, and infero-lateral humeral heads. In the present case the supernumerary third head of biceps brachii muscle was the infero-medial type of humeral head. It was continuous with the insertion of the coracobrachialis muscle and closely related to medial intermuscular septum and brachialis muscle. According to the literature the three principal origins of the accessory head of biceps brachii muscle were the humeral shaft inferior to and common with the insertion area for the coracobrachialis muscle, a brachial origin where the muscle originated distally from the medial humeral shaft, adjacent to and in common with the brachialis muscle or a dual origin where the medial fibers originated from the short head of biceps brachii muscle and the lateral fibers from the deltoid fascia and the insertion area of this muscle. In another study, an accessory head has been reported arising from the distal part of the pectoralis major muscle (15). In the present case a few fibers of the supernumerary third head of the biceps brachii muscle arose from the fascia of brachialis muscle. These fibers have crossed the median nerve. In other words the median nerve was piercing the accessory head before entering into the forearm. The supernumerary third head of biceps brachii muscle crossed the brachial artery. The presence of such type of supernumerary third head of the biceps brachii muscle may cause compression on the median nerve and the brachial artery. So, information on such a variation is of importance for the differential diagnoses of the other compression causes such as enlarged veins (16) or a fibrovascular band (17). Biceps brachii is a considerable component in plastic surgery (18, 19, 20) but it is known that accessory heads of biceps brachii would be expandable and possibly has more value in flap surgery rather than the two main heads. The variation seen in present case would probably cause difficulty during elevating or transferring the flaps. The supernumerary third head of biceps brachii muscle documented in the present case causes no symptoms most of the time but they have the potential to compress the median nerve and the brachial artery with consequent functional impairment. Such type of variation is rare and not yet reported in literature. The compression of the median nerve and brachial artery by various types of structures leading to clinical neurovasculopathy has been found in literature (21, 22).

Developmental basis of present variation:

Embryologically, the intrinsic muscles of the upper limb differentiate in situ, opposite the lower six cervical and upper two thoracic segments, from the limb bud mesenchyme of the lateral plate mesoderm. The formation of muscular elements in the limbs takes place shortly after the skeletal elements begin to take shape. At a certain stage of development, the muscle primordia within the different layers of the arm fuse to form a single muscle mass (23). Langman stated, however, that some muscle primordia disappear through cell death despite the fact that cells within them have differentiated to the point of containing myofilaments (24). Failure of muscle primordia to disappear during embryologic development may account for the presence of the accessory muscular bands reported in this case.

Clinical significance:

The existence of such variation should be kept in mind by the surgeons operating on patients with high median nerve palsy and brachial artery compression, by the orthopaedicians dealing with fracture of the humerus, the radiologists while doing radiodiagnostic procedures e.g. CT scan, MRI of the arm and angiographic studies and also by the physiotherapists. These accessory fibres of brachialis may be used as a transposition flap in deformities of infraclavicular and axillary areas and in post-mastectomy reconstruction (25). The accessory fibres of brachialis may prove significant and lead to confusion during surgical procedures or cause compression of neurovascular structures.

Conclusion :

The knowledge of such variations is important for anatomists and clinicians. A lack of awareness of these variations might complicate surgical repair, flap surgery and may cause ineffective nerve blockade. Also, these muscles should not be mistaken for tumors on magnetic resonance imaging of the arm.

Competing interests:

The author declare that he has no competing interests.

Acknowledgement:

Author is also thankful to Dean Dr. Geeta Niyogi Madam for her support and encouragement. Author is also thankful to Dr. Arif A. Faruqui and Mr. M. Murugan for their help. Author also acknowledge the immense help received from the scholars whose articles are cited and included in references of this manuscript. The author is also grateful to authors / editors / publishers of all those articles, journals and books from where the literature for this article has been reviewed and discussed.

REFERENCE

1. Williams P.L., Bannister L.H., Berry M.M. et al. Gray's Anatomy. 39th ed. London Churchill Livingstone, 2005: 231-232, 803-4, 877, 1270. | 2. Snell, R. S. Clinical Anatomy. 7th. ed. Lipincott Williams & Wilkins, 2004. | 3. Kosugi, K.; Shibata, S. & Yamashita, H. Supernumerary head of biceps brachii and branching pattern of the musculocutaneous nerve in Japanese. *Surg. Radiol. Anat.*, 14:175-85, 1992. | 4. Asvat, R.; Candler, P. & Sarmiento, E. E. High incidence of the third head of biceps brachii in South African populations. *J. Anat.* 182:101-4, 1993. | 5. Jakubowicz, M. & Ratajczak, W. Variation in morphology of the biceps brachii and coracobrachialis muscles associated with abnormal course of blood vessels and nerves. *Folia Morphol. (Warsz)*, 58: 255-8, 2000. | 6. Rodriguez-Niedenführ, N.; Vazquez, T.; Choi, D.; Parkin, I. & Sanudo, J.S. Supernumerary humeral heads of the biceps brachii muscle revisited. *Clin. Anat.*, 16:197-203, 2003. | 7. Bergman, R. A.; Thompson, S. A. & Afifi, A. K. Catalogue of Human Variation. Munich: Urban and Schwarzenberg. 27-30, 1984. | 8. Greig, H. W.; Anson, B. J. & Budinger, J. M. Variations in the form and attachments of the biceps brachii muscle. *Bull. Northwest Univ. Med Sch.*, 26:241-4, 1952. | 9. Tamura, H. Case of the brachial biceps with two accessory heads in each. *Kaibogaku Zasshi*, 46:12-6, 1971. | 10. Bergman, R. A.; Afifi, A. K. & Miyauchi, R. Part I: Muscular system. In: *Illustrated encyclopedia of human anatomic variation*, 2000. | 11. Swieter, M. G. & Carmichael, S.W. Bilateral three-headed biceps brachii muscles. *Anat. Anz.*, 148:346-9, 1980. | 12. Nakatani, T.; Tanaka, S.; Mizukami, S. Bilateral four headed biceps brachii muscles: the median nerve and brachial artery passing through a tunnel formed by a muscle slip from the accessory head. *Clin. Anat.*, 11:209-12, 1998. | 13. Neto, H. S.; Camilli, J. A.; Andrade, J. C. T.; Filho, J. M. & Marques, M. J. On the incidence of the biceps brachii third head in Brazilian whites and blacks. *Ann. Anat.*, 180: 69-71, 1998. | 14. El-Naggar, M. M. & Zahir, F. I. Two bellies of the coracobrachialis muscle associated with a third head of the biceps brachii muscle. *Clin. Anat.*, 14:379-82, 2001. | 15. Sargon, F. M.; Tuncali, D. & Celik, H. An unusual origin for the accessory head of biceps brachii muscle. *Clin. Anat.*, 9:160-2, 1996. | 16. Braun, R.M.; Spinner, R.J. Spontaneous bilateral median nerve compressions in the distal arm. *J Hand Surg.*16:244-7, 1991. | 17. Holtzman, R. N.; Patel, M. R. & Mark, M. H. Median nerve neuralgia caused by a fibrovascular band in the distal forearm. *J. Hand Surg.*, 11:894-5, 1986. | 18. Muneuchi, D.; Suzuki, S.; Ito, O.; Saso, Y. One-stage reconstruction of both the biceps brachii and triceps brachii tendons using a free anterolateral thigh flap with a fascial flap. *J. Reconstr. Microsurg.*, 20:139-42, 2004. | 19. Willcox, T. M.; Teotia, S. S.; Smith, A. A. & Rawlings, J. M. The biceps brachii muscle flap for axillary wound coverage. *Plast. Reconstr. Surg.*, 110:822-6, 2002. | 20. Har-Shai, Y.; Kaufman, T.; Hasmonai, M.; Hirsowitz, B. & Schramek, A. External longitudinal splitting of the biceps brachii muscle for coverage of repaired brachial vessels: an anatomical study and clinical application. *Neurology*, 21:158-64, 1988. | 21. Gessini L, Jandolo B, Pietrangeli A. Entrapment neuropathies of the median nerve at and above the elbow. *Surg Neurol.* 1983; 19: 112-116. | 22. Nakatani T, Tanaka S, Mizukami S. Bilateral four-headed biceps brachii muscles: the median nerve and brachial artery passing through a tunnel formed by a muscle slip from the accessory head. *Clin Anat.* 1998; 11: 209-212. | 23. Arey L.B. *Developmental Anatomy*. In: *A Textbook and Laboratory Manual of Embryology*. 6th Ed., Philadelphia, WB Saunders company. 1960; 434-435. | 24. Langman J. *Medical Embryology*. 2nd Ed., Baltimore, Williams and Wilkins. 1969: 143-146. | 25. Khaledpour, C. Anomalies of the biceps muscle of the arm. *Anat. Anz.*, 58:79-85, 1985.