

## Giant Desmoid Tumor of Anterior Abdominal Wall With Recurrence in Foot:case Study



**Subject Awaited**

**KEYWORDS :**

<b>Dr. Kirit Parmar</b>	Associate Professor, M.S General Surgery , Department of General Surgery, smt.NHL municipal medical College
<b>Dr. Pratik Vyas</b>	Associate Professor, M.S General Surgery , Department of General Surgery, smt.NHL municipal medical College
<b>Dr. Bhavesh Dave</b>	Professor, M.S General Surgery , Department of General Surgery, smt.NHL municipal medical College
<b>By Dr. Dushyant Pawar</b>	3rd Year, Resident Doctor, Department of General Surgery, smt.NHL municipal medical College
<b>Dr. Brijesh Panchal</b>	3rd Year, Resident Doctor, Department of General Surgery, smt.NHL municipal medical College
<b>Dr. Rushikesh Gadhavi</b>	3rd Year, Resident Doctor, Department of General Surgery, smt.NHL municipal medical College

### ABSTRACT

*Desmoid tumors are rare slow growing benign and musculoaponeurotic tumors. Although these tumors have a propensity to invade surrounding tissues, they are not malignant. These tumors are associated with women of fertile age, especially during and after pregnancy. We report a young female patient with a giant desmoid tumor of the anterior abdominal wall with recurrent desmoid tumor on left foot. The patient had no history of an earlier abdominal surgery. Preoperative evaluation included abdominal ultrasound, computed tomography, and magnetic resonance imaging of left foot. The histology revealed a desmoid tumor. Primary surgical resection with immediate reconstruction of abdominal defect is the best management of this rarity.*

### 1.Introduction

Desmoid tumors (also called desmoids fibromatosis) are rare slow growing benign fibrous tumors without any metastatic potential but a strong tendency to invade locally and to recur. The term desmoids was coined by Muller in 1838 and is derived from the Greek word desmos, which means tendon like. These tumors often appear as infiltrative, usually well differentiated and locally aggressive in nature and also known as deep fibromatoses. Desmoid tumors may be classified as extra-abdominal, abdominal wall, or intra-abdominal (the last is more common in patients with familial adenomatous polyposis (FAP)). It is thought that the lesions may develop in relation to estrogen levels or trauma/operations. They constitute 3% of all soft tissue tumors and 0.03% of all neoplasms[1] These tumors are associated with women of fertile age, especially during and after pregnancy. The most common site of occurrence of desmoids is the anterior abdominal wall, with an incidence of 50% [1-8]

### 2. Case Report

A 35-year-old female patient presented to surgery department with a painless mass in the lower abdomen for 6 months which was gradually increasing in size with another mass in left foot. The patient had no history of previous abdominal surgery or any abdominal trauma. Patient underwent surgical excision of mass from left foot three years back n recurrence occurred from last 6 months.

On examination, a single lower abdominal mass involving right iliac fossa with another 3\*2 cm mass in left foot.

Preoperative image showing huge lump located in the anterior abdominal wall.

Lump was not fixed to the anterior abdominal wall, nontender, globular in shape of size 5\*5 cm with smooth surface, and firm in consistency.

Ultrasonography demonstrated a large solid heterogeneous hypoechoic mass showing internal vascularity, few anechoic areas

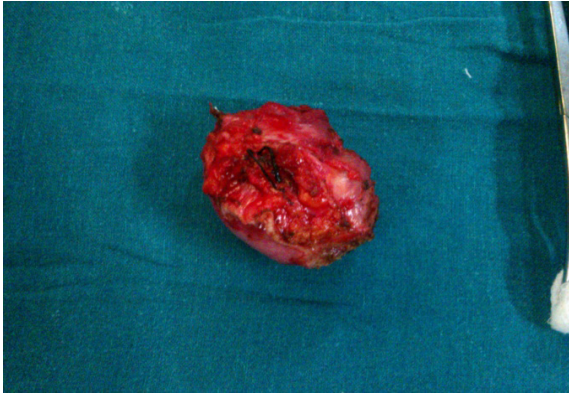
of necrosis, seen in right iliac fossa.

CT scan revealed a neoplastic anterior abdominal muscle mass arising from right anterolateral abdominal wall muscles in right iliac fossa causing stretching of subcutaneous tissue without any Intra-abdominal extension. Differentials include desmoid tumor and rhabdomyoma. No evidence of lymphadenopathy was detected. No evidence of free fluid was seen in pelvic and peritoneal cavity

CT scan showing mass arising from anterior abdominal musculature revealed a large mass, measuring 5\*5 cm arising from the right anterior abdominal wall musculatures. Fat plane to the surrounding organs appears normal. No enlarged lymph node or ascites were seen. No focal lesion was noted in bone or liver. Described CT imaging features were compatible with neoplastic anterior abdominal wall origin mass and considered for desmoid tumor. After preoperative workup, patient was planned for operation, and complete excision of the tumor\_ with wide surgical margins along with the anterior abdominal wall down to the peritoneum was performed, resulting in a large wall defect which was fig no.1 defect repaired with mesh

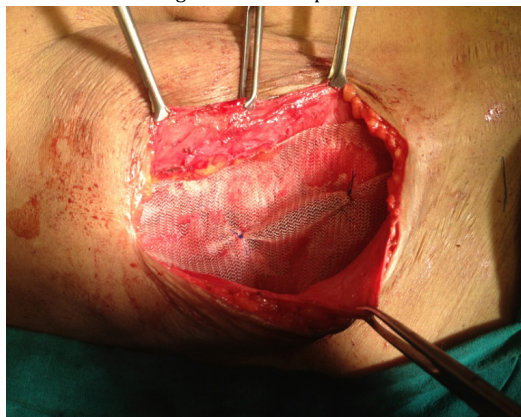

fig no.2 removed desmoids tumor



Repaired and reconstructed with polypropylene mesh[fig no.1]. complete excision of mass from the left foot with wound closed primarily.

The postoperative course was uneventful, and patient was discharged on the 9th postoperative day. Histopathological reports were consistent with desmoid tumor with negative surgical margins[fig no.2]

### 3. Discussion

Desmoid tumors are cytologically benign fibrous neoplasm originating from the musculoaponeurotic structures throughout the body.

Desmoid tumors are benign deep aggressive fibromatoses, originating from fascia and muscle aponeurosis with an infiltrating growth. Approximately, 3.7 new cases occur per one million persons per year and often associated with female gender, FAP, estrogen therapy, and occasionally with surgical trauma (1 in 4 cases). Trauma especially operative trauma may contribute to the formation of desmoid tumors. Estrogen may act as a growth factor. Endogenous estrogen levels have a close correlation with tumor growth factor rate. It has a higher prevalence in young women who experienced pregnancy and rare in males. They may be extra-abdominal (the shoulder girdle, trunk, and lower extremities), intra-abdominal (in the abdominal wall, especially the rectus and internal oblique muscles with their fascial coverings, and mesentery or retroperitoneum), multiple familial, and as part of Gardner's syndrome.

Abdominal desmoid tumor usually presents as a firm mass with ill-defined margins and no distinct capsule. On cut surface, they are gritty, glistening white and trabeculated resembling scar tissue. Histologically, desmoid tumors consist of elongated fibroblasts and myofibroblasts

On ultrasonography, desmoid tumors appear as well-defined lesions with variable echogenicity. On CT, they may appear as homogeneous or heterogeneous and hypo-, iso-, or hyperintense compared with the attenuation of muscles. Characteristic MRI findings include poor margination, low-signal intensity on T1-weighted images and heterogeneity on T2-weighted images, and variable contrast enhancement. MRI is superior to CT scanning in defining the pattern and the extent of involvement as well as in determining if recurrence has occurred after surgery, though both the modality CT and MRI aid in determining the extent of local invasion.

Wide local excision with reconstruction of the defect is the treatment of choice. Peritoneum, intraperitoneal organs, or adjacent bony structures involved by tumor must be resected as well. Incomplete tumor removal or positive surgical margins may lead to local recurrence (20% to 77% depending on the location, extent, and completeness of the initial resection). Abdominal wall desmoid tumors have a significantly lower recurrence rate (20% to 30%) and usually become evident within six months after excision. Radiotherapy, chemotherapy, and endocrine therapy are used in patients with inoperable tumors, local recurrences, or incompletely excised lesions. Metastatic disease has not been reported with desmoid tumor. Only few cases of malignant transformation in desmoid tumor are reported, and all were associated with local irradiation.

### 4.conclusion

Desmoid tumors in females are often associated with pregnancy or occur post-partum. The reasons behind this association are unclear. The history of painless abdominal mass, the age and sex of the patient, the location of the mass within the anterior abdominal wall, and the imaging features make desmoid tumor a strong primary diagnostic consideration even if it is a rare entity. Aggressive, wide surgical resection with negative margin is the best surgical option. Complete surgical excision of desmoid tumors is the most effective method of cure, sometimes necessitating removal of most of an involved anterior abdominal wall in such a giant desmoid tumor with immediate repair of resultant huge defect and reconstruction using prosthetic mesh for better functional results

## REFERENCE

- Kiel KD, Suit HD. Radiation therapy in the treatment of aggressive fibromatoses (desmoid tumors)Cancer. 1984;54(10):2051-2055. [PubMed]
- Fletcher CD. Myofibroblastic tumours: an update. Verhandlungen der Deutschen Gesellschaft für Pathologie. 1998;82:75-82. [PubMed] | 3. Lewis JJ, Boland PJ, Leung DHY, Woodruff JM, Brennan MF. The enigma of desmoid tumors. Annals of Surgery. 1999;229(6):866-873. [PMC free article] [PubMed] | 4. Lynch HT, Fitzgibbons R. Surgery, desmoid tumors, and familial adenomatous polyposis: case report and literature review. American Journal of Gastroenterology. 1996;91(12):2598-2601. [PubMed] | 5. Kumar V, Khanna S, Khanna AK, Khanna R. Desmoid tumors: experience of 32 cases and review of the literature. Indian Journal of Cancer. 2009;46(1):34-39. [PubMed] | 6. Overhaus M, Decker P, Fischer HP, Textor HJ, Hirner A. Desmoid tumors of the abdominal wall: a case report. World Journal of Surgical Oncology. 2003;1, article 11 [PMC free article] [PubMed] | 7. Lahat G, Nachmany I, Itzkowitz E, et al. Surgery for sporadic abdominal desmoid tumor: is low/no recurrence an achievable goal? Israel Medical Association Journal. 2009;11(7):398-402. [PubMed] | 8. Casillas J, Sais GJ, Greve JL, Iparraguirre MC, Morillo G. Imaging of intra- and extraabdominal desmoid tumors. Radiographics. 1991;11(6):959-968. [PubMed] | 9. Einstein DM, Tagliabue JR, Desai RK. Abdominal desmoids: CT findings in 25 patients. American Journal of Roentgenology. 1991;157(2):275-279. [PubMed] | 10. Waddell WR, Gerner RE. Indomethacin and ascorbate inhibit desmoid tumors. Journal of Surgical Oncology. 1980;15(1):85-90. [PubMed] |