


A Clinical and Histopathological Study of Varieties of Cutaneous TB and its Treatment Analysis



Medical Science

KEYWORDS : Cutaneous TB, Misleading, Epithelioid granuloma, ATT

Dr. Rikeeta Deshmukh

Resident , Department of dermatology, Smt SCL hospital, Ahmedabad

Dr. Raju Chaudhary

Associate professor, Department of dermatology, Smt SCL hospital, Ahmedabad

ABSTRACT

OBJECTIVE:- To study the patterns of clinical presentation of various types of cutaneous tuberculosis(TB) and to assess the efficacy of ATT treatment. **DESIGN:-** 10year study of patients attending skin opd,Shardabeben hospital. **RESULTS:-** Cutaneous TB was found in 0.15% of patients with 3:2 male preponderance and majority being 21-30year age. Lupus vulgaris 36% was most common, followed by Tuberculous verrucosa cutis and scrofuloderma. Face involved in 36% patients followed by buttocks and trunk as most common sites. Study revealed Single lesion in 90% patients, BCG vaccination in 75%, and Mantoux tested positive in 68% patients. Histopathologically correlation was important in clinically challenging cases. Diabetes was associated with 14% patients; hypertension with 7% patients; pulmonary TB was associated in 4% patients. All three diseases were found to be more common in Scrofuloderma. Disseminated disease was found more in unvaccinated patients and Scrofuloderma as compared to vaccinated and in other types. Patients were treated with ATT treatment category III regimen and followed up to find excellent recovery without relapse. **CONCLUSION:-** As cutaneous TB sometimes reflects the presence of pulmonary tuberculosis and some cases of cutaneous TB misleading as diagnosis of other skin condition; its incidence should not be ignored.

1. Introduction:-

Tuberculosis(TB) is a mycobacterial infection, mostly due to Mycobacterium tuberculosis, and others like M. Bovis and M. scrofulosum. TB is a worldwide common and communicable pathogen; transmitted mostly by airborne droplet inhalation, sometimes direct inoculation like Bacillus calmette-guerin (BCG).¹ Robert Koch first identified Mycobacterium tuberculosis.² Subsequently, the bacillus was detected in cutaneous lesions. The incidence of cutaneous TB is between 2% to 0.15%,³ which has recently dropped to 0.1% in the world.^{4,5} Despite strategic efforts and effective therapy, TB is still a major problem in India. The incidence of pulmonary, cutaneous and other extrapulmonary tuberculosis is on the rise particularly in this HIV and MDR -TB era. Cutaneous TB is rare extra-pulmonary variety of TB with varied clinical presentation; determined by route of infection, immune status of patients. Pillsburg and Shelly wrote "In skin, TB presents itself in an astonishing variety of form."⁶ Cutaneous lesions may be papules, nodules, plaques, ulcers, verrucous lesions, papillomatous tumours, vegetative reactions or cicatricial lesions. Cutaneous TB consists 1.5% patients of total extra-pulmonary TB cases. In India OPD basis incidence ranges between 0.1 to 0.9%, with no gender predilection and 18 to 54% Child involvement. In 1981, Beyt et al. proposed simplified scheme of classification which has gained wide acceptance.⁷

[A] Exogeneous:-

- 1) TB chancre
- 2) Warty TB or Tuberculosis verrucosa cutis (TVC)
- 3) Lupus Vulgaris (LV)

[B] Endogeneous:-

- 1) Scrofuloderma
- 2) Lupus Vulgaris
- 3) Tuberculous Gumma.

[C] Tuberculides:-

- 1) Lichen Scrofulosum (LS)
- 2) Papulonecrotic Tuberculid
- 3) Erythema Induratum
- 4) Erythema Nodosum

It is mostly diagnosed clinically, sputum analysis, culture on LJ medium, chest X-ray, PCR helps; sometimes poses diagnostic challenges. Histopathology is not pathognomic, but plays corroborative role in diagnosis especially in clinically challenging cases. Treatment consisting of antitubercular therapy (ATT) is the main basis and patient is treated like extra-pulmonary TB; but if required surgery is done in LV, TVC and LS in recalcitrant cases.⁸ Drugs are monitored for toxicities.

This is a study to measure incidence, classify clinically, know histopathological correlation, and assess the efficacy and response of treatment to different forms of cutaneous tuberculosis.

2. MATERIALS AND METHODS:-

During period of 10 years in Smt SCL hospital, Ahmedabad, Gujarat from 1st May 2004 to 1st May 2014; patients suspected of cutaneous TB having chronic granulomatous skin lesions and chronic ulcerative lesions who presented to Skin OPD was further investigated, and of all 175 got enrolled in our study regarding Cutaneous TB. Detailed history of 175 patients regarding age, sex, occupation, education, marital status, socioeconomic class taken. Family history of cutaneous/systemic tuberculosis and trauma history was also interrogated. Complete general and systemic examinations were carried out in addition to dermatological examination for evidence of tuberculosis elsewhere in the body. Smear from the affected area and sputum for acid-fast bacilli were carried out in each case. Routine haemogram with ESR, biochemistry profile, HIV-ELISA and VDRL, Mantoux test, histopathological examination, culture were performed. X-ray chest in all cases, sputum examination, and barium meal, barium swallow and ultrasonography in indicated cases were done. The patients were classified and treated as per schedule.

3. RESULT:-

175 were found to be suffering from cutaneous tuberculosis. 2,62,500 patients with skin diseases were seen in Skin OPD, therefore 0.15% cutaneous tuberculosis. The age group 3 to 60 years, where patients in 21-30 years comprised 43 (25%), 11-20 years comprised 39 (22%) of total patients. In 26 cases (15%) disease appeared before 10 years age. There were 105 (60%) male patients and 70 (40%) female patients giving sex ratio of 3:2. 144 patients (82%) were from poor socioeconomic class, facing overcrowding. Duration of disease varying 3 months to 5 years. After doing required investigations patients were diagnosed as TB and classified. Maximum cases were lupus vulgaris i.e. 63 (36%) followed by tvc and scrofuloderma in 56 (32%) and 49 (28%) respectively. 5 (3%) patients had erythema nodosum. 2 (1%) cases of orificial tuberculosis, one involving perianal region and other involving glans penis observed. We didn't come across papulonecrotic tuberculides or miliary tuberculosis.

Face and neck were affected in 63 (36%) patients; buttocks 35 (20%), trunk 28 (16%), legs in 22 (12.5%), foot 15 (8.5%), hand 12 (7%) each. 157 (90%) had single lesion, 18 (10%) had multiple lesions. Active tuberculosis in others viz. lung, bone, lymph nodes observed in 63 (36%) patients. 132 patients (75%) showed inflammatory papule followed by scarring at the site of BCG vaccination within 3-6 weeks, 43 patients (32%) did not show such response. Mantoux test was positive in 119 (68%), negative in remaining. Biopsy reports of 126 (72%) showed characteristic histopathological changes of tuberculosis. 49 cases (28%) had non-specific histopathology. All the patients

were negative for HIV.Diabetes was associated with 25(14%) patients;hypertension with 13(7%);pulmonary TB was associated in 7(4%)patients.All three diseases were found to be more common in Scrofuloderma.Disseminated disease was found more in unvaccinated patients and Scrofuloderma as compared to vaccinated and in other types.After establishing the diagnosis,patients were given ATT.

Currently,the treatment of all types of tuberculosis is by the directly observed treatment short course (DOTS) strategy,which is implemented by World Health Organization.⁹ This programme has been fully adapted by the Revised National Tuberculosis Control Programme of India.¹⁰For cutaneous tuberculosis, category III (2H₃ R₃ Z₃ + 4H₃ R₃)is recommended. In this category, Rifampicin (R-450 mg),Isoniazid (H-600 mg) and Pyrazinamide (Z-1500 mg) are administered for three days in a week for 2 months,followed by R-450 mg and H-600 mg given three days in a week for 4 months.In case of cutaneous tuberculosis with pulmonary TB,category I with four drugs is advised.Standard treatment protocol was followed and drugs were given under supervision.Patients were reviewed once weekly in 1st two months, then biweekly for next 2 months then monthly till next two months.Patients were given therapy taking in consideration the general health,extent of disease,patient compliance.Patients were observed for decreased size of induration,ulcer ,scaling, verrucosity,relapse and side effects of therapy.Patients showed significant clinical improvement and response with residual skin changes within 6months.The compliance and tolerability with DOTS was good.No relapse was observed in follow-up.

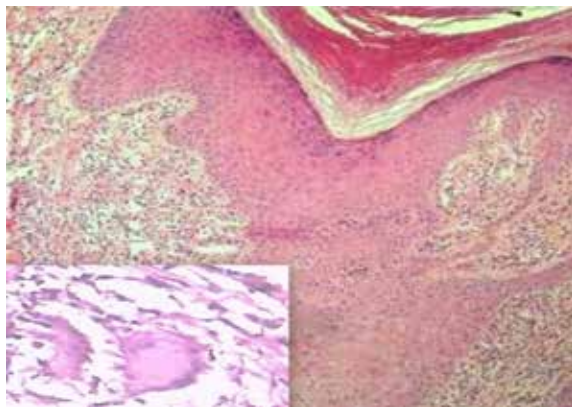


Figure3: Pseudoepitheliomatous hyperplasia with cell infiltrate in upper dermis(H and E stain, ×100) and Epithelioid granuloma with Langhans giant cell(H and E stain, ×400).

TABLE 1: Age distribution of the cases

Age group	LV (63)	TVC(56)	Scrofuloderma (49)
0-10	8	2	16
11-20	18	11	10
21-30	16	12	15
31-40	9	3	5
41-50	8	18	2
51-60	4	10	1

TABLE 2: Distribution of the involved sites

	LV	TVC	Scrofuloderma
Face & neck	36	3	24
Hand	-	12	-
Trunk	1	7	22
Legs	10	12	-
Buttocks	14	9	3
Foot	2	13	-

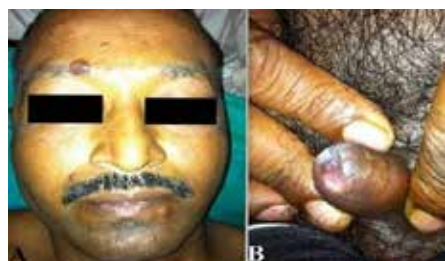

Figure1:Lupus vulgaris: soft erythematous nodule on face with ulcerative lesion on glans penis in same patient

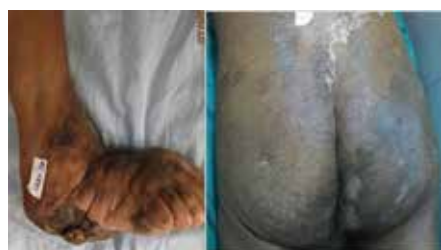

Figure2:Warty tuberculosis on sole, Scrofuloderma on buttock

TABLE 3: Clinical and Histopathological features

	LV	TVC	Scrofuloderma
Clinical features	Erythematous, well defined lesion with heal and scar in one region and activity in another region	Verrucous papule and plaque with perilesional erythema	Lymph node infection followed by swelling,rupture and ulcer and sinus tract formation with scarred healing
Histopathological features Granuloma and Infiltration	Epithelioid granuloma in upper dermis Lymphocytes and langerhans cell infiltrate	Pseudoepitheliomatous hyperplasia and acute infiltrate in upper dermis and tuberculoid granuloma in mid dermis	Granulomatous entire dermis,extensivecaseous necrosis
AFB bacilli	Difficult to detected	Rarely detected	Easily detected

4. DISCUSSION:-

Cutaneous tuberculosis is now rarely (0.1%) seen in Western countries but it is encountered commonly in developing countries 0.15% to 0.26% in various studies.¹¹⁻¹⁴In our study, we observed that incidence was 0.15%, with male preponderance like other studies,¹⁵ mainly in the younger age group, which was also noticed in the studies by Satyanarayan and Wong.¹⁶This was found to be in accordance with exposed areas being more often affected. Face being most common was also noticed by others.^{13,17}Practically no site was found to be spared. Lupus vulgaris was the commonest type of cutaneous TB in our study as observed in various other studies from India^{13,14} while in other study TVC was most common type.¹⁸We found TVC was next common to lupus vulgaris.

In our study, diabetes was associated with 14%; hypertension with 7%; pulmonary TB was associated in 4% patients. Wong and Banerjee also noticed an association with pulmonary tuberculosis^{18,19} while Restrepo noted an association with DM.¹⁹All the patients were negative for HIV while Decker et al. showed an association of HIV infection with tuberculosis.²⁰Carcinomatous change as reported in lupus vulgaris,²¹ was not recorded in the present study. The positivity of the Mantoux test has been reported from 68% to 100% in various studies¹² and our study compared well with their findings. In one study,¹² epidermal hyperplasia was observed in 41.2% cases of lupus vulgaris and all cases of TVC. Tuberculoid granulomas in dermis were reported in 70.6% cases of lupus vulgaris, 39.1% cases of scrofuloderma, and all cases of TVC, which were comparable to our study except granuloma not found in all cases of TVC. Like Lever, we also saw acid-fast bacilli in few biopsy reports.²²In one study,¹² epidermal hyperplasia was observed in 41.2% cases of lupus vulgaris and all cases of TVC. Tuberculoid granulomas in dermis were reported in 70.6% cases of lupus vulgaris, 39.1% cases of scrofuloderma, and all cases of TVC, which were comparable to our study except granuloma not found in all cases of TVC. Like Lever, we also saw acid-fast bacilli in few biopsy reports.²²All patients except 7 cases with pulmonary TB were treated with ATT category- III regimen, which gave a very good response. 7 cases with pulmonary tuberculosis, responded to Cat- I treatment of ATT. All followed up without relapse.

5. CONCLUSION:-

Cutaneous TB is caused by *Mycobacterium tuberculosis*. The most common type was lupus vulgaris and the most commonly affected sites were face and neck. Cutaneous TB may also be associated with diabetes and hypertension. The most commonly affected age group was the 21-30 years' group and all our cases were treated with ATT. As cutaneous TB sometimes reflects the presence of pulmonary tuberculosis and some cases of cutaneous TB misleading as diagnosis of other skin condition; its incidence should not be ignored.

REFERENCE

1. Vanessa Ngan. Vanessa Ngan. Cutaneous tuberculosis [Online]. 2003 [cited 25 Dec 2006]; [3 screens] Available from: URL: <http://www.dermnetnz.org/bacterial/tuberculosis.html> | 2. *Mycobacterium tuberculosis* [Online]. [cited 2008 Oct 8]; [3 screens] Available from: URL: http://en.wikipedia.org/wiki/Mycobacterium_tuberculosis | 3. Gopinathan R, Pandit D, Joshi J, Jerajani H, Mathur M. Clinical and morphological variants of cutaneous tuberculosis and its relation to mycobacterium species. *Indian J Med Microbiol*. 2001;19:193-6. | 4. Kumar B, Rai R, Kaur I, Sahoo B, Muralidhar S, Radotra BD. Childhood cutaneous tuberculosis: a study over 25 years from northern India. *Int J Dermatol*. 2001;40:26-32. | 5. Kumar B, Muralidhar S. Cutaneous tuberculosis: A Twenty-year prospective study. *Int J Tuberc Lung Dis*. 1999;3:494-500. | 6. Pillsbury DM, Shelley WB, Kligman AM. In: *Dermatology*. Philadelphia: WB Saunders; 1956. Systemic bacterial infection; pp. 499-540. | 7. Beyt BE, Ortbals DW, Santa-Cruz DJ, Kobayashi GS, Eisen AZ, Medoff G. Cutaneous mycobacteriosis: analysis of 34 cases with a new classification of the disease. *Medicine*. 1981;60:95-109. | 8. Barbagallo J, Tager P, Ingleton R, et al. Cutaneous tuberculosis: diagnosis and treatment. *Am J Clin Dermatol*. 2002;3(5):319-328. | 9. World Health Organisation. Treatment of tuberculosis: Guidelines for national programmes. WHO; 1993. p. 1-43. | 10. RNTCP at a glance. Available from: <http://www.tbindia.org/RNTCP.asp> | 11. Kumar B, Kaur S. Pattern of cutaneous tuberculosis in North India. *Indian J Dermatol Venereol Leprol*. 1986;52:203-7. | 12. Sehgal VN, Srivastava G, Khurana VK, Sharma VK, Bhalla P, Beohar PC. An appraisal of epidemiologic, clinical, bacteriologic, histopathologic and immunologic parameters in cutaneous tuberculosis. *Int J Dermatol*. 1987;26:521-6. | 13. Acharya KM, Ranpara H, Dutta R, Mehta B. A clinicopathological study of 50 cases of cutaneous tuberculosis in Jamnagar district. *Indian J Dermatol Venereol Leprol*. 1997;63:301-3. | 14. Patra AC, Gharami RC, Banerjee PK. A profile of cutaneous tuberculosis. *Indian J Dermatol*. 2006;51:105-7. | 15. Kumar B, Rai R, Kaur I, Sahoo B, Muralidhar S, Radotra BD. Childhood cutaneous tuberculosis: a study over 25 years from northern India. *Int J Dermatol*. 2001;40:26-32. | 16. Satyanarayan BV. Tuberculoderma - A brief review together with statistical analysis and observations. *Int J Dermatol*. 1963;29:25-30. | 17. Kumar B, Rai R, Kaur I, Sahoo B, Muralidhar S, Radotra BD. Childhood cutaneous tuberculosis: A study over 25 years from northern India. *Int J Dermatol*. 2001;40:26-32. | 18. Wong K, Lee KP, Chiu SF. Tuberculosis of the skin in Hong Kong - A review of 160 cases. *Br J Dermatol*. 1968;80:424-9. | 19. Banerjee BN. Tuberculosis of the skin and its relation with pulmonary tuberculosis. *Indian J Dermatol*. 1957;2:69. | 20. Decker CF, Lazarus A. Tuberculosis and HIV infection. How to safely treat both disorders concurrently. *Postgrad Med*. 2000;108:57-60. 65-8. | 21. Betti R, Tolomio E, Vergani R, Crosti C. Squamous cell carcinoma occurring after lupus vulgaris. *Hautarzt*. 2002;53:118-20. | 22. Lever WF, Schaumburg Lever G. 7th ed. Philadelphia JB Lippincott; 1990. *Histopathology of the Skin*; pp. 326-32. |