


Post Cabg(Coronary Artery Bypass Graft) Surgical Site Infection by Nocardia- a Case Report



Medical Science

KEYWORDS :

G R Manjunath

Assistant Professor Department of General Surgery BGS GLOBAL INSTITUTE OF MEDICAL SCIENCES & HOSPITAL, BANGALORE.

Shivanand Reddy K.V

Post graduate Department of General Surgery, JSS University, Mysore.

Manjunath Shenoy

Professor of Surgery, JSS University, Mysore.

M N Sumana

Professor of Microbiology, JSS University, Mysore.

ABSTRACT

A 65 year old male patient presented with history of incomplete healing of wound on the Chest wall for 2 months after CABG surgery. He is a known Diabetic and a Hypertensive under good control. A clinical diagnosis of surgical site infection was made and the discharge sent for ZN staining, gram staining, Culture and sensitivity revealed Nocardia and was treated with cotrimoxazole and wound healed in 1 month.

INTRODUCTION:

Surgical site infection is the second most common nosocomial infection. Wound infection is an important cause of morbidity and occasional mortality after coronary artery bypass graft surgery (CABG). Common organisms encountered are *Staphylococcus aureus*, *Staphylococcus epidermidis*, *Enterococcus* species, *Streptococcus pneumoniae*, and *Pseudomonas aeruginosa*¹. In certain cases of delayed CABG wound healing, *Candida* species and occasionally rapidly growing atypical Mycobacterial species are isolated. Only one case of *Nocardia asteroides* Mediastinitis complicating Coronary Artery Bypass (CABG) Surgery has been reported in the literature available by Susan Verghese et al from the US¹. *Nocardia* occurs worldwide and annual incidence is 0.375 cases per 100000 persons as estimated by three continents- North America, Europe and Australia. This case report may be following transcutaneous inoculation during CABG surgery from the hospital environment or solution. Because of the rarity of *Nocardia* causing sternal wound infection after CABG surgery, it is worth while reporting this case.

Case report:

A 65 year old male patient reported to Surgical OPD, with history of incomplete healing of wound on the Chest wall for more than 2 months duration after CABG surgery. He underwent surgery 2 ½ months ago. He is a known Diabetic and a Hypertensive under good control. On examination, wound dehiscence was noticed at the lower end of the CABG surgical scar with scanty discharge. The discharge was sent to Microbiology lab for Culture and sensitivity.

The sample was inoculated on to MacConkey agar and blood agar, and incubated aerobically at 37 degree Celsius over night. A gram stained smear was also prepared from the sample and observed under the microscope. It showed gram positive branching filaments. The smear was completely decolorized with alcohol and re-stained with modified Zeihl-Nelson's stain using 1% H₂SO₄ as decolourizer and observed under the microscope. It showed pink acid fast branching thin filaments and tentatively identified as *Nocardia* species.

The culture plates did not show any growth after overnight incubation and they were further incubated for another day. Next day when the plates were examined, MacConkey's agar showed no growth but blood agar showed growth of white, small, dry colonies (Fig 1). Culture smear made showed gram positive thin branching filaments. Modified Zeihl-Neelson's stain using 1% H₂SO₄ as decolourizer showed pink acid fast filamentous branching bacteria (Fig-2). The bacteria grown were identified as

Nocardia species. The biochemical reactions showed following results. It failed to hydrolyze casein, xanthine and tyrosine and was urease negative. It was identified as *Nocardia asteroides*. The sensitivity of the organism was done on Mueller-Hinton blood agar. It was sensitive to cotrimaxazole, penicillin, amoxicillin, gentamycin, erythromycin, amikacin, ciprofloxacin and ofloxacin. A repeat sample collected from the patient to confirm also yielded the growth of same organism. The patient was started on Trimethoprim (20mg/kg) and sulfamethoxazole (100mg/kg) each day in two divided doses for 15 days and later the dosage reduced to 5mg/kg and 25mg/kg respectively for 4 months. After 15 days of treatment the wound showed signs of healing and after a month it was completely healed.

Discussion:

Post operative wound infections like sternal wound infections, donor site infections and mediastinitis form serious complications after cardiac surgery. Common causes of post operative wound infection include *Staphylococcus aureus* both MRSA (Methicillin resistant *Staphylococcus aureus*) and MSSA (Methicillin sensitive *Staphylococcus aureus*), *Staphylococcus epidermidis* both MSSE (Methicillin sensitive *Staphylococcus epidermidis*) and MRSE (Methicillin resistant *Staphylococcus epidermidis*)¹. Other less common causes could be *Enterococcus*, *Pseudomonas*, *Acinetobacter* and members of *Enterobacteriaceae*.

Bhatia JY et al from Hinduja hospital, Mumbai have studied Six hundred and fifteen patients. Of these 116 (18.86%) developed SSI, involving sternum 75%, leg 21.3%, and forearm sites 3.44%. Organisms isolated at sternum site were MSSE, MRSA, and MRSE¹.

Softah, MD et al have reported post CABG wound infection due to *Staphylococcus aureus* in 33% of their patients and *Staphylococcus epidermidis* in 31% of their patients and mixed infections in 11.7% of patients².




Fig 1. showing dry white colonies on blood agar.

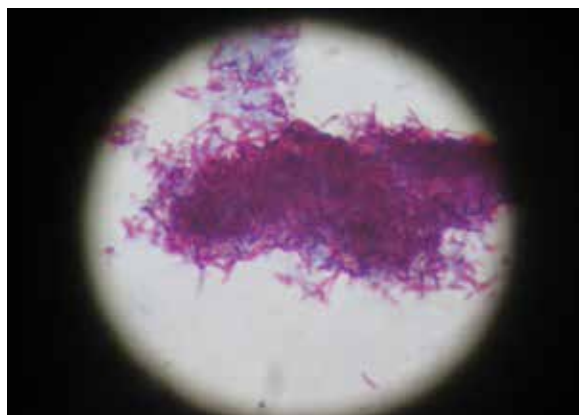


Fig 2. Showing branching acid fast filamentous bacteria

Preeti N. Malani, et al from University of Michigan Medical School, Ann Arbor, Michigan have reported that *Candida* species are an uncommon cause of sternal wound infections. Mediastinitis due to *Candida* is a rare but serious complication that usually occurs in the first few days to weeks after the surgical procedure and is associated with a mortality rate of >50%. They report on a series of 11 patients who developed deep sternal wound infections due to *Candida albicans*. These infections were characterized by a chronic, indolent, and recurrent course³.

Susan Verghese et al have reported a case of *Nocardia asteroides* Mediastinitis Complicating Coronary Artery Bypass Surgery⁴.

Thaler F et al have reported Mediastinitis due to *Nocardia asteroides* after Cardiac transplantation⁵.

REFERENCE

1. Bhatia JY, Pandey K, Rodrigues C, Mehta A, Joshi VR. Rheumatology, PD Hinduja National Hospital and Medical Research Centre, Mumbai - 400 016, India. "Postoperative wound infection in patients undergoing coronary artery bypass graft surgery: a prospective study with evaluation of risk factors". *Indian J Med Microbiol.* 2003 Oct-Dec;21(4):246-51. | 2. A. Softah, MD; A. Bedard, MD; P. Hendry, MD; R.G. Masters, MD; W. Goldstein, MD; M. Brais, MD; W. Keon, MD. WOUND INFECTION IN CARDIAC SURGERY. *Annals of Saudi Medicine*, Vol 22, Nos 1 -2, 2002 P105-07 | 3. Preeti N. Malani, Shelly A. McNeil, Suzanne F. Bradley, and Carol A. Kauffman. University of Michigan Medical School, Ann Arbor, Michigan, *Candida albicans* Sternal Wound Infections: A Chronic and Recurrent Complication of Median Sternotomy Clin Infect Dis. (2002) 35 (11): 1316-1320. doi: 10.1086/344192. | 4. Susan Verghese*, VM Kurian**, CF Maria***, P Padmaja***, SJ Elizabeth***, KM Cherian+ "Nocardia asteroides Mediastinitis Complicating Coronary Artery Bypass Surgery". *JAPI • VOL. 51 • OCTOBER 2003* | 5. Thaler F, Gotainer B, Teodori G, Dubois C, Loirat P. Mediastinitis due to *Nocardia asteroides* after cardiac transplantation. *Intensive Care Med* 1992;18:127-8.