

Pleuropulmonary Blastoma in an Adult Patient:a Case Report



Medical Science

KEYWORDS :

NASIM MONDAL

3rd year resident doctor, Department of pulmonary medicine, B.J. MEDICAL COLLEGE, AHMEDABAD

KEYUR PATEL

3rd year resident doctor, Department of pulmonary medicine, B.J. MEDICAL COLLEGE, AHMEDABAD

NILESH PARMAR

2nd year resident doctor, Department of pulmonary medicine, B.J. MEDICAL COLLEGE, AHMEDABAD

SUJAL PATEL

1st year resident doctor, Department of pulmonary medicine, B.J. MEDICAL COLLEGE, AHMEDABAD

ABSTRACT

Pleuropulmonary blastoma (PPB) typically presents in young children, most younger than 5 years, as dysontogenetic neoplasm. It has poor prognosis with three different subtypes: cystic (type I), combined cystic and solid (type II) and solid (type III). Our patient was admitted with dyspnea and was diagnosed at 23 years of age. He was evaluated with bronchoscopic guided biopsy and diagnosed as PPB by histopathology and IHC. Immunohistochemical studies showed vimentin positive. Complete resection is proposed to be one of the important prognostic factors in literature.

INTRODUCTION

Pleuropulmonary blastoma (PPB) is a rare pulmonary tumor usually observed in childhood under the age of 6 years. In 1988, Manivel et al. described PPB in children as an entity that was distinct from the biphasic epithelial-stromal morphology of the classic adult type, and termed as PPB, which includes tumors that previously have been described as pulmonary blastoma, pulmonary sarcomas, embryonal sarcoma, pulmonary rhabdomyosarcoma. These tumors are rare dysontogenetic childhood tumors. The primitive sarcomatous features of the tumor are analogous to those of other dysontogenetic or dysembryonic tumors, such as Wilms tumor, hepatoblastoma, neuroblastoma, and embryonic rhabdomyosarcoma. PPB was classified into three groups by Dehner in 1995 as cystic (type I), mixed (type II), or solid (type III). Type I has a more favorable prognosis than type II and III. PPB is observed rarely in adults and there is no optimal treatment regimen that has been defined yet. In this report, a case of PPB is presented and reviewed briefly.

CASE REPORT

A 23 years-old male patient with no history of smoking referred to our out patient clinic with complaints of dyspnea and irritative cough that had been present for the previous 3-4 months. He had never experienced these symptoms before. He described the cough as constant and non-productive with no hemoptysis. He had no fever, weight loss, wheezing or chest pain within this time period. He is current tobacco user. He had no known chemical or occupational exposure. Although there were no pathologic findings in her physical examination, a routine evaluation was initiated, which included basic blood investigations, chest xray and CT thorax. His chest radiography (Figure 1) revealed a smooth-contoured opacity with a 9-10 cm diameter in the left upper zone. Computed tomography of the thorax (Figure 2) revealed a well defined pleural based hypodense lesion of variable size noted on left side which on post contrast study shows moderate heterogeneous enhancement, largest lesion measures approximately 10cm upto mediastinum. Mild free fluid is seen on left pleural cavity. There was no distant metastasis. He was referred for bronchoscopic guided biopsy.

Pathological examination revealed a brownish bits of tissue showing infiltrate of small cell tumor with sheets of uniform sized small tumor cells with dark stained nuclei and scanty cytoplasm. There is plenty of vascularity and low mitotic activity.

some rosette like structures are seen. In the immuno-histochemistry of the tissue bits was positive for vimentin, BCL-2 and weakly positive for NSE. IHC was negative for CK, AE1, CD99. These pathological examinations confirmed the diagnosis pulmonary blastoma. He was subsequently referred to cardiothoracic surgeon for resection.

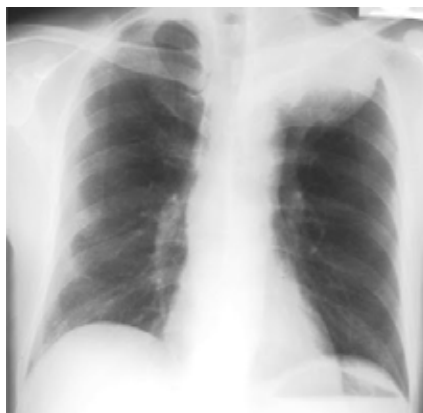

Figure-1 : smooth-contoured opacity with a 9-10 cm diameter in the left upper zone

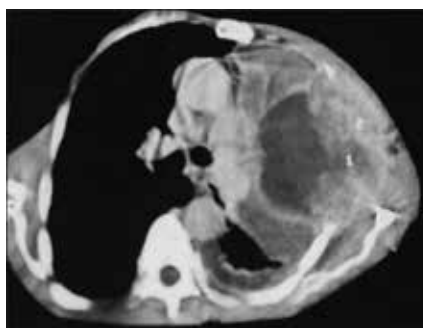


Figure 2: Computed tomography of the thorax revealed a well defined pleural based hypodense lesion of variable size noted on left side.

DISCUSSION

PPB is mainly distinct from classic adult-type pulmonary blastoma by the absence of malignant epithelial elements. In pediatric patients the lesion is a true dysembryonic neoplasm of thoracopulmonary mesenchyma, without malignant epithelial cells. Pulmonary blastoma with carcinomatous elements has only been described in adults. Engagement of parietal pleura and diaphragm can often be observed in type II and III, which have poorer prognoses. Type II is similar to Wilms tumor morphologically and therefore, it is sometimes incorrectly called "extra-renal Wilms tumor". Three pathologic types based on gross and microscopic features have been defined in the following manner: type I is a purely cystic lesion that may be mistaken clinically and pathologically for a congenital lung cyst; type II is a cystic and solid lesion with areas of thickening and/or nodularity with or without a relationship to the cysts; and type III is a purely solid tumor consisting of friable, gelatinous to mucoid, lobulated tissue often accompanied by hemorrhage and necrosis. In immunohistochemical studies; the most common findings were vimentin positivity and S-100 protein positivity in cartilaginous foci positivity and desmin positivity in areas with rhabdomyoblastic differentiation. The only typical characteristic of tumor is vimentin positivity. Although surgery can yield positive results in type I lesions, surgical success is rather more limited in type II and III. The most important prognostic factor is the total excision of the mass with clear margins. Postoperative radiotherapy is recommended in cases with incomplete resections. Cyclophosphamide, doxorubicin, ifosfamide, etoposide, vincristine are commonly used agents in the treatment of PPB. The most common combination is vincristine, dactinomycin, cyclophosphamide (VAC) regimen. This treatment should be reserved for sarcomatous lesions in particular. Toxicities of the regimen were consisted of Grade 3/4 leukopenia in two cycles with one febrile neutropenic episode. Although metastases may not be present at diagnosis in these patients, brain, liver and bone metastases can develop in addition to local recurrence at the follow-up. Recurrence and distant metastases, most commonly in the central nervous system, can be observed in approximately half of the patients. The poor prognostic factors of the disease are origin of cystic pulmonary disease, tumor size exceeding 5 cm, and mediastinal and/or pleural invasion.

CONCLUSION

PPB is a rare lung cancer group mostly detected in the childhood. Our case is an interesting one as it is seen in adulthood. Surgical excision with clear margins seems to be cornerstone of the treatment of this tumor. Efficacy of the adjuvant chemotherapy should be determined in large case series especially in patients with type II-III disease.

REFERENCE

1. Wright JR. Pleuropulmonary Blastoma. A case report documenting transition from type I (cystic) to type III (solid). *Cancer* 2000;88:2853-8.
2. Manivel JC, Priest JR, Watterson J, et al. Pleuropulmonary blastoma. The so-called pulmonary blastoma of childhood. *Cancer* 1988;62:1516-26.
3. Hill DA, Sadeghi S, Schultz MZ, et al. Pleuropulmonary blastoma in an adult. An initial case report. *Cancer* 1999;85:2368-74.
4. Dehner LP, Watterson J, Priest J. Pleuropulmonary blastoma: a unique intrathoracic-pulmonary neoplasm of childhood. *Perspect Pediatr Pathol* 1995;18:214-26.
5. Yang P, Hasegawa T, Hirose T, et al. Pleuropulmonary blastoma: fluorescence in situ hybridization analysis indicating trisomy 2. *Am J Surg Pathol* 1997;21:854-9.
6. Priest JR, Watterson J, Strong L, et al. Pleuropulmonary blastoma: A marker for familial disease. *J Pediatr* 1996;128:220-4.
7. Priest JR, McDermott MB, Bhatia S, et al. Pleuropulmonary blastoma. A clinicopathologic study of 50 cases. *Cancer* 1997;80:147-61.
8. Picaud JC, Levrey H, Bouvier R, et al. Bilateral cystic pleuropulmonary blastoma in early infancy. *J Pediatr* 2000;136:834-6.
9. Dehner LP. Pleuropulmonary blastoma is the pulmonary blastoma of childhood. *Semin Diagn Pathol* 1994;11:144-51.
10. Novak R, Dasu S, Agamanolis D, et al. Trisomy 8 is a characteristic finding in pleuropulmonary blastoma. *Pediatr Pathol Lab Med* 1997;17:99-103.
11. Parsons SK, Fishman SJ, Hoorntje LE, et al. Aggressive multimodal treatment of pleuropulmonary blastoma. *Ann Thorac Surg* 2001;72:939-42.
12. Lallier M, Bouchard S, Di Lorenzo M, et al. Pleuropulmonary blastoma: A rare pathology with an even rarer presentation. *J Pediatr Surg* 1999;34:1057-9.
13. Indolfi P, Casale F, Carli M, et al. Pleuropulmonary blastoma. Management and prognosis of 11 cases. *Cancer* 2000;89:1396-401.