Volume : 5 | Issue : 9 | September 2016 • ISSN No 2277 - 8179 | IF : 3.508 | IC Value : 69.48

Original Research Paper

Gangrenous Torsed Meckel's Diverticulum:a Rare Presentation of Small Bowel Obstruction

Medical Science

KEYWORDS : Meckel's diverticulum, gangrenous, intestinal obstruction, vitello intestinal duct.

Dr. Patel Samarth R.	Third year post graduate resident, MS general surgery, Surat municipal institute of medical education and research
Dr. Harish Chauhan	associate professor, Surat municipal institute of medical education and research
Dr. Yagnesh vaghani	assistant professor, Surat municipal institute of medical education and research
Dr. Aanchal Datta	3rd year pg resident, Surat municipal institute of medical education and research
Dr. jyotirekha desai	HOD and professor, Surat municipal institute of medical education and research

ABSTRACT

Meckel's diveriticulum is the persistence of proximal part of vitello-intestinal duct. It is a common congenital anomaly of the small bowel. We report an extremely rare case of gangrenous meckel's diverticulum causing small bowel obstruction. A 23 year old male patient presented to our emergency department with history of vomiting, abdominal pain and distension of abdomen since 4 days. On exploratory laparotomy, minimal free fluid was found in pelvis and right iliac fossa with dilatation of jejunum and proximal part of ileum. Meckel's diveritculum was seen attached to mesentry of small bowel and twisted around a loop of ileum. Resection anastomosis of small bowel including meckel's diverticulum was performed. It is an extremely rare complication of meckel's diveriticulum.

INTRODUCTION

Meckel's diverticulum is a persistence of proximal part of vitello-intestinal duct. The "RULE OF 2" applies to meckel's diveriticulum:

Found in 2% population

Seen at distance usually 2 feet proximal to ileocaecal junction

Approximately 2 inches in length

Common complications of meckel's diverticulum include :

Inflammation

Bleeding

Perforation

Intestinal obstruction

We report an extremely rare case of gangrenous meckel's diverticulum causing intestinal obstruction.

CASE REPORT:

A 23 year old male patient comes to our emergency department with history of vomiting, abdominal pain and distension of abdomen. On clinical examination tenderness present over right iliac fossa, umbilical region and hypogastric region. Patient is haemodynamically stable. Blood counts are all within normal limits. No history of similar episodes in the past and no past operative history. X ray abdomen standing showed multiple air fluid levels. (figure 1). On USG abdomen: features of small bowel obstruction were present. On ryle's tube insertion around 800 cc bilious content was drained overnight. Fluid resuscitation was done. Plan for laparotomy was made in morning. On exploration there was 300-400 ml of contamination (turbid free fluid) in pelvis and right iliac fossa. Jejunum and proximal ileum was dilated. On tracing, a gangrenous meckel's diveritculum was seen attached to the mesentry of small bowel and twisted around a loop of ileum (figure 2). Resection and ileo-ileal anastomosis of small bowel including meckel's diverticulum was performed. Biopsy report suggestive of : specimen labeled as meckel's diverticulum shows changes of ischemic enteritis. post operative recovery was uneventful and patient was discharged on 12th post operative day.

FIGURE 1: X ray abdomen standing showing features suggestive of small bowel obstruction.

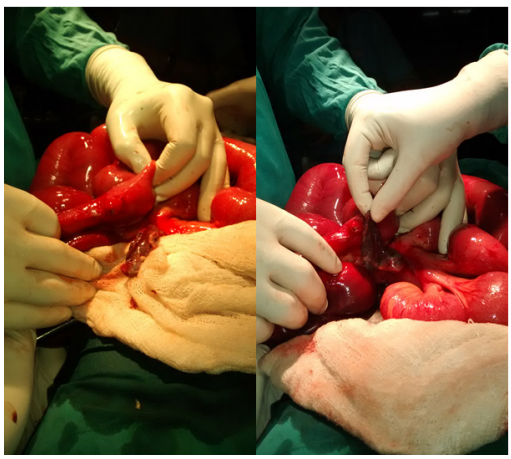

FIGURE 2: Gangrenous meckel's diverticulum causing small bowel obstruction with attachment of meckel's diver-

Volume : 5 | Issue : 9 | September 2016 • ISSN No 2277 - 8179 | IF : 3.508 | IC Value : 69.48

ticulum with mesentry of small bowel by a band.

DISCUSSION:

Meckel's diverticulum is a persistence of proxmial part of vitello-intestinal duct. It occurs on anti-mesentric border of ileum and at 2 feet distance proximal to ileo-caecal junction. It is a true diverticulum. Complication rate average 4%. The most common complication in adults is inflammation and in children it is bleeding. Diverticulum, littre's hernia and peritoneal bands are often rare causes of small bowel obstruction. Gangrene of meckel's diverticulum is a rare phenomenon, and even rare if it is secondary to torsion. When patient comes with diverticulitis, often it is confused with appendicitis. No specific diagnostic tool is available for meckel's diverticulitis. In patients with doubtful diagnosis, laparoscopy is saef and effective modality for diagnosis and therapeutic purpose. Ideal treatment for meckel's diverticulum is wedge resection of bowel including meckel's diverticulum. Resection and anastomosis is reserved for complicated cases.

CONCLUSION:

Here we report a rare cause of complicated meckel's diverticulum. Preoperative diagnosis is difficult but outcome of patient is excellent.

REFERENCES:

1. Current management of meckel's diverticulum.Adv surg. 1996;29:207-14 *Cullen J.J., Kelly KA.* [pubmed]
2. Gangrene of Meckel's diverticulum secondary to axial torsion:a rare complication. Am J Gastroenterol. 1998;93:1373-5 *Malhotra S., Roth DA, Gouge TH, Hofstetter SR, Sidhu G, Newman E.* [pubmed]
3. Axial torsion and gangrene of a giant meckel's diverticulum mimicking acute appendicitis. J Pak Med Assoc. 2009;59:408-9 *Kiyak G, Ergul E, Sarikaya SM, Kusdemir A.I* [pubmed]
4. Laparosopic management of perforated meckel's diverticulum in adult. Int J Med Sci. 2012;9:243-7 *Ding Y, Zhou Y, Ji Z, Zhang J, Wang Q.* [PMC free articles][pubmed]
5. Meckel's diverticulum causing intestinal obstruction. Am J Gastroentero. 2001;96:3426-7 *Prall RT, Bannon MP, Bharucha AE.* [pubmed]
6. Axial torsion and gangrene of a giant meckel's diverticulum . J Gastrointentin Liver Dis. 2006;15:67-8 *Limas C, Seretis K, Soultanidis C, Anagnostoulis S.* [pubmed]
7. Intestinal obstruction caused by torsed gangrenous meckel's diverticulum encircling terminal ileum. World J Gastroentero Surg. 2011;3:106-9 *Cartanese C, Petitti T, Marinelli E, Pignatelli A, Martignetti D, Zuccarino M et al* [PMC free articles][pubmed]
8. Giant meckel's diverticulum with necrosis due to axial torsion. Rev Col Gasteroenterol. 2010;25:298-400 *Ruiz VA, Camacho LA, Diaz DC*
9. Meckel's diverticulum:a 10 year experience. Am surg. 1997;63:354-5 *Arnold JF, Pellicane JV.* [pubmed]
10. Gangrenous Meckel's diverticulum causing acute intestinal obstruction in an adult. ANZ J Surg. 2008;78:1046-7 *Sharma RK, Jain VK, KAmboj S, Murari K.* [pubmed]