


# A COMPARISON BETWEEN USB ENDOSCOPIC CAMERA MOUNTED MCCOY LARYNGOSCOPE AND CONVENTIONAL MACINTOSH LARYNGOSCOPE AIDED ENDOTRACHEAL INTUBATION



## Anaesthesiology

**Dr. Luqman  
Muhammed M**

Assistant professor, Department of Anaesthesiology, Karuna Medical College, India.

**\*Dr. Devadas P**

Professor, Department of Anaesthesiology, Karuna Medical College, India.

\*Corresponding Author

## ABSTRACT

The Macintosh curved blade laryngoscope is the standard equipment for endotracheal intubation. Video laryngoscopes provide an excellent and magnified view of larynx and adnexa. Commercial video laryngoscopes are expensive which acts as a limitation for routine use. We prepared an inexpensive version of video laryngoscope by using an USB endoscope camera and attaching it to McCoy laryngoscope blade and a personal computer. McCoy laryngoscopes have lever-tip for anterior displacement of the epiglottis, vallecula and epiglottis in difficult intubation. We evaluated between custom made video laryngoscope and Macintosh laryngoscope aided endotracheal intubation for success of intubation, overall duration, POGO score, intubation difficulty score and ease of intubation

## KEYWORDS

Custom made video laryngoscope, Macintosh, McCoy, POGO Score, USB endoscope camera

## INTRODUCTION

Endotracheal intubation is required in providing safe general anaesthesia and is an essential skill for all anaesthesiologists. Even in the expert hands there is failure to intubate the trachea. Failure to successfully intubate the trachea remains a leading cause of morbidity and mortality in anesthetic and emergency setting<sup>(1-6)</sup>. In difficult airway the Macintosh laryngoscopes (conventional) alone is not sufficient, so several modifications of it have come into practice.

McCoy laryngoscope is modification of the standard Macintosh laryngoscope blade to facilitate tracheal tube placement in cases of difficult visualization of the larynx<sup>7</sup>. This blade offers the unique advantage, of a hinged blade tip, controlled by a lever on the handle of the laryngoscope which allows elevation of the epiglottis while decreasing the overall laryngoscopic elevation or levering movement required<sup>7</sup>. McCoy laryngoscope blades, does not require any special training in its use and will prove useful for both routine intubations as well as those which may be difficult and associated with an anterior larynx<sup>7</sup>.

The Digital Revolution has brought new technology to the practice of tracheal intubation. The first device commercially available device of this kind was the GlideScope in the year 2000. Several manufacturers have developed video laryngoscopes which employ digital technology such as the Complementary metal-oxide-semiconductor active pixel sensor (CMOS APS) to generate a view of the glottis so that the trachea may be intubated. The KARL STORZ C-MAC Video Laryngoscope and the Glidescope video laryngoscope are examples of such a device.

In spite of all the technological advancements the cost of these devices are a major drawback, they are expensive. So to overcome that and to provide technology at an affordable cost we came across an article-Inexpensive video-laryngoscopy guided intubation using a personal computer: initial experience of a novel technique<sup>8</sup>. A custom device easily assembled using an USB endoscopic camera, a conventional McCoy laryngoscope blade size 4, and a laptop was used. (can be connected to an android smartphone also)

This endoscopy is a true plug and play driver installed, convenient detection equipment with 5.5mm camera head a new electronic detection product, which can capture the image, to the android phone and computer in real time video and photo, storage, printing or upload to the internet. The inspection camera makes use of optoelectronic technology to investigate hard to reach area. The main advantages are small in size and the diameter is only 5.5mm with high resolution imaging, waterproof camera, waterproof wire, endoscope camera head, high resolution with CMOS camera and 6 LED light is adjustable for photo shooting and video recording. Waterproof level: IP 67 photo shooting and video recording. Pixel: VGA 300k resolution: 640 x 480 capture resolution: up to 1024 x 720 (VGA), 30 fps. Wide visual view angle: 67 degrees and Focal distance: 3cm

## Materials and Method

After approval from Ethical Committee and written informed consent, 50 adult ASA grade I-II patients undergoing elective surgery requiring tracheal intubation as part of anaesthesia were selected. Patients with increased risk of pulmonary aspiration, history of difficult intubation, or anticipated airway difficulties were excluded.

They were randomly assigned to two groups based on the device used for laryngoscopy by lottery method. In group B patients Macintosh laryngoscope was used, in group A custom made video laryngoscope on McCoy blade was used.

Patients were premedicated with midazolam 0.025mg/kg, ondansetron 0.15mg/kg, and fentanyl 2mcg/kg body weight intravenously. Anaesthetic technique used comprising of pre oxygenation with 100% O<sub>2</sub> for three minutes, induction with propofol 2mg/kg i.v. neuromuscular blockade was achieved by using succinylcholine 2 mg/kg.

Laryngoscopy was performed one min after succinylcholine administration and intubation was carried out depending on the group to which the patient was assigned. After achieving best possible view of the glottis, Cormack-Lehane grading<sup>9</sup> (grade 1-4) and the percentage of glottic opening (POGO) scoring was done (0 to 100%, 100 = full view of glottis from anterior commissure to the inter-arytenoid notch, 0 = even inter-arytenoid notch is not seen). If proper glottic view for intubation was not seen to the viewers, manipulations were done accordingly.

The endotracheal cuffed tube of appropriate size (7.0 and 8.0mm internal diameter for women and men, respectively) was introduced into the trachea under direct vision. After laryngoscopy and intubation the breathing circuit was connected. Proper ventilation was confirmed by chest auscultation and capnography. Once the intubation was complete, lungs were mechanically ventilated during the procedure and anaesthesia was maintained using nitrous oxide with oxygen and sevoflurane (1.5-2%).

If the first intubation attempt failed, a next attempt was made after mask ventilation. In each

Parameters	McCoy video laryngoscope	Macintosh laryngoscopes
Male:female	13:12	14:11
Age (mean±SD)	35.28±12.56	37.96±8.61
MP I/II/III/IV	12/8/3/2	11/9/3/2
Weight (mean±SD)	61.56±7.57	65 ±9.64
ASA grade I	20 (80%)	17 (68%)
ASA grade II	5 (20%)	8 (32%)

group, tracheal intubation was considered a failure if it could not be accomplished in three attempts. All intubations were performed by an experienced anaesthesiologist. The number of intubation attempts, the number of optimization manoeuvres required (use of stylet, laryngeal manipulations) to aid tracheal intubation, the duration of successful intubation attempt (defined as the time from insertion of the laryngoscope to confirmation of intubation by capnography), and the intubation success rate were recorded.

The intubation difficulty score<sup>10</sup> (IDS 0 = easy, IDS 1-5 = slight difficulty, IDS >5 = major difficulty in intubation) was calculated as primary outcome. Secondary points were the time taken for laryngoscopy and intubation and the rate of successful placement of endotracheal tube into trachea. The incidence of oesophageal intubation, mucosal trauma, or dental injury was recorded. The haemodynamic variables like heart rate (HR), ECG, oxygen saturation (SpO<sub>2</sub>), and mean arterial pressure (MAP) were recorded at the baseline, post induction, just after tracheal intubation and at 1, 3, 5 and 10 min post intubation. Any episode of haemodynamic instability was noted.

### Statistical analysis:

Statistical analysis was done by chi-square test and Analysis of variance (ANOVA). The qualitative data between two groups were compared using the Chi-square test. Normally distributed data was compared using analysis of variance (ANOVA). P value < 0.05 was considered statistically significant.

## RESULTS

Table 1: Demographic data, mallampatti assessment and ASA grading

The groups were similar with respect to demographic data and ASA physical status (Table 1).

	McCoy video laryngoscope custom made			Macintosh laryngoscopes			p-value
	N	mean	SD	n	mean	SD	
Intubation time taken (in seconds)	25	26.92	± 5.03	25	40.64	± 5.7	<0.001

Table 2: Time taken for intubation

The overall duration of successful tracheal intubation was shorter in the custom made video McCoy laryngoscope group 26.92 (± 5.03) seconds versus 40.64 (± 5.7) seconds in the Macintosh group, statistically significant (p-value<0.001). (Table 2)

Figure: 1 Ease of intubation

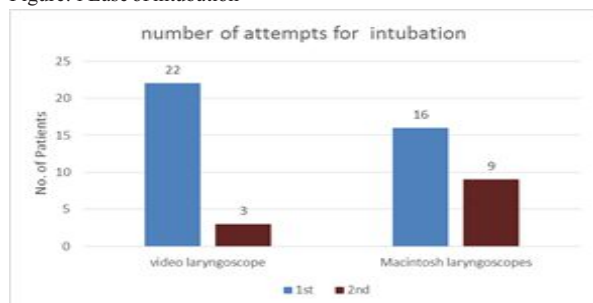


Table 3: intubation attempts

Intubation attempts	video laryngoscope	Macintosh laryngoscopes	p-value
1st	22 (88%)	16 (64%)	0.095
2nd	3 (12%)	9 (36%)	

Overall successful tracheal intubation was 100% (25 patients) in the McCoy Video laryngoscope group and (25 patients) in the Macintosh group. 1st attempt was 88% in video laryngoscope compared to 64% in curved blade. 12% required a second attempt in video laryngoscope while 36% in Macintosh group. (figure:1 & table:3)

Figure: 2 Intubation difficulty score (IDS)

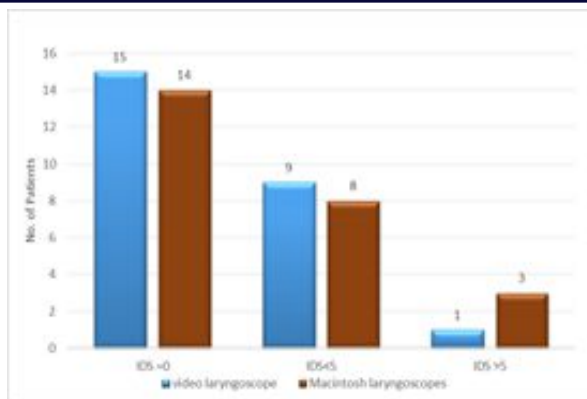


Table 4: Intubation difficulty score (IDS)

IDS score	McCoy video laryngoscope	Macintosh laryngoscopes	p-value
IDS=0	15 (60%)	14 (56%)	0.579
IDS<5	9 (36%)	8 (32%)	
IDS>5	1 (4%)	3 (12%)	

Fifteen patients (60%) had easy intubation (IDS score = 0) in the video laryngoscope group as compared to 14 patients (56%) in the Macintosh group. One patient (4%) was in score of >5 in video laryngoscope group compared to 3 patients (12%) in macintosh group (Figure 2 & Table 4).

Figure: 3 Cormack and Lehane score

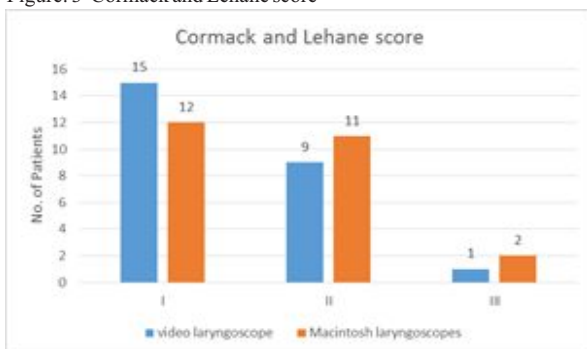
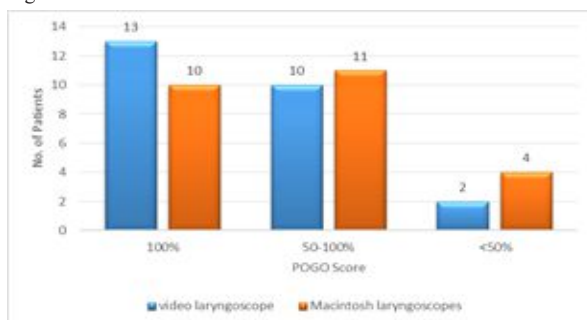


Table 5: Cormack and Lehane score

Cormack and Lehane score	McCoy video laryngoscope	Macintosh laryngoscopes
I	15 (60%)	12 (48%)
II	9 (36%)	11 (44%)
III	1 (4%)	2 (8%)

The Cormack-Lehane glottis view were better with McCoy video laryngoscope compared with the Macintosh laryngoscope. 60% vs 48%. (Figure 3 & Table 5)

Figure: 4 POGO Score



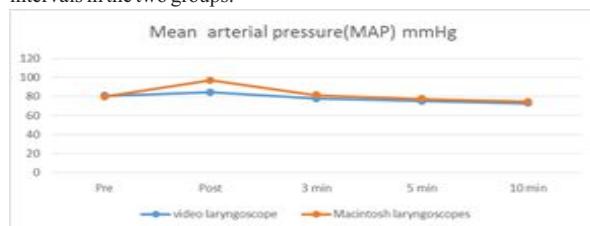
The POGO scores (Figure 4) were better with video laryngoscope when compared with the Macintosh laryngoscope.

Table 6: POGO score

POGO Score	video laryngoscope	Macintosh laryngoscopes	p-value
100%	13 (52%)	10 (40%)	0.575
50-100%	10 (40%)	11 (44%)	
<50%	2 (8%)	4 (16%)	

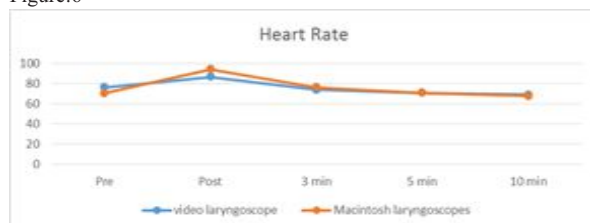
52% had POGO score of 100% in video laryngoscope group compared to 40% in the macintosh group. (Table 6)

Figure :5 Changes in mean arterial blood pressure at various time intervals in the two groups.



The increase in mean arterial pressure was less with video laryngoscope when compared to the Macintosh laryngoscopes. The mean arterial pressure (Figure 5) increased after intubation in all groups but returned to base line within 5 min after intubation in each group. Statistically significant, post laryngoscopy values noted in Macintosh group.

Figure:6

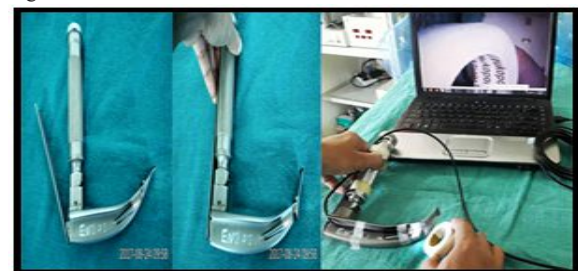

The effects of laryngoscopy on heart rate (Figure 6) were transient. Statistically significant, post laryngoscopy values noted in Macintosh group. The heart rate increased after intubation in both groups but returned to base line within 5 min after intubation. But the increase in heart rate was less with video laryngoscope.

## Discussion

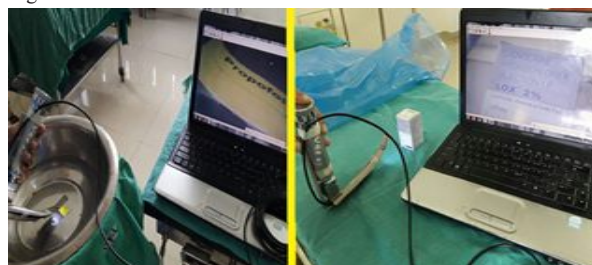In the present study, the McCoy video laryngoscope reduced the intubation difficulty score and improved the glottis view, when compared to Macintosh laryngoscopes in patients.

Figure: 7



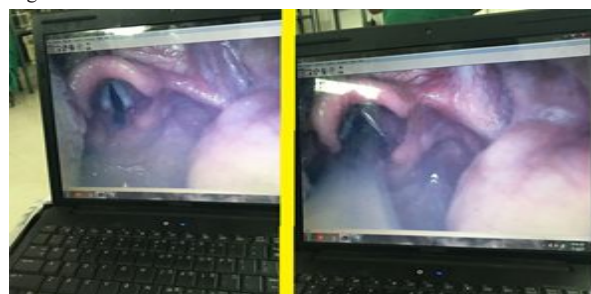
McCoy laryngoscope with tip of blade elevated. Setting the video laryngoscope. LED lights whose intensity are adjustable. (Figure 7)

Figure :8



The first half of the picture it's dipped in water and it focuses on the sticker stuck to bottom and Checking for orientation of camera in second half of the figure. The USB camera is water proof , wash and reuse. (Figure:8)

Figure : 9



Vocal cords visualized (POGO score 100%) and intubated successfully (Figure:9)

## Conclusion

In this study, the time to intubation with the custom made McCoy video laryngoscope was less when compared with Macintosh laryngoscopes. The main problem with the custom made video laryngoscope is fogging on the lens and blood and secretions in oral cavity which may reduce the image quality<sup>11</sup>. With the video laryngoscope less laryngeal manipulations and force required during intubation, thereby reducing the potential for haemodynamic stimulation due to a blunted haemodynamic response<sup>11</sup>. Studies have demonstrated that video laryngoscope improves the laryngeal view and first attempts at successful intubation when compared with the Macintosh laryngoscope in manikins with normal and anticipated difficult airways<sup>12-14</sup>.

When compared to conventional laryngoscopy with Macintosh blade video laryngoscope gives an excellent and enhanced view of the laryngeal structures. The commercially available video laryngoscopes are expensive, the custom made ones are safe and reliable and easy to use. The one we procured was a water proof type , cleaning the equipment was easy as well as sterilization of it. Real time imaging is an advantage and all the intubations were successful and not much of external manipulation was needed in the video laryngoscope group.

This can be used as a teaching tool for medical students, as the software helps to record video and take snap shots archiving of patients possible. When given an intubation chance for medical students they found this tool very helpful when compared to conventional form. All the students performed video laryngoscopy with ease and the outcome was a successful and uneventful intubation. This will be of help when patients with cervical injuries require endotracheal intubation as no major manipulation is required<sup>15</sup>.

## REFERENCES:

- Caplan RA, Posner KL, Ward RJ, Cheney FW. Adverse respiratory events in anesthesia: A closed claims analysis. *Anesthesiology* 1990;72:828-33.
- Cheney FW. The American Society of Anesthesiologists Closed Claims Project: What have we learned, how has it affected practice, and how will it affect practice in the future? *Anesthesiology* 1999;91:552-6.
- Peterson GN, Domino KB, Caplan RA, Posner KL, Lee LA, Cheney FW. Management of the difficult airway: A closed claims analysis. *Anesthesiology* 2005;103:33-9.
- Mort TC. Esophageal intubation with indirect clinical tests during emergency tracheal intubation: A report on patient morbidity. *J Clin Anesth* 2005;17:255-62.
- Mort TC. Emergency tracheal intubation: Complications associated with repeated laryngoscopic attempts. *Anesth Analg* 2004;99:607-13.
- Bhandari G, Shahi KS, Asad M, Bhakuni R. Airtaq® versus Macintosh laryngoscope: A comparative study in tracheal intubation. *Anesth Essays Res* 2013;7:232-6.
- McCOY, E. P. and MIRAKHUR, R. K. (1993), The levering laryngoscope. *Anaesthesia*, 48: 516-519. doi:10.1111/j.1365-2044.1993.tb07075.x
- Karipachcheril, J.G., Umesh, G. & Ramkumar, V. *J Clin Monit Comput* (2014) 28: 261. <https://doi.org/10.1007/s10877-013-9522-x>
- Cornack RS, Lehane J. Difficult tracheal intubation in obstetrics. *Anesthesia* 1984; 39:1105-11. <https://doi.org/10.1111>
- Adnet F, Borron SW, Racine SX et al. The Intubation Difficulty Scale (IDS): proposal and evaluation of a new score characterizing the complexity of endotracheal intubation. *Anesthesiology* 1997; 87: 1290-7. <https://doi.org/10.1097/00000542-199712000-00005> PMID:9416711
- Ali et al. A comparative evaluation of King Vision video laryngoscope (channeled blade), McCoy, and Macintosh laryngoscopes for tracheal intubation in patients with immobilized cervical spine. *Sri Lankan Journal of Anaesthesiology*: 25(2):70-75(2017)
- Itai J, Tanabe Y, Nishida T et al. Tracheal intubation for a difficult airway using Airwayscope®, KingVision® and McGrath®: a comparative manikin study of inexperienced personnel. *Critical Care* 2013; 17: 159.
- Murphy LD, Kovacs GJ, Reardon PM, Law J A. Comparison of the king vision video

- laryngoscope with the macintosh laryngoscope. JEmerg Med 2014; 47: 239-46.  
<https://doi.org/10.1016/j.jemermed.2014.02.008> PMID:24742495
14. Jarvis JL, McClure SF, Johns D. EMS intubation improves with King Vision video laryngoscopy. Prehosp Emerg Care. 2015;19(4):482-489.
  15. Carley S, Butler J Use of the McCoy laryngoscope in patients with suspected cervical spine fracture Emergency Medicine Journal 2000;17:364-365.  
<http://dx.doi.org/10.1136/emj.17.5.364-a>