



TRANSANAL EXTRACTION OF STRANGE INTRA-RECTAL FOREIGN BODY IN AN OLD MAN : ABOUT A CASE.

Surgery

**Mohamed
Essarghini***

MD, Surgical Service Of The Military Hospital Of Instruction Mohamed 5 Rabat Morocco. *Corresponding Author

ABSTRACT

INTRODUCTION: The intrarectal foreign body is an uncommon reason for consultation in our practice, especially in the elderly, and the questioning of the patient in this type of situation is not always successful. Fatal complications may be life-threatening apart from early diagnosis and adequate management.

OBSERVATION: This was a 70-year-old patient with no history, admitted in emergency for hypogastric pain with dysuria. the clinical examination revealed a hypogastric sensitivity and the rectal examination palpated a foreign body obstructing the rectal lumen, the abdominal CT allowed to highlight a huge foreign body occupying the pelvis. Transrectal instrumental extraction was possible under general anesthesia, and colonoscopy control confirmed the integrity of the rectal wall.

CONCLUSION: Colonoscopy when performed immediately after transanal extraction may reduce hospital stay in the absence of rectal lesions requiring close monitoring.

KEYWORDS

rectal foreign body, transanal extraction, colonoscopy

INTRODUCTION :

The intrarectal foreign body can be defined as a voluntary or involuntary insertion of an object into the rectum through the anal canal whose most widespread cause is sexual behavior but other causes may be encountered such as: cross-border illegal trafficking , aggression, mental illness ... [1].

Whatever the cause, this foreign body may cause anal and rectal lesions of varying degrees, especially at the time of its penetration and its transanal extraction.

In our practice, seeing this type of pathology is not common, this is the reason why we wanted to share a strange case, in our eyes, as well as the modalities of diagnosis and management.

Patient et observation :

A 70-year-old patient with no history, admitted to the emergency room for constipation for 48 hours. Interviewed by emergency doctor, he reported hypogastric pain with dysuria, the clinical examination found a soft abdomen with a hypogastric sensitivity, moreover, there was no abdominal meteorism or vomiting. A rectal examination was performed in search of a fecal impaction and to assess the state of the prostate, curiously palpated an object occupying all the distal rectal lumen, of hard consistency.

Faced with the failure of digital maneuvers attempting to mobilize, an abdominopelvic CT was performed in order to identify this object but especially in search of a complication. This examination revealed a grossly spherical object, occupying almost the entire rectal lumen with a hypodense center, with no sign of peritonitis or colonic occlusion (Figures 1 and 2).

Under general anesthesia, in the prone position, the patient underwent transanal extraction after fractionation of an intrarectal apple using an Allis forceps. After rectal preparation, colonoscopy performed immediately to check the integrity of the rectal mucosa did not indicate laceration or hematoma.

The patient left the hospital the next day after a psychological assessment.

DISCUSSION

The rectal foreign body has been described in the literature in patients of all ages, irrespective of sex or ethnicity, and in two-thirds of reported cases it is a male patient, in his thirties or forties [1]. In our 70-year-old patient and in our sociocultural context, this diagnosis remains little evoked.

The clinical symptomatology in rectal foreign body is not specific; vague abdominal pain, rectal bleeding, rectal pain or sometimes constipation may be suggestive signs. Sepsis and peritonitis indicate a

perforating complication [2]. In our case, constipation and urinary signs pushed towards the digital rectal examination that guided the diagnostic procedure.

Computed tomography often helps to diagnose rectal perforation, which is a severe complication [1-3], it has also allowed us a visual diagnosis of the foreign body: its size, shape and nature.

Transanal extraction is a treatment of choice in the absence of evidence of perforation and 75% of rectal foreign bodies can be removed without surgical intervention when sedation or anesthesia provides optimal sphincter relaxation [3-4]. In our situation this extraction was made possible, considering the volume of foreign bodies, only after instrumental fragmentation.

Interventional colonoscopy can be considered as a means of transanal extraction in the absence of perforation, especially for high objects located in the rectum or sigmoid [5]. It also makes it possible to evaluate the rectal lesions due to the foreign body itself. , secondary lesions caused by the patient while attempting to remove the foreign body prior to consultation and possible iatrogenic lesions related to transanal extraction in hospital [1-6]. the immediate conventional colonoscopy following the extraction that we performed after rectal preparation allowed us to reduce the hospital stay in the absence of rectal lesions requiring prolonged close monitoring.

CONCLUSION

A control colonoscopy systematically after a transanal extraction of rectal foreign body seems a wise attitude to detect lesions that require surveillance and if not to reduce the length of hospitalization.

Conflicts of interest

The authors do not declare any conflict of interest

Contributions of the authors:

All authors contributed to the writing of this article. The authors also state that they have read and approved the final version of the article.

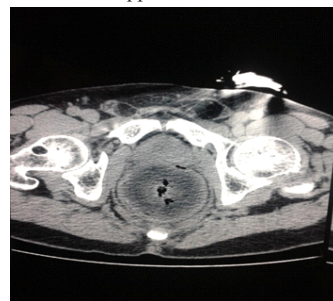

Figure 1: apple blocked between the bones of the pelvis.

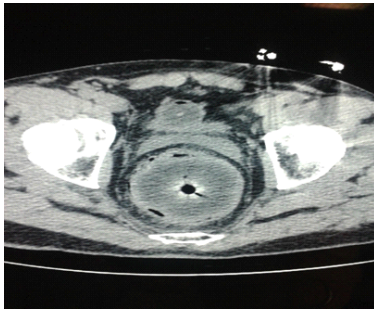


Figure 2 : CT aspect of a rectal apple.

REFERENCES :

1. Joel E. Goldberg, Scott R. Steele. Rectal Foreign Bodies. *Surg Clin N Am*.2010 ;90(1): 173–184
2. Ali Coskun, Nazif Erkan, Savas Yakan, Mehmet Yildirim and Fevzi Cengiz . Management of rectal foreign bodies. *World Journal of Emergency Surgery*.2013 ; 8(1): 5 pages
3. Faruk Karateke, Koray Das, Sefa Ozyazici, Ebru Menekse, Zikret Koseoglu, and Ozgur Karcioğlu. Anorectal Injuries due to Foreign Bodies: Case Reports and Review of the Management Options. *Case Reports in Surgery*. Volume (2013) 2013; Article ID 809592. 4 pages
4. A. Senéjoux. Extraire un corps étranger intrarectal. *Colon Rectum*. 2010 ;4(4):239-240
5. Xiao-Dong Lin, Guang-Yao Wu, Song-Hu Li, Zong-Quan Wen, Fu Zhang, Shao-Ping Yu. Removal of a large foreign body in the rectosigmoid colon by colonoscopy using gastrolith forceps. *World J Clin Cases*.2016 ;4(5): 135-137
6. Bobby Desai . Visual diagnosis: Rectal foreign body: A primer for emergency physicians. *International Journal of Emergency Medicine*.2011 ;4(73) , 3 pages.